

# Magnetocardiographic versus PET images in «difficult-to-diagnose» patients with CAD

Chaikovsky I., Primin M., Nedayvoda I., Budnik N.

Institute for Cybernetics of NAS of Ukraine, Kiev, Ukraine

**Summary.** Presented clinical cases show great potential of joint analysis of the electrical activity of the heart based on the MCG data and perfusion images based on PET, particularly in difficult-to-diagnose cases, i. e. patients with non-informative results of routine tests. 3D reconstruction of the current density on the basis of the inverse problem solving is the most promising direction of magnetocardiographic data. analysis.

**Key words:** magnetocardiography, PET, inverse problem, CAD.

## INTRODUCTION

Worldwide, coronary artery disease (CAD) is becoming pandemic [1]. Mortality from CAD is predicted to reach 23.4 million in 2030. Now days, chronic CAD is estimated to affect 16.8 million people in the United States; and 2.65 million people in the UK. CAD was the single most frequent cause of death in USA and Western Europe (about 1 in every 5 deaths). The estimated direct and indirect economic cost of CAD in the United States for 2009 is \$ 165.4 billion. Moreover, in the developing world, particularly in Ukraine, prevalence of CAD is even higher and there is the tendency tends to affect people at a younger age and thus could negatively affect the workforce and economic productivity. The morbidity, mortality, and socioeconomic importance of CAD make its diagnosis and management fundamental for all practicing physicians [2].

Non-invasive, rapid and reliable diagnosis of coronary artery disease and patients with chest pain remains a clinical challenge.

Methods of detecting the presence and assessing the extent of CAD have become increasingly important in informing therapies aimed at reducing mortality and morbidity. Coronary angiography (CA) is considered to be the «gold standard» for defining the site and severity of coronary artery lesions. However, routine use of CA without prior non-invasive testing is not advisable, except in those with a high pre-test probability of significant disease, partly due to the high cost, but also because of the associated morbidity and mortality. The most serious complications of CA are death (0.1–0.2 %), non-fatal MI (0.1 %) and cerebrovascular accidents (0.1 %).

Functional (non-invasive) testing is used as a gateway to angiography for management of coronary artery disease. Among those the most important are the following methods: stress (usually treadmill or bicycle exercise) electrocardiography, Stress-Echo, MRI myocardial perfusion, nuclear perfusion.

All existing methods have certain merits and disadvantages. Stress-ECG is widely used for non-invasive detection of CAD owing to its availability and low cost. However, a normal EET does not exclude CAD and EET is a poor diagnostic test in low-risk populations (such as women) owing to its low positive predictive value in a population with a low prevalence of the disease. Deaths occur rarely, in < 0.05 % of tests. Echo is one of the most frequently used tools for the investigation of a wide range of cardiological problems. The portability and relative affordability of the equipment have led to a very rapid acceptance of the technique by the general medical community. The sensitivity, specificity and accuracy of stress-echo is in the range 80–85 % with the highest sensitivity (> 90 %) for three-vessel disease

and the lowest (75 %) for single-vessel disease. There are limitations inherent to the stress echo technique. Chief among these is the problem of reliably obtaining good images and reproducible tomographic slices as the heart rate goes up with increasing rate of dobutamine infusion. Furthermore, there may be significant inter-observer variability in image interpretation due to the subjective nature of wall motion assessment.

MRI is a relatively new tool for the examination of the heart compared with the other non-invasive modalities and clinical value of this method is still doubtful.

Nuclear perfusion has an extensive pedigree extending back over a quarter of a century, with hundreds of thousands of scans performed worldwide each year. Recent guidelines have suggested that the technique could be even more widely employed in the future [3]. Positron emission tomography (PET) is probably the most sensitive method to analyze myocardial perfusion and to detect myocardial ischemia. It is actually regarded the non-invasive «gold standard». Major disadvantages of PET-technique are high expenses, attenuation artifacts, use of ionising radiation, radiation and availability in specialist centers only.

Thus there is a need for low-cost, accurate, noninvasive diagnostic tools, more convenient and less complicated for both the diagnostics and screening for coronary artery disease. Magnetocardiography (MCG) is known as a completely non-invasive and risk-free method of measuring cardiac activity. Recent studies has shown significant potential of MCG in diagnosis of myocardial ischemia, although analysis of MCG-generated data is not standardized yet [4–6].

MCG technology closely related to modern methods of data processing. There is a variety of methods and indicators for medical analysis available in the current stage of MCG development. MCG analysis can be expressed at several levels of increasing complexity of MCG signal transformation [7].

Level 1. The first level of analysis is similar to routine morphological analysis of the 12-lead ECG.

Level 2. Spectrotemporal analysis. The relative power of a cardiac signal for various frequency bands and their spectral variability and time-domain analysis (such as QRS duration) of the MCG can be provided at specific measurement points.

Level 3. 36 measurement points of the MCG-7 are summarized in an averaged curve. Such an approach provides a more generalized representation of myocardial excitation. For example, the areas under the P-wave or the QRS-complex reflect overall «electrical energy» generated due to excitation of atria and ventricles.

Level 4. Magnetic field mapping. This requires the construction of maps showing the distribution of the magnetic field obtained at specific measurement points and precise moments of the cardiac cycle. These maps are constructed along the principles of geographical or meteorological maps. Areas with identical value of given parameter are color filled. There are variety of quantitative and semi-quantitative indicators to estimate such maps.

Level 5. The representation of all electrical sources as one equivalent dipole. Here it is assumed that all electrical activity of the heart originates from one point.

The sixth, highest level of MCG software development are based on an inverse problem solution. This approach allow 2D reconstruction of distributed electrical cardiac sources and first steps have been made for 3D reconstruction. This promising technical progress allow to utilize magnetocardiography routinely in the next future, e. g. in patients with «normal» or uncertain results of standard testing, especially in patients with high or intermediate pre-test probability of CAD.

---

This study intended to compare MCG-images of «difficult-to-diagnose» patients with normal left ventricular function and clinical suspicion of ischemic heart disease with perfusion images obtained by the PET-technique.

## **METHOD**

The study includes 3 patients (2 female, 1 male, mean age 58 years) and one healthy volunteer (male, 47 year). All patients underwent resting and stress ECG, echocardiography, PET and coronarangiography. The healthy volunteer had no history of any cardiovascular disease, normal ECG at rest and stress as well as a normal echocardiogram.

Coronary angiograms were documented in multiple projections according to standard clinical practice (Judkins-technique). PET was performed with adenosine to recruit coronary reserve. Resting and stress recordings were made using N-13-ammonium as tracer. MCG was performed in an unshielded setting using a 7-channel SQUID-magnetometer. Single MCG recordings were taken from 36 positions within a 20 by 20 cm rectangular grid with a 4 cm pitch over the precordial area. The sensor was positioned as close to the chest as possible, directly over the heart using the jugulum as landmark. The examination table with the patient resting in constant the same position was then moved systematically to each of the 36 predetermined positions under the SQUID detector. Data were recorded at each registration point for 30 seconds with simultaneous registration of lead II of the surface ECG and stored on hard disk for further evaluation. The analysis was based on the «inverse problem solution», i. e reconstruction of the intracardiac sources that originated the magnetic field measured.

## **INVERSE PROBLEM SOLUTION**

Description of the problem and definition. The «inverse problem solution» is based on the following physical considerations. Magnetocardiographic measurements are made with a sensor moving over a planar grid above the body surface. The distance from this planar grid to a signal source inside the heart differs from patient to patient. As the magnetic field parameters vary with the source-to-plane distance in a nonlinear way, magnetic field maps generated may also vary significantly in one and the same patient. To the technical set up with the analysis of the biomagnetic field source distribution, directly corresponding with the field registered, this problem can be overcome. Therefore magnetocardiographic information transformation should lead to the inverse problem solution.

The full definition of inverse solution is following : inverse task solution in electrodynamics (magnetostatics) implies finding of special magnetic sources distribution from the known (registered) magnetic field parameters.

Steps of solution. Inverse problems may could be solved in different ways, using simple or more complex models of biomagnetic sources. There are the following steps in modeling and representation of bioelectrical sources in the heart.

### **1) Localization of the dipole magnetic field source [8].**

We use a model of the magnetic dipole as the source of biomagnetic signal in contrast to common approaches using the electric dipole as a source. Based on this approach the more precise analytical solution of the inverse task could be obtained. The background for the analytical solution is to use the properties of the

spatial derivatives of the magnetic induction vector  $B$  matrix in a homogeneous nonmagnetic and nonconductive medium (in points of measurements  $\text{div}B = 0$ ,  $\text{curl}B = 0$ ). In this case, matrices of the first ( $D_1$ ) and second ( $D_2$ ,  $l = x, y, z$ ) spatial derivatives of the  $B$  vector are symmetrical and possess several properties providing analytical solution of the inverse task to be fulfilled first in a new (own) and afterwards by reverse transition in a set-point coordinate systems. It is important that independent solutions can be obtained for every point in a plane of measurement. As a result «effective» dipole (i. e dipole which creates the magnetic field with parameters corresponding with high degree of accuracy to those of the field registered in the plane of measurement) could be localized. It means that three coordinates  $r_z, r_x, r_y$  and magnetic moment of these dipoles could be determined.

## **2) Reconstruction of currents distribution in the layer [9].**

Distribution of the current density vectors has been defined using double integral Fourier transform for the plane arranged at a distance equal to  $r_z$  coordinate of the «effective» source and parallel to the thorax and to the plane of measurements.

## **3) Reconstruction of 3D magnetic dipole density [10].**

Method is based on analytical method of inverse solution. Source of biomagnetic signal can be represented in the form of  $N$  elementary magnetic dipoles. Algorithm allows to make a solution on the determination of coordinates and magnetic moment vector for every dipole, homogenization of the source and finally representation of the «effective» biomagnetic signal source as a 3D «clouds» of magnetic dipole density. That is way the most suitable model for solving of inverse problem in this class of patients is a system of currents, distributed in the plane or (what is the best) in the volume.

## **4) Tomographical (layer-to-layer) reconstruction [11, 12].**


Knowing density, coordinates and magnetic moments of all elementary magnetic dipoles currents distribution as a current density vectors maps could be obtained for any  $r_z$  coordinate i. e for any distance (layer) from the measurement plane. The layer with the highest current density values corresponds to the layer possessing maximum number of elementary sources. The specificity of our approach is that every further, more advanced step of inverse solution based on the results of the preceding step which allows us to approach reliable 3D solution. The results of current distribution in the layer, reconstruction of 3D magnetic dipole density and layer-to-layer reconstruction were used for further medical analysis. From all patients 32 CDV maps were generated on equal distance within the ST-T interval starting with the J-point.

## **5) Reconstruction of 3D image of electrical activity in the heart.**

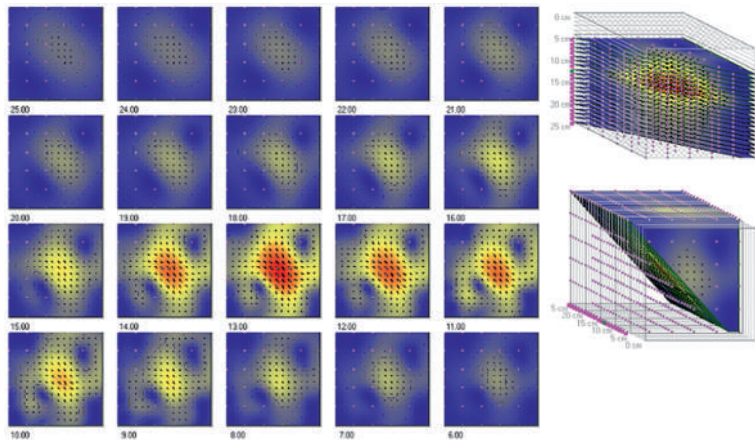
This reconstruction have been done for single time moment in the middle of ST-T interval. Two approaches for 3D data representation have been used. One of them represents reconstruction of the 2D CDV maps on the different distance from the probe, in other words this reconstruction of electrical activity on layers (methodologically similar to tomographical approach in other imaging methods). Other approach represents a 3D distribution of magnetic dipoles density. «Cloud» of these dipoles represent the exited zones of myocardium.

## RESULTS

Healthy volunteer	male, 47 years
Complaints	none
Resting ECG	normal
Echo	normal
Magneto-cardiography	The 2D CDV maps within ST-T interval show a highly homogeneous distribution of currents with only one main current area in each map. Main current density vectors are located at the center part of the maps and are directed left-to-downwards (Fig. 1a). The maps remain stabile over the ST-T interval. «Tomographical» representation is shown on Figure 1b. Homogeneous current distribution with similar structure of maps at each layer could be seen. The layer with maximal density is located on the middle distance from the measurements plane. «Cloud» of magnetic dipole density (Figure 1c) is very compact, spherical and located on the center of the cube of sources reconstruction



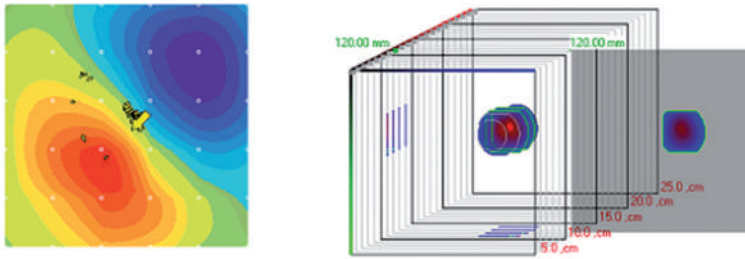
**Figure 1a**  
Example of reconstruction of several current density vector maps in the course of the ST-T interval of volunteer M. O.



**Figure 1b**  
3D current reconstruction at the middle of ST-T interval of volunteer M. O.

Upper row: axonometric projection of cube of current reconstruction – frontal view (left) and sagittal view (right).


Low rows: current density vectors maps on different distance from plane of measurement (from 6 to 25 cm).



**Figure 1c**  
3D dipoles density reconstruction at the middle of ST-T interval of volunteer M. O.

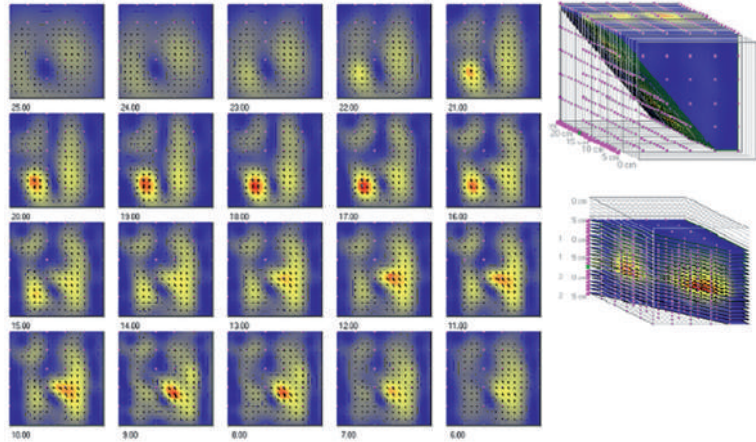
Axonometric projection of cube of current reconstruction with «cloud» of dipoles density. Layer with maximal density is marked.

Patient J	male, 72 years
Complaints	typical chest pain
Resting ECG	unchanged
Echo	mild LV hypertrophy, otherwise – normal echocardiogramm
Coronaroangiography	1-vesel disease, stenosis (75 %) of proximal to mild LAD
LV-angio	mild LV hypertrophy, otherwise – normal result
PET	reduced myocardial perfusion in the all walls in particular in septoapical area
Magnetocardiography	2D CDV maps within ST-T interval are presented in Figure 2a. Maps are not homogenous, absence of dipole structure are seen within the hole ST-T interval. «Tomographical» representation (Figure 2b) clearly shows two area of activity: one of them is located on the anterior part of the cube of reconstruction with maximal intensity on the layer of 12 cm, another is shifted left-backwards with maximal activity on 18 cm. «Cloud» of magnetic dipoles (Figure 2c) generally shifted downwards and also clearly divided on two areas

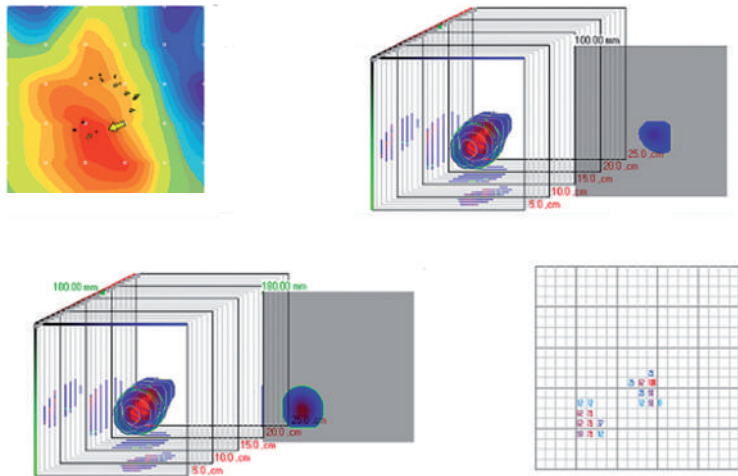


**Figure 2a**  
Example of reconstruction of several current density vector maps in the course of the ST-T interval of patient J.





**Figure 2b**  
**3D current reconstruction at the middle of ST-T interval of patient J.**




**Figure 2c**  
**3D dipoles density reconstruction at the middle of ST-T interval of patient J.**

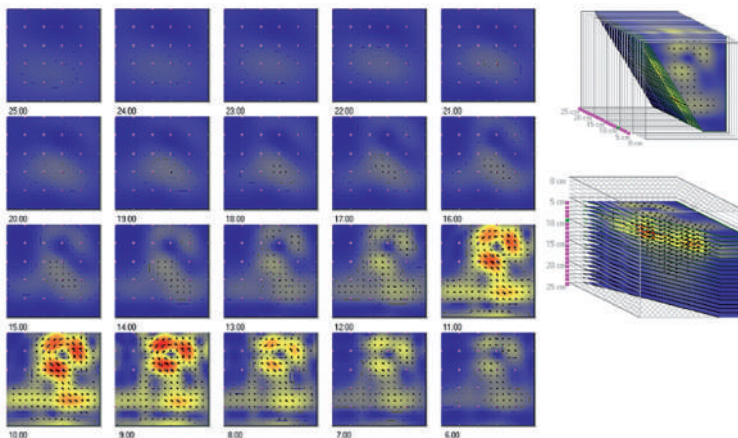
Axonometric projection of cube of current reconstruction with «cloud» of dipoles density. Layers with maximal density of upper currents area (right) and lower currents area are marked.

Patient L.	male, 74 years
Complaints	atypical chest pain
Resting ECG	unchanged
Ergometry	125 WT, end point criteria – targeting heart rate achieved
Echo	marginal local contractility disturbances in the anterior wall, otherwise – normal echocardiogram

Coronaroangiography	1-vesel disease, stenosis (50 %) of proximal to mild LAD
LV-angio	marginal local contractility disturbances in the anteriolateral wall and septoapical area
PET	reduced myocardial perfusion in the apical, septoapical and suproapical areas
Magnetocardiography	2D CDV maps within ST-T interval are presented in Figure 3a. Maps are not homogein, non-dipole especially at the beginning and at the and of ST-T interval, there are additional current areas at the upper and lower part of maps. «Tomographical» representation (Figure 3b) clearly shows two area of activity which are located approximately on one depth – 11–12 cm. «Cloud» of magnetic dipoles (Figure 3c) like in previous case generally shifted downwards and also clearly divided on two areas, one of them is shifted rather up backwards

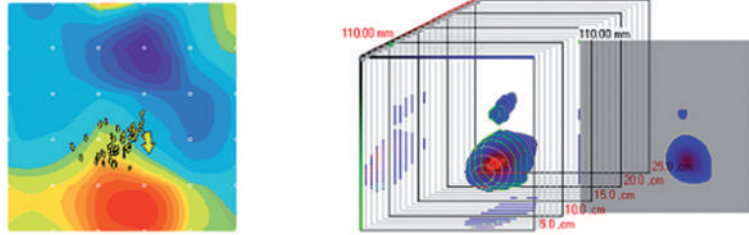


**Figure 3a**  
**Example of reconstruction of several current density vector maps in the course of the ST-T interval of patient L.**



**Figure 3b**  
**3D current reconstruction at the middle of ST-T interval of patient L.**

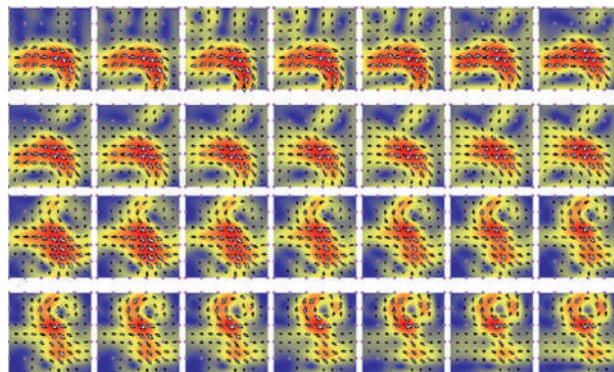




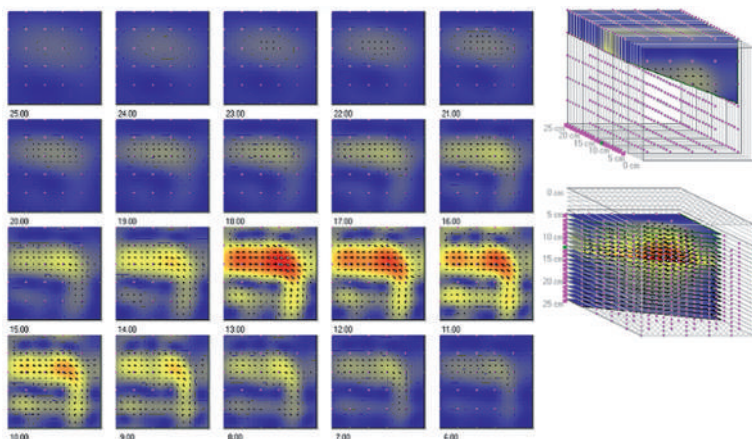
**Figure 3c**  
**3D dipoles density reconstruction at the middle of ST-T interval of patient L.**

Axonometric projection of cube of current reconstruction with «cloud» of dipoles density. Layer with maximal density is marked.


Patient T	female, 42 years
Complaints	atypical chest pain
Resting ECG	absolute arrhythmia due to atrial fibrillation, otherwise-unchanged ECG
Ergometry	125 WT, end point criteria – targeting heart rate achieved
Echo	normal echocardiogram
Coronaroangiography	Coronarosclerosis, macroangiopathy formally excluded.
LV-angio	Marginal hypokinesia of apical are, otherwise – normal results
PET	Small local reducing of myocardial perfusion in the inferioapical area
Magnetocardiography	2D CDV maps within ST-T interval are presented in Figure 4a. Maps are not homogein, absence of dipole structure are seen within the hole ST-T interval. «Tomographical» representation (Figure 4b) shows one but non-compact, distributed are of activity with fuzzy contours. «Cloud» of magnetic dipoles (Figure 4c) located approximately on the central part of the cube of source reconstruction but also non-compact and non-spherical



**Figure 4a**  
**Example of reconstruction of several current density vector maps in the course of the ST-T interval of patient T.**



**Figure 4b**  
3D current reconstruction at the middle of ST-T interval of patient T.



**Figure 4c**  
3D dipoles density reconstruction at the middle of ST-T interval of patient T.

Axonometric projection of cube of current reconstruction with «cloud» of dipoles density. Layer with maximal density is marked.

## DISCUSSION

Methods of MCG-data analysis based on inverse solution are able to give the most valuable information. However some methodological aspects should be taken into consideration for optimal using of this approach.

It is well known that the inverse solution in classical setting up has no unambiguous solution. The task is simplified and can acquire the uniqueness with definition of the «functional relationships» between magnetic field measured and sources reconstructed. In other words, definition of the field source models (point dipole, current layer distributed in a plane, current distributed in a volume) determines the relationships between field sources and magnetic field values and distribution in the plane of measurement.

It is rather complex to choose the field source model. This choice of the source model is determined on the one hand by the excitation area dimensions, distance

---

from the sensor (registration point), diameter of the magnetic flux transformation coil and on the other hand by physiological characteristic of the process under investigation. In other words to substantiate the model of the biomagnetic signal source, the volume of the active heart tissue where the source is distributed should be considered in relationship with field parameters registered in points of the plane of measurements. For instant « point dipole» model is correct in the cases of small, focal sources in a heart muscle stipulated by excitation of the His-Purkinje conducting system and arrhythmogenic focuses. In contrast, perfusion insufficiency, first of all because of CAD, is resulting in electrophysiological changes of more extended zones of myocardium. Therefore the most suitable model for solving of inverse problem in this class of patients is a system of currents, distributed in the plane or, what is the best, in the volume.

This is especially true when ventricular repolarisation period is analysed. Repolarisation is a diffuse process i. e. large zones of the whole myocardium are excited simultaneously in the case of normal ventricular myocardium. Pathological processes will lead to the asynchronisation of the repolarisation process in the normal and affected zones of myocardium. In other words we could say that different zones of myocardium are in the different electrical stage due to the difference in the conduction velocity.

That is why the concept of clinical analysis of electrical images obtained is based on of homogeneity, «electromagnetic symmetry» evaluation. Highly homogeneous type of electrical currents within the whole ST-T interval in 2D mode and at the middle of ST-T interval in the 3D mode we could see in the healthy volunteer maps. In the framework of our concept we could assume that this maps reflect absence of myocardial zones with different electrical properties. The most non-homogeneous structure of current maps we could see in patient J. This is especially clear when 3D image is analysed – two zones of activity located on two different levels of cube of reconstruction – more upwards and more downwards. This patient shown the most pronounced coronary stenosis and the most severe perfusion insufficiency by PET.

The maps of patient L. also not homogeneous especially at the beginning of ventricular repolarisation. 3D image also shows two zones, both located on one level – a little bit upwards. Perfusion insufficiency was found in the apical and supraapical areas.

2D maps and 3D reconstruction of patient T. could be settled on the intermediate position between maps of healthy volunteers and maps of patients with CAD in the sense of inhomogeneity of electrical images. At the same time only minor perfusion insufficiency (probably due to microangiopathy) in the apical was found. From pathophysiological point of view this inhomogeneity could be explained by the the presence of myocardial ischemia at rest. Indeed the absence of ischemia under resting conditions is generally accepted to be the explanation for a normal ECG at rest in CAD patients. Keeping in mind that ischemia is a dynamic process with an important temporal continuum starting with changes on molecular basis followed by some unspecific changes in the 12 lead standard ECG progressing, leading to wall motion disturbances, and angina as a last step, it could be possible that this new method is able to detect signs of ischemia in a very early phase of such a dynamic process.

Perfusion insufficiency proved based on PET results confirms presence of myocardial ischemia regardless to normal results of ECG and other routine tests. In what way insufficiently perused myocardial zones could represent themselves

on 3D current images. Generally two variants could be supposed: In the case of affected but viable myocardium areas of additional pathological electrical activity could overlap these zones or be located near by, representing so-called «currents of injury». In the case of non-viable myocardium, losing electrical properties completely, electrical «defect» could be seen on 3D electrical images.

To find a correlation between 3D electrical images these areas and myocardial segments in pathological conditions (different stage of perfusion insufficiency, hibernation stunning and so on) will be the main subject of further studies. It is also important from methodological point of view to present digital information in «absolute terms» like it is achieved already in other diagnostic methods. «Absolute terms» for magnetocardiography, analyzing homogeneity of electrical properties of myocardium, is dispersion of conduction velocity within certain physiological periods of cardio cycle, first of all within ventricular repolarization.

In the near future such software, directly representing zones of hypo-, hyper- and normal conduction as well as diagnostic indicators might be developed to show a complete 3D electrical image of the heart. The fact that CAD patients, presumably with ischemia but with a normal results of the routine tests, might be identified on the basis of a completely noninvasive method is of great clinical interest.

The original results of earlier studies with a multichannel MCG system inside a shielded setting, were always limited by the expensive costs of the system itself and by the lack of patient e. g. c. q. physician acceptance. The present data show the results of a much less expensive system not requiring a shielded room. A further confirmation of these results in a greater population would be an important step towards the aim to restrict invasive procedures like coronary angiography to those patients in whom the diagnosis of CAD is confirmed prior to the procedure and in whom interventional therapy appears to be indicated.

A main limitation of this study is small number of cases analyzed. Then, the analysis of 3D magnetocardiographic images is rather subjective. As long as the score system depends to some degree on the experience of the observers, with the need for a training procedure, the implementation of an automatic process following the described criteria should improve this aspect.

Nevertheless presented cases shows a certain clinical potential of joint analysis of heart electrical images based on MCG and perfusion images based on PET. Further investigation will be done to make this diagnostical approach useful in a clinical routine.

## Сравнение магнитокардиографических изображений ПЭТ в «сложных для диагностики» случаях у больных с ИБС

Чайковский И., Примин М., Недайвода И., Будник Н.

Институт кибернетики НАН Украины, г. Киев, Украина

**Резюме.** Представленные клинические случаи показывают большой потенциал совместного анализа электрической активности сердца на основе МКГ и перфузионных изображений на основе ПЭТ, в особенности в трудных для диагностики случаях, т. е. у пациентов с неинформативными результатами рутинных тестов. 3D реконструкция плотности тока на основе решения обратной задачи магнитостатики является наиболее перспективным направлением анализа магнитокардиографических данных.

**Ключевые слова:** магнитокардиография, ПЭТ, обратная задача, ишемическая болезнь сердца.

---

## ЛИТЕРАТУРА

1. Omran AR. Changing patterns of health and disease during the process of national development. In: Albrecht GL, Higgins PC, eds. *Health, Illness and Medicine: A Reader in Medical Sociology*. Chicago, IL: Rand McNally; 1979.
2. Cassar A, Holmes DR, Jr, Rihal CS, Gersh BJ. Chronic coronary artery disease: diagnosis and management. *Mayo Clin Proc.* 2009; 84(12):1130–1146.
3. Sharples L., Hughes, Crean A., Dyer M., Buxton M., Goldsmith K, Stone D. Cost-effectiveness of functional cardiac testing in the diagnosis and management of coronary artery disease: a randomised controlled trial. The CECaT trial. *Health Technology Assessment* 2007; Vol. 11: No. 49:1–86.
4. Hailer B., Chaikovsky I., Van Ieeuwen P, Auth-Eisernitz S. The value of MCG in pts with and without relevant stenoses of the coronary arteries using an unshielded system. *PACE*, 2005; 28:8–16.
5. Kwon H, Kim K, Lee YH, Kim JM, Yu KK, Chung N, Ko YG. Non-invasive magnetocardiography for the early diagnosis of coronary artery disease in patients presenting with acute chest pain. *Circ J.* 2010 Jul;74(7):1424–30.
6. Chaikovsky I., Boychak M., Sosnytsky V., Mjasnikov G., Sosnytskaja T., Ryschlik K., Frolov Yu., Budnik V. Magnetocardiography in unshielded location : technologies of data analysis. *Likarska sprava*, 2011; 3–4:54–64 (in Russian).
7. Chaikovsky I., Primin N., Hugenholtz P., Nedayvoda I., Horstkotte D., Berndt C., Korfer J., Hailer B. Approaches and methods for the clinical interpretation of the magnetocardiogram // *USIM*, 2006:2:33–43.
8. Primin Michael A., Nedayvoda Igor V., A mathematical model and measurement algorithms for a dipole source location. *Int. J. of Applied Electromagnetics and Mechanics.* 1997; vol. 8: 119–131.
9. Gumenyuk-Sychevskii Vitalij I., Primin Michael A., Nedayvoda Igor V. Mathematical model and data processing algorithms for spatial analysis of weak magnetic fields. *Engineering Simulation.* 1993; Vol.11, 1:40–150.
10. Primin Michael A., Nedayvoda Igor V. Inverse problem solution algorithms in magnetocardiography: new analytical approach and some results. *International Journal of Applied Electromagnetics and Mechanics.* 2009; vol. 29, 2:65–81.
11. Primin Michael, Chaikovsky Ilya, Berndt Caroline, Nedayvoda Igor, Korfer Jan, Layer-to-layer heart electrical image based on magnetocardiography data in comparison with perfusion image based on PET, *Int.J.of Bioelectromagnetism.* 2003; Vol. 5, 1:27–28.
12. Primin Michael A., Nedayvoda Igor V., Masslennikov Yuri V., Gulyaev Yuri V., Software for the magnetocardiographic complex for the early diagnostics and monitoring of heart diseases, *Journal of Communications Technology and Electronics.* 2010; vol. 55 , 10:1250–1269.

Рецензент: Билинский Е. А., к. м. н., доцент НМАПО им. П. А. Шупика МОЗ Украины

Статья поступила в редакцию 01.04.2014 г.