

КОРОТКІ ПОВІДОМЛЕННЯ

DOI:10.21802/gmj.2016.4.5

Arda Isik^{*1}, Huseyin Eken¹, Mehmet Soy Turk², Deniz Firat¹, Osmayil Yilmaz¹**A Rare Presentation of Accessory Breast in Axilla**¹ Erzincan University, School of Medicine, Department of General Surgery, Erzincan, Turkey² Erzincan University, School of Medicine, Department of Radiology, Erzincan, Turkey*Corresponding author: kararda@yahoo.com

Accessory breast tissue is rare, accounting for less than 0.1% of cases seen among young women; it is generally bilateral. We report a case of a 22-year-old woman with a mass in the right axilla (Fig. 1-2) with a differential diagnosis of fibroadenoma being confirmed by ultrasonography (USG) the results of which revealed that it was accessory breast tissue in the axilla. At USG, 35x4 mm hypoechoic ductus was seen inside of breast tissue (Fig. 3). Differential diagnosis for all axillary masses should also be considered: axillary accessory breast cancer, hidradenitis, lymphadenomegaly, lipomas, cutaneous neoplasia, cysts, and phyllodes tumori. Although, there are a few reports, our case is similar to current medical registers and our patient has an excellent prognosis during follow up period [1-3].

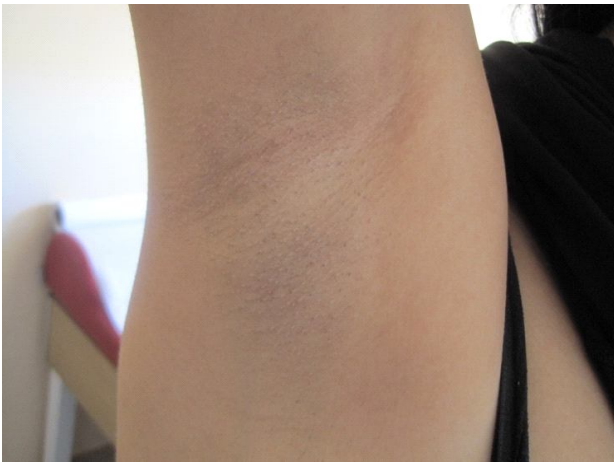

Fig. 1

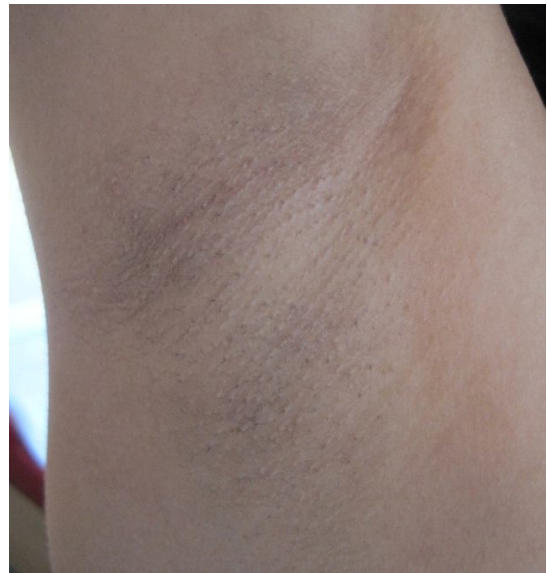

Fig. 2

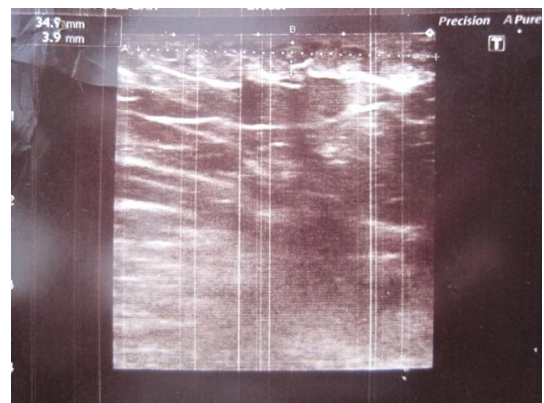


Fig. 3

References

1. Isik A, Karavas E, Peker K, Soy Turk M, Yilmaz I. Male Mondor's Disease is a Rare Entity. *Breast J.* 2016; DOI: <http://doi.org/10.1111/tbj.12657> (
2. Firat D, Idiz O, Isik A, Peker K, Atar N, Gul E. Spontaneous Milk Fistula from an Accessory Breast: An Extremely Rare Case. *Breast J [Internet].* 2015 Sep;21(5):554–555. DOI: <http://doi.org/10.1111/tbj.12452> [PMid: 26183695] (
3. Firat D, Ozturk G, Demirbas E, Idiz O, Isik A, Eken H. Auto-Amputation of the Breast; a Rare Case Caused by Invasive Ductal

Carcinoma. *Breast J [Internet].* 2016; DOI: <http://doi.org/10.1111/tbj.12696>

Received: 3.10.2016

Revised: 4.10.2016

Accepted: 5.10.2016