

CARDIOLOGY

Zhuiko A.

AORTIC STENOSIS IN 93 Y.O. FEMALE (case report)

Belorussian Research Institute of Cardiology, Belarus

Abstract: The increase in life expectancy of patients contributes to development of new technology for treatments of patients with comorbidities of advanced age. Transcatheter aortic-valve implantation has been suggested as a less invasive treatment for high-risk patients with aortic stenosis.

KeyWords: aortic stenosis, transcatheter aortic-valve implantation



INTRODUCTION

Aortic stenosis (AS) has become the most frequent type of ventricular heart disease (VHD) in Europe and North America. It primarily presents as calcific AS in adults of advanced age (2-7% of the population over 65 years) [1, 2]. The primary treatment for severe aortic stenosis is aortic valve replacement surgery. The 3-year survival in patients with symptomatic aortic stenosis who undergo surgery is 87%; in those who do not have surgery, it is 21% ($P < 0.001$) [3].

AS with a valve area 1.0 cm² is considered severe, critical AS is most likely with a valve area 0.8cm² [4].

CASE STUDY

A 93-year old woman with a stress reaction on death of the husband. In anamnesis are the iron deficiency anemia, sigmoid diverticulosis, colonic angiodysplasia (2014), cholecystectomy, appendectomy, chronic renal failure, presented with, paroxysmal atrial fibrillation (under Rivaroxaban therapy), symptomatic aortic (valve) stenosis, arterial hypertension, osteoporosis.

Physical examination:

Anthropometry - 156 cm, 65 kg. BP - 150/60 mm Hg. Loud systolic murmurs were heard in point 2 with right carotid radiating. Weak vesicular breathing was heard in the basal area; basal pleural effusions were noticed. The abdomen was soft, not resistant; the patient denied any tenderness. Discreet lower leg edema was present. She also denied chest pain, shortness of breath. She reported exercise dyspnea.

Chest X-ray demonstrated chronic signs of congestion and low angle effusions on both sides, sclerosis of the aorta without the evidence of infiltration. Laboratory data are presented in Table 1.

Corresponding Author:

Corresponding Author:

Alena Zhuiko, MD, PhD, Assistant of Professor, senior researcher, Belorussian Research Institute of Cardiology, Minsk, Belarus. E-mail: zhuchok.06@mail.ru

Table 1.
Results of laboratory investigation of the female patient with aortic stenosis

Complete blood count	14.06 2016	17.06 2016	Unit	Refer- ences
White blood cells	10.93	10.63	G./L	3.60-10.50
Platelets	565	503	G./L	160-370
Red Blood Cells	3.49	4.19	T/L	3.85-5.20
HGB (Hb, hemoglobin)	7.1	8.6	g/dl	11.8-15.8
HCT (hematocrit)	23.7	28.8	%	35-45%
NEUT%	77.8	72.3	%	50.0-70.0
LYM%	11.5	153.	%	20.0-44.0
Hypochromic Ery.	53.1	41.5	%	0-.2.5%
Kreatinin	1.56	1.37	mg/dl	0.51-0.95
GFR	28.38	33.21	mL/min/1.7 m ²	>90
BUN	32	22	mg/dl	8-23
Uric Acid	8.3	8.8	mg/dl	2.4-5.7
Na	140	138	mmol/L	136-145
K	4.8	4.4	mmol/L	3.5-4.6
Chlorid	101	102	mmol/L	3.5-4.6
Iron	16		µg/dL	33-193
Transferrin	2.45		g/l	2.0-3.6
Transferrin saturation	4.63		%	16.0-45.00
Ferritin	14		µg/L	15-150
Vitamin B12	341.7		Pg/mL	197-771.0
CRP	9.4		mg/l	0.0-5.0
ESR 1h	57		mm	0-45
Calcium	2.29	2.37	mmol/L	2.05-2.40
CK	38		U/L	20-180
Troponin T- hs	32.69		ng/L	0.0-14.0
ALAT (GPT)	27		U/L	0-35.0
Gamma-GT	39		U/L	0-40
Alk.Phosphatase (AP)	71		U/L	35-105
Bilirubin	0.27		mg/dL	0.00-1.20
LDH	317		U/L	0-250
Glucose	148		mg/dL	50-100
Cholesterol	126		mg/dL	150-200
HDL-cholesterol	22		mg/dL	>65
LDL-cholesterol	--		mg/dL	60-130
Chol./HDL-Ch.-ratio	5.7		-	0-3.6
Triglyceride	198		mg/dL	50-150
Total proteins	65		g/L	66-87
TSH (hormone)	2.50		µU/ml	0.27-4.20
Hemostasis				
aPTT	48.5	28.6	sek	26.0-38.0
INR	1.84	--	---	1.07

ECG revealed sinus rhythm, HR was 74 bpm. left axis, left ventricular hypertrophy, AV-Block I, T- neg.: I, II, V5-6 (Repolarization problem) (fig.1).

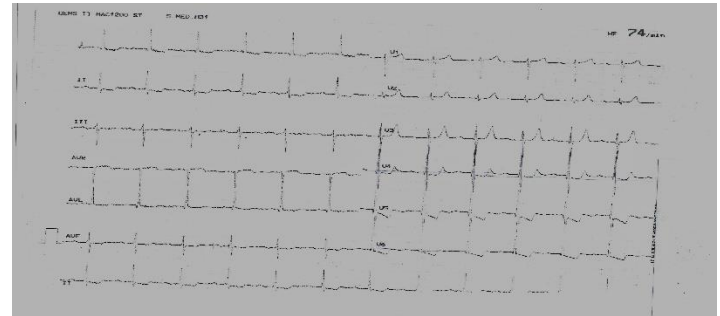

Fig. 1. ECG

Echocardiography demonstrated a normal borderline, normal Left Ventricular Ejection Fraction LVEF(EF 54%); Mitral Insufficiency grade II; Severe Aortic Stenosis, max. gradient 105 mm Hg, mean AV Pg 62 mm Hg., AVA V max/ VTI 0.8 cm², pulmonary hypertension 65 mm. Hg. (fig.2). Conclusively aortic stenosis together with mitral insufficiency and pulmonary hypertension were diagnosed.

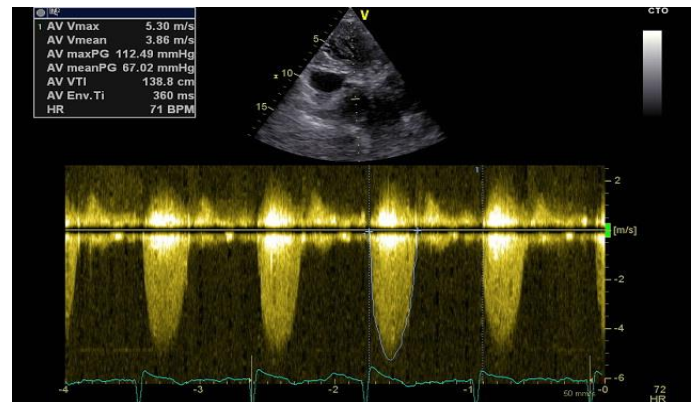


Fig. 2. Aortic valve velocity and pressure gradient.

Coronary angiography revealed coronary l-vessel stenosis with focal (about 70 %) proximal left arteria descending (LAD) stenosis.

The patient was diagnosed:

- I35.0 - Aortic (valve) stenosis, valve area 0.8 cm²
- I25.1 - Atherosclerotic heart disease. Focal stenosis proximal LAD.
- I34.0 - Mitral (valve) insufficiency.
- I13.1 - Hypertensive heart and renal disease with renal

failure

- I48. - Paroxysmal atrial fibrillation
- I50.0 - Congestive heart failure
- E14 - Diabetes mellitus
- N18.9 - Chronic renal failure
- D50 - Iron deficiency anemia.
- K57 - Sigmodivertikulosis.
- K55 - Angiodysplasia of the colon.

Treatment:

1. Oral rehydration therapy according standard protocol under the control of kidney function.
2. The earlier treatment was continued:
 - Actonel 35 mg vis Calcimagnon 1 weekly
 - Pantoloc 40 mg in the morning (1/0/0)
 - Lexotanil 3 mg in the evening (0/0/1)
 - Rasilez (aliskeren) / HCT 300 /12.5 mg in the morning (1/0/0)
 - Concor 5 mg (2.5 mg twice per day) (1/2/0/1/2)
 - Furon 40 mg (20 mg twice per day) (1/2/1/2/ 0)
 - Digimerc 0.07 mg (0.035 in the morning) (1/2/0/0)
 - Zanicid (lercanidipine) 10mg per day (0/1/0),
 - Xarelto 15 mg per day (1/0/0) (under current International Normalized Ratio (INR) and glomerular filtration rate (GFR)
 - Metformin 850 mg twice per day (1/0/1)
3. The erythrocyte concentrate infusion was successfully prescribed for treatment hypochromic microcytic anemia (no side effects with appropriate rise of Hb level).
4. Oral iron therapy for approximately 1 month, after a reassessment of the iron status. GIT examination was recommended one month after the discharge from hospital (iron therapy should be stopped for 10 days before it).
5. Transcatheter aortic valve implantation (TAVI) was considered.

Discussion

Aortic valve replacement (AVR) is the definitive therapy for severe AS. In contemporary series, operative mortality of isolated AVR for AS is 1-3% in patients younger than 70 years and 4-8% in selected older adults [1,4 - 13].

Surgery has been shown to prolong and improve quality of life, even in selected patients over 80 years of age [10 - 13].

Contraindications for transcatheter aortic valve implantation can be absolute, clinical and relative.

Absolute contraindications include:

- Absence of a 'heart team' and no cardiac surgery on the site
- Appropriateness of TAVI, as an alternative to AVR, not confirmed by a 'heart team'

Clinical contraindications comprise:

- Estimated life expectancy <1 year
- Thrombus in the left ventricle
- Active endocarditis
- Elevated risk of coronary ostium obstruction (asymmetric valve calcification, short distance between annulus and coronary ostium, small aortic sinuses)
 - Plaques with mobile thrombi in the ascending aorta, or arch
 - For transfemoral/subclavian approach: inadequate vascular access (vessel size, calcification, tortuosity)

Relative contraindications are:

- Bicuspid or non-calcified valves
- Untreated coronary artery disease requiring revascularization
 - Haemodynamic instability
 - LVEF<20%
 - For transapical approach: severe pulmonary disease, LV apex not accessible.

In patients with high surgical risk, TAVI has been shown to be feasible (procedural success rates 90%) using transfemoral, transapical or, less commonly, subclavian or direct trans-aortic access [13,14 - 22].

4 CONCLUSIONS

The Considering the patient's clinical condition: Severe aortic valve stenosis, the absence of decompensation of the cardiovascular and respiratory systems- patient is need of replacement surgery Trans catheter implantation of the aortic valve.

REFERENCES

1. Iung B., Baron G., Butchart E.G., Delahaye F., Gohlke-Barwolf C., Levang O.W., Tornos P., Vanoverschelde J.L., Vermeer F., Boersma E., Ravaut P., Vahanian A. (2003). A prospective survey of patients with valvular heart disease in Europe: the Euro Heart Survey on Valvular Heart Disease. *Eur Heart J*, 24, 1231 -1243.
2. Nkomo V.T., Gardin J.M., Skelton T.N., Gottdiener J.S., Scott C.G., Enriquez-Sarano M. Burden of valvular heart diseases: a population-based study (2006). *Lancet*, 368, 1005 -1011.
3. Schwarz F, Baumann P, Manthey J, Hoffmann M, Schuler G, Mehmel HC, et al. The effect of aortic valve replacement on survival. *Circulation* 1982;66(5):1105-10
4. Minners J., Allgeier M., Gohlke-Baerwolf C., Kienzle R.P., Neumann F.J., Jander N. Inconsistencies of echocardiographic criteria for grading of aortic valve stenosis (2008). *Eur Heart J*, 29, 1043 -1048
5. The Society of Thoracic Surgeons. Adult cardiac surgery database, executive summary, 10 years STS report (2010).
<http://www.sts.org/sites/default/files/documents/df/ndb2010/1stHarvestExecutiveSummary%5B1%5D.pdf>.
6. Bridgewater B., Keogh B., Kinsman R., Walton P. The Society for Cardiothoracic Surgery in Great Britain & Ireland, 6th national adult cardiac surgical database report; demonstrating quality 2008. Henley-on-Thames, UK: Dendrite Clinical Systems Ltd; ISBN 1-903968-23-2, published July 2009.
7. Gummert J.F., Funkat A., Beckmann A., Schiller W., Hekmat K., Ernst M., Beyersdorf F. Cardiac surgery in Germany during 2009 (2010). A report on behalf of the German Society for Thoracic and Cardiovascular Surgery. *Thorac Cardiovasc Surg*, 58, 379 -386.
8. Dewey T.M., Brown D., Ryan W.H., Herbert M.A., Prince S.L., Mack M.J. Reliability of risk algorithms in predicting early and late operative outcomes in high-risk patients undergoing aortic valve replacement (2008). *J. Thorac Cardiovasc. Surg.*, 135, 180 -187.
9. Osswald B.R., Gegouskov V., Badowski-Zyla D., Tochtermann U., Thomas G., Hagl S., Blackstone E.H. Overestimation of aortic valve replacement risk by EuroSCORE: implications for percutaneous valve replacement (2009). *Eur. Heart J.*, 30, 74 -80.
10. Brown J.M., O'Brien S.M., Wu C., Sikora J.A.H., Griffith B.P., Gammie J.S. Isolated aortic valve replacement in North America comprising 108,687 patients in 10 years: changes in risks, valve types, and outcomes in the Society of Thoracic Surgeons National Database (2009). *J Thorac. Cardiovasc Surg.*, 137, 82 -90.
11. Bardissi A.W., Shekar P., Couper G.S., Cohn L.H. Minimally invasive aortic valve replacement in octogenarian, high-risk, transcatheter aortic valve implantation candidates (2011). *J. Thorac Cardiovasc. Surg.*, 141, 328-335
12. Chukwuemeka A., Borger M.A., Ivanov J., Armstrong S., Feindel C., David T. Valve surgery in octogenarians: a safe option with good medium-term results (2006). *J. Heart Valve Dis.*, 15, 191 -196.
13. Smith C.R., Leon M.B., Mack M.J., Miller D.C., Moses J.W., Svensson L.G., Tuzcu E.M., Webb J.G., Fontana GP, Makkar RR, Williams M, Dewey T, Kapadia S, Babaliaros V, Thourani VH, Corso P, Pichard A.D., Bavaria J.E., Herrmann H.C., Akin J.J., Anderson W.N., Wang D., Pocock S.J.; PARTNER Trial Investigators. Transcatheter versus surgical aortic-valve replacement in high-risk patients (2011). *N. Engl. J. Med.*, 364, 2187 - 2198.
14. Leon M.B., Smith C.R., Mack M., Miller D.C., Moses J.W., Svensson L.G., Tuzcu E.M., Webb J.G., Fontana G.P., Makkar R.R., Brown D.L., Block .P.C., Guyton R.A., Pichard A.D., Bavaria J.E., Herrmann H.C., Douglas P.S., Petersen J.L., Akin J.J., Anderson W.N., Wang D., Pocock S.; PARTNER Trial Investigators. Transcatheter aortic-valve implantation for aortic stenosis in patients who cannot undergo surgery (2010). *N. Engl. J Med.*, 363, 1597 -1607.
15. Thomas M., Schymik G., Walther Th., Himbert D., Lefe`vre Th., Treede H., Eggebrecht H., Rubino P., Michev I., Lange R., Anderson W.N., Wendler O., on behalf of the SOURCE Investigators. Thirty-day results of the SAPIEN aortic bioprosthesis European outcome (SOURCE) registry: a European registry of transcatheter aortic valve implantation using the Edwards SAPIEN valve (2010).

Circulation , 122, 62-69.

16. Piazza N., Grube E., Gerckens U., den Heijer P., Linke A., Luha O., Ramondo A., Ussia G., Wenaweser P., Windecker S., Laborde J.C., de Jaegere P., Serruys P.W.. Procedural and 30-day outcomes following transcatheter aortic valve implantation using the third generation (18 Fr) corevalve revalving system: results from the multicentre, expanded evaluation registry 1-year following CE mark approval (2008). *EuroIntervention* ,4, 242 -249.

17. Thomas M., Schymik G., Walther T., Himbert D., Lefe`vre T., Treede H., Eggebrecht H., Rubino P., Colombo A., Lange R., Schwarz R.R., Wendler O. One-year outcomes of cohort 1 in the Edwards SAPIEN Aortic Bioprosthesis European Outcome (SOURCE) registry: the European registry of transcatheter aortic valve implantation using the Edwards SAPIEN valve (2011). *Circulation* ,124, 425 - 433.

18. Zahn R., Gerckens U., Grube E., Linke A., Sievert H., Eggebrecht H., Hambrecht R., Sack S., Hauptmann K.E., Richardt G., Figulla H.R., Senges J. The German transcatheter aortic valve interventions: registry investigators. Transcatheter aortic valve implantation: first results from a multi-centre real-world registry (2011). *Eur. Heart J.* ,32, 198 -204.

19. Eltchaninoff H., Prat A., Gilard M., Leguerrier A., Blanchard D., Fournial G., lung B., Donzeau-Gouge P., Tribouilloy C., Debrux J.L., Pavie A., Gueret P.; FRANCE Registry Investigators. Transcatheter aortic valve implantation: early results of the FRANCE (FRench Aortic National CoreValve and Edwards) registry (2011). *Eur. Heart J.* ,32, 191 - 197.

20. Tamburino C., Capodanno D., Ramondo A., Petronio A.S., Etori F., Santoro G., Klugmann S., Bedogni F., Maisano F., Marzocchi A., Poli A., Antoniucci D., Napodano M., De Carlo M., Fiorina C., Ussia G.P. Incidence and predictors of early and late mortality after transcatheter aortic valve implantation in 663 patients with severe aortic stenosis(2011). *Circulation* ,123, 299 - 308.

21. Rode´s-Cabau J., Webb J.G., Cheung A., Ye J., Dumont E., Feindel C.M., Osten M., Natarajan M.K.,

Velianou J.L., Martucci G., DeVarennes B., Chisholm R., Peterson M.D., Lichtenstein S.V., Nietlispach F., Doyle D., DeLarochellie`re R., Teoh K., Chu V., Dancea A., Lachapelle K., Cheema A., Latter D., Horlick E. Transcatheter aortic valve implantation for the treatment of severe symptomatic aortic stenosis in patients at very high or prohibitive surgical risk: acute and late outcomes of the multicenter Canadian experience (2010). *J. Am. Coll. Cardiol.*, 55, 1080 -1090.

22. Buellesfeld L., Gerckens U., Schuler G., Bonan R., Kovac J., Serruys P.W., Labinaz M., den Heijer P., Mullen M., Tymchak W., Windecker S., Mueller R., Grube E. Two-year follow-up of patients undergoing transcatheter aortic valve 2492 ESC/EACTS Guidelines by guest on June 21, 2016 <http://eurheartj.oxfordjournals.org/> Downloaded from implantation using a self-expanding valve prosthesis. *J Am Coll Cardiol* 2011; 57: 1650-1657

Received: 28-Jul. - 2016

Accepted: 20-Sep. - 2016