

REMOTE-NONCONTACT AND NON-INVASIVE DIAGNOSTICS OF GONADODYSTROPHY IN MALES

Naumenko S. V., Koshevoy V. I.

Kharkiv State Zooveterinary Academy, Kharkiv, Ukraine,
e-mail: froika001@gmail.com, vsevolod_koshevoy@yahoo.com

Summary. The results of the development and implementation of remote-noncontact and noninvasive diagnostic methods of gonadodystrophy in males are presented in the article. These methods include the use of thermal imager and ultrasound scanner. It is quite simple in implementation and can be used in veterinary medicine practice for rapid determination of the reproductive function, functional state of testes, detection or exclusion of pathological processes. The results are used to make a diagnosis and for differential diagnostics of andrological pathologies and in computer-based speculation programs for the recovery of reproductive function in males.

Keywords: males, diagnostics, gonadodystrophy, thermal imager, thermography, ultrasound scanner, sonography

Introduction. Various factors of the external and internal medium can have a negative influence on the structure and function of the testes. Among such factors, the major ones are hypokinesis, deficient state of organism, imbalance in the prooxidant-antioxidant system, toxic substances, ionizing radiation and other pathogens (Kharuta et al., 2012; Koshevoy et al., 2015).

Andrological medical examination which includes general clinical examination, biochemical (determination of homeostasis indexes such as protein, vitamins, mineral substances, hormones) and andrological examinations (genitals state, in particular testes (consistence, temperature, pain reaction), determination of sexual reflexes activity), determination of indexes of sperm quality are obligatory in veterinary medicine practice (Yablonskyi, 2002; Koshevoy et al., 2017).

The processes of andro- and spermiogenesis depend on the optimum parameters of the structure and functioning of the testes. These interdependent processes are vulnerable. Nowadays the conducted research does not allow defining the state of reproductive function in males objectively. Methods of diagnostics of andrological pathologies, in particular gonadodystrophy, must be improved (Kharuta et al., 2009; Stelletta et al., 2013; Draaisma, 2015).

The aim of the study was to develop the methods of the use of ultrasonic scanner and thermal imager in order to determine the functional state of the testes and preventive diagnostics of gonadodystrophy in males.

Materials and methods. The research was carried out in the Department of Veterinary Reproduction and in the Scientific Practical Center of Plant Breeding and Animal Husbandry of the Kharkiv State Zooveterinary Academy and on some farms of Kharkiv and Dnepropetrovsk Regions.

Twelve bulls, seventeen boars and twenty-one rabbits were examined for the research.

Animals were divided into two groups: I — with full appearance of sexual function, clinically healthy, without reproductive pathologies; II — with gonadodystrophy.

Clinical, andrological, ultrasonic, and thermographic investigations, and also some biochemical and hormonal methods of the research were used.

To determine the internal structure and consistence of the gonads the ultrasonic scanner SLE-150 was applied. The thermographic investigations of external privy parts were carried out by thermal imager TI-120 model.

The analysis of the thermogram was conducted with the help of special program 'IR Analysis Software'.

The methods of the preventive remote diagnostics of inflammatory processes in the external privy parts of males were approved in animals with normal condition and gonadodystrophy.

During the research, the temperature of stock-raising apartments was 15–17 °C, relative humidity — 60%. Digital data was worked out by biometric method.

Results. The dependence of temperature gradients of the testes from their morphological condition in bulls in thermographic research was determined. It was defined that animals with gonadodystrophy had decreased temperature gradient compared to animals with full reproductive function (Table 1).

Table 1 — Indexes of distance-project thermography of the testes of males

Species	Groups of animals	
	with a full reproductive function, M ± m	with gonadodystrophy, M ± m
Bulls	29.5 ± 0.250	28.8 ± 0.124***
Boars	30.9 ± 0.113	29.2 ± 0.185*
Rabbits	31.5 ± 0.256	30.2 ± 0.352**

Notes: * — P < 0.001, ** — P < 0.02, *** — P < 0.037 compared to full reproductive function.

In addition, differences in the indexes of thermograms were defined. In thermogram of the testes of bulls with a full reproductive function dominated 'warm' colors of the palette (red and orange) (Fig. 1). On the other hand, the

thermographic images of the testes of males with gonadodystrophy had expressive thermo-spotted area with predominance of 'cold' colors that is typical for blood circulation disorders (Fig. 2).

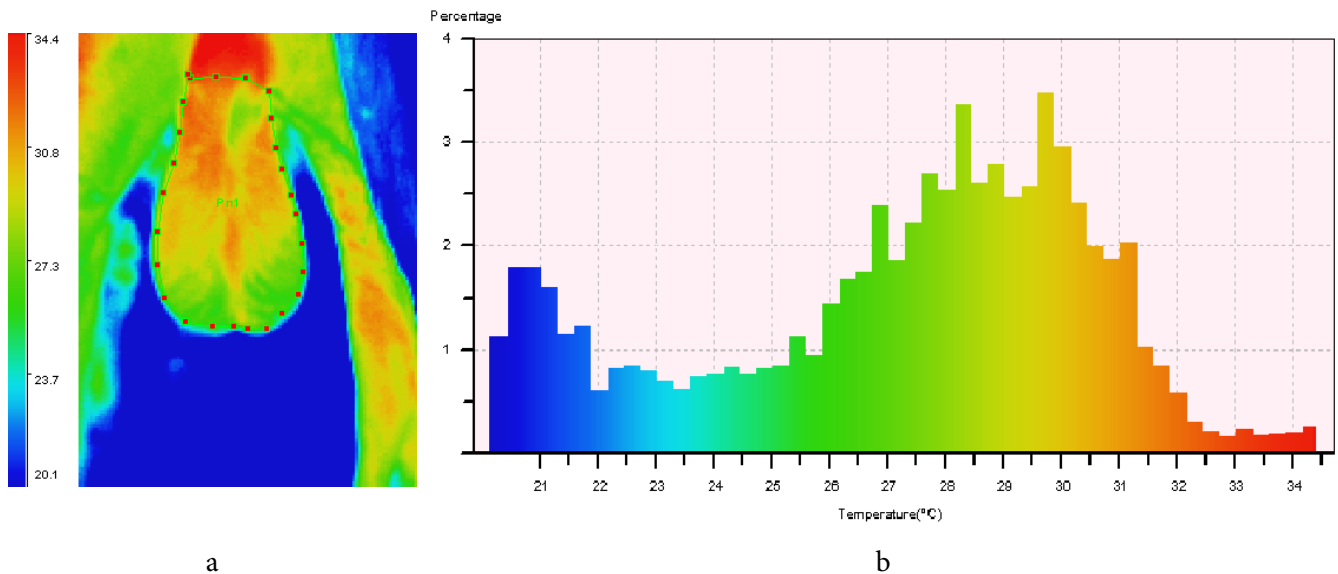


Figure 1. Thermogram of the testes of bulls with a full reproductive function: a — color palette, b — the program of read-out of indexes

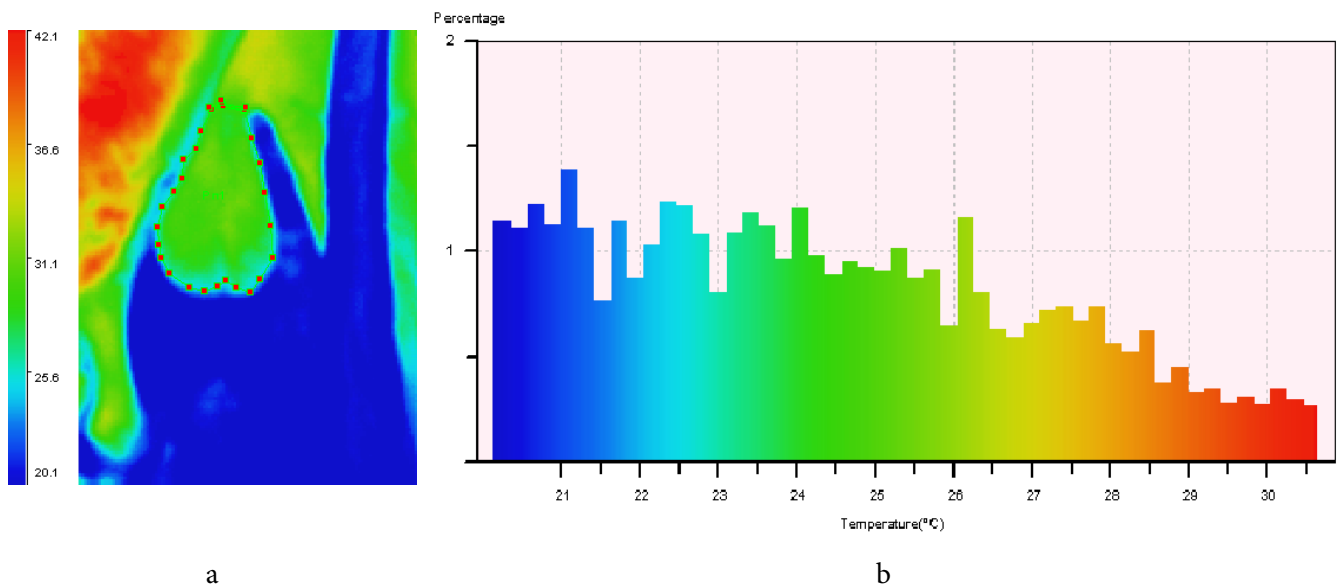


Figure 2. Thermogram of the testes of bulls with gonadodystrophy: a — color palette, b — the program of read-out of indexes

Taking into account the findings, it can be concluded that decline of temperature gradient and insignificant hypothermia area are typical for gonadodystrophy in males. Ultrasonographic method of research of the testes includes determination of increased echogenicity. The echograms of gonads were characterized by definite alternative features. Hyperechoic structure is defined by bright white spots on a black background. These spots show the surfaces with high reflecting ability, such as bones, gases, and collagen. Hypoechoic structure is

revealed by dissipated dark grey points, which show the reflection of waves from soft tissues. Non-echogenic structure is black one and appears during complete passing of waves through the medium (liquid). A computer program developed on Object Pascal was used to determine the consistence of tissue. Ultrasonograms of testes of boars are presented on Fig. 3.

In dystrophic processes in the testes tissues the increase of their size, decline of parenchyma echogenicity with maintaining of homogeneity were observed.

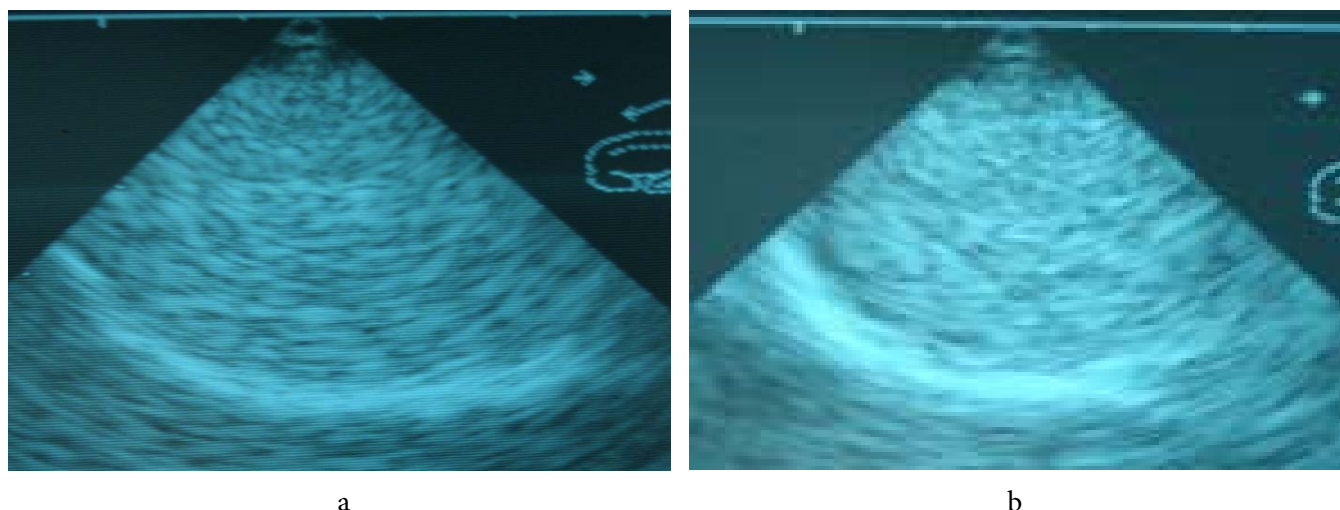


Figure 3. Ultrasonograms of testes of boars: a — with full reproductive function, b — with gonadodystrophy

Conclusion. Methods of remote-noncontact and non-invasive estimation of the gonad endostructure in males are simple in implementation and can be used in the

practice of veterinary medicine for rapid determination of full reproductive function, functional state of the testes, and the detection or exclusion of pathological processes.

References

- Draaisma, H. S. (2015) *Application of infrared scrotal thermography (IRST) under field conditions in bulls extensively managed in tropical Costa Rica, and its relationship with spermogramme, clinical variables and final breeding soundness classification*. The Master thesis. Utrecht: Utrecht University. Available at: <https://dspace.library.uu.nl/handle/1874/315633>.
- Kharuta, G. G., Podvaliuk, D. V., Lototskyi, V. V. and Baban, O. A. (2009) 'The use of sonography in livestock and veterinary medicine' [Vykorystannia sonohrafii u tvarynnystvi i veterynarii medytsyni], *Veterinary Practice [Veterynarna praktyka]*, 5, pp. 24–26. [in Ukrainian].
- Kharuta, G. G., Velbivets, M. V., Volkov, S. S. and Vlasenko, S. A. (2012) *Reproduction of livestock animals [Vidtvorennia silskohospodarskykh tvaryn]*. Bila Tserkva: Bila Tserkva National Agrarian University. ISBN 9789662122268. [in Ukrainian].
- Koshevoy, V. P., Naumenko, S. V., Koshevoy, V. I., Maliukin, Yu. V., Klochkov, V. K. and Kavok, N. S. (2015) 'Computer monitoring of the indicators of structural and functional conditions of the reproductive system organs in males at deficiency of carotene (vitamin A) and zinc' [Kompiuternyi monitorynh pokaznykiv strukturno-funktsionalnoho stanu orhaniv reproduktyvnoi systemy u samtsiv pry defitsyti karotyну (vitaminu A) ta Tsynku], *Problems of Zooengineering and Veterinary Medicine [Problemy zooinzhenerii ta veterynarnoi medytsyny]*, 31(2), pp. 62–70. Available at: [http://nbuv.gov.ua/UJRN/pzvm_2015_31\(2\)_16](http://nbuv.gov.ua/UJRN/pzvm_2015_31(2)_16). [in Ukrainian].
- Koshevoy, V. P., Naumenko, S. V., Koshevoy, V. I. and Skliarov, P. M. (2017) 'Distance non-contact and noninvasive diagnostics of pathological processes in male gonads: methodological recommendations' [Dystantsiino-bezkontaktna ta neinvaziina diahnozyka patolohichnykh protsesiv u honadakh samtsiv: metodychni rekomendatsii]. Kharkiv: Kharkiv State Zooveterinary Academy. [in Ukrainian].
- Stelletta, C., Vencato, J., Fiore, E. and Gianesella, M. (2013) 'Infrared thermography in reproduction', in Luzi, F., Mitchell, M., Nanni Costa, L. and Redaelli, V. (eds.) *Thermography: Current Status and Advances in Livestock Animals and in Veterinary Medicine*. Brescia, Italy: Fondazione Iniziative Zooprofilattiche e zootecniche, pp. 113–125. Available at: <https://www.fondiz.it/download/96/quaderni/17047/092-2013-thermography-current-status-and-advances-in-livestock-animals-and-in-veterinary-medicine.pdf>.
- Yablonskyi, V. A. (2002) *Practical obstetrics, gynecology and animal reproduction biotechnology with the basics of andrology [Praktychne akusherstvo, hinekolohiia ta biotekhnolohiia vidtvorennia tvaryn z osnovamy androlohii]*. Kyiv: Meta. ISBN 9667947033. [in Ukrainian].