УДК616.441

R.P.Tkachenko[1], O.G.Kuryk[1, 2], A.S.Golovko[2], A.I. Denisenko[1]

MEDULLARY CARCINOMA OF THYROID: CASE REPORT AND A REVIEW OF LITERATURE

State Scientific Institution "Scientific-Practical Centre of Preventive and Clinical Medicine" State Administration of Affairs, Kyiv[1]
Bogomolets National Medical University, Kyiv [2]

Резюме

МЕДУЛЯРНА КАРЦИНОМА ЩИТОПОДІБНОЇ ЗАЛОЗИ: ВИПАДОК З ПРАКТИКИ І ОГЛЯД ЛІТЕРАТУРИ
Ткаченко Р.П.[1], Курик О.Г.[1, 2], Головко А.С.[2], Денисенко А.І.[1]
Державна наукова установа «Науково-практичний центр профілактичної та клінічної медицини»
Державного управління справами, Київ[1]
Національний медичний університет імені О.О. Богомольця, Київ[2]

Медулярна карцинома щитоподібної залози (МКЩЗ) є рідкісним захворюванням, яке становить приблизно 4–5% всіх випадків раку щитовидної залози і походить з кальцитонін-секретуючих парафолікулярних С-клітин. МКЩЗ часто поширюється на шийні лімфатичні вузли. Зустрічається у спорадичних (75-80%) і сімейних (20-25%) формах.
Представлений випадок МКЩЗ з метастазами в шийні лімфатичні вузли у 67-річної жінки. Пацієнтці була проведена тотальна тиреоїдектомії з шийною лімфодисекцією. Заключний патогістологічний діагноз підтвердив МКЩЗ. Були виявлені метастази у двох лімфатичних вузлах 6 групи і у двох лімфатичних вузлах 2,3.4 груп зліва.
В обговоренні представлений огляд класифікацій, патогенезу, діагностики та лікування МКЩЗ. Зазначено, що у нашої пацієнтки через шість місяців після операції не виявлено рецидиву або метастазів МКЩЗ.
Отже, МКЩЗ є рідкісним новоутворення щитовидної залози, характеризуется частым метастазированием и поганим прогнозом за відсутністю лікування. Рання діагностика забезпечує більш високу вірогідність успішного лікування і довгострокового виживання. Тотальна тиреоїдектомія з лімфодисекцією шиї є основою лікування. Всі пацієнти повинні проходити регулярне обстеження з метою можливого виявлення рецидиву або метастазів МКЩЗ.

Ключові слова: **медулярна карцинома щитоподібної залози, спорадичні форми, тиреоїдектомія, шийна лімфодисекція, кальцитонін.**

INTRODUCTION

Medullary thyroid carcinoma (MTC) is a rare disease that accounts 4-5% of all thyroid cancers and originates from the calcitonin-screening parafollicular C cells [7]. Parafollicular C-cells secrete a number of peptide hormones such as calcitonin, serotonin, vasoactive intestinal peptide, such as a neuroendocrine tumor [3]. MTC may cause death if untreated [20].

MTC can be sporadic or familial, the latter of which is defined as part of the cancer syndrome known as Multiple Endocrine Neoplasia type 2 (MEN2) [17]. MEN2 is the result of an autosomally dominant gain-of-function mutation in the RET (REarranged during Transfection) proto-oncogene [5]. The sporadic form occurs in 70% of the cases, and familial form in 10-20% of all cases [4]. The preoperative diagnosis is based on the results of thyroid fine-needle aspiration cytology (FNAC), serum calcitonin level, and RET protooncogene testing [12]. In 10–15% of cases, diagnosis of MTC is made only after thyroidectomy. Histologically tumor containing hyperplastic parafollicular C-cells. Sporadic MTC generally presents as a single tumor in the one thyroid lobe [17]. Metastasis occur in 40% of all cases of MTC [20].

We present the case report of patient with sporadic MTC with metastasis.

CASE REPORT

A 67-year-old woman referred to endocrinologist with an anterior neck mass. An ultrasound examination of his neck showed a 1,5 cm solid hypoechoic nodule of the left thyroid lobe, and the metastatic lymph nodes was noticed. The right thyroid lobe and the isthmus were normal. Serum levels of triiodothyronine and thyroxine were within normal ranges, and anti-thyroglobulin antibody were negative. A preoperative calcitonin serum value was 240 ng/L. She had normal serum levels of calcium, phosphorus and parathyroid hormone. FNAC biopsy of the nodule was consistent with a diagnosis of MTC. Our patient underwent a total thyroidectomy with neck exploration. An enlarged thyroid gland with a prominent left lobe were detected during the operation (Figure 1). A neck dissection yielded six regional lymph nodes of 6 group, twenty lymph nodes of 2,3.4 groups in left side and eighteen lymph nodes of 2,3.4 groups in right side. Surgical specimens were fixed in 10% buffered formalin, embedded in paraffin, and stained with hematoxylin and eosin. For immunohistochemical studies, sections were incubated with the following primary monoclonal antibodies: chromogranin A, thyroglobulin, and calcitonin (Dako Corporation, Glostrup, Denmark). In light microscopy, two lesions in the left lobe of thyroid were found. The tumor was limited to thyroid capsule. Two nodules consisted of sheet-like cells with round nuclei and clumped chromatin with amphophilic cytoplasm. Mitotic activity was low. The stroma contained a homogeneous and pink ground substance. Tumor cells were immunoreactive for calcitonin, chromogranin A, and were negative for thyroglobulin. There were found two lymph nodes of 6 group and two lymph nodes of 2,3.4 groups in left side with metastasis of medullary carcinoma. Pathologic findings in thyroid gland are showed in the figures 2 and figures 3, which reveal neoplastic proliferation of parafollicular cells in nesting pattern with amorphous eosinophilic material depositions in stroma.

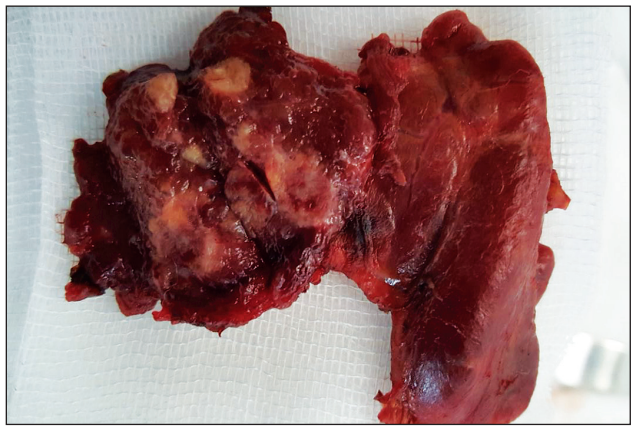

Fig. 1. Specimen showing total thyroidectomy in the patient

DISCUSSION

MTC is a neuroendocrine tumor of the parafollicular C cells of the thyroid gland. And accounts 4-5% of thyroid carcinomas [7]. MTC can be sporadic or familial, which is defined as part of the cancer syndrome known as Multiple Endocrine Neoplasia type 2 (MEN2) [17]. Germline mutations of the RET proto-oncogene found on chromosome 10q11 are responsible for familial MTC sand may be present in more than 95% of the hereditary MTC and about only 25% of the sporadic MTC [5,12].

The prognosis of MTC is better than the poorly-differentiated, malignant, anaplastic thyroid cancer, but is worse than the more well-differentiated and benign papillary and follicular thyroid cancers [9]. Therefore,

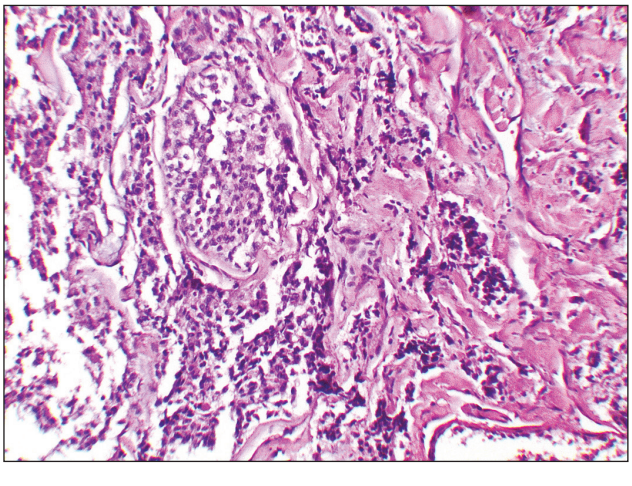

Fig. 2. Medullary thyroid carcinoma with nesting proliferation of neoplastic parafollicular cells with stromal amorphous material deposition. Hematoxylin and eosin (H & E) staining. x200.

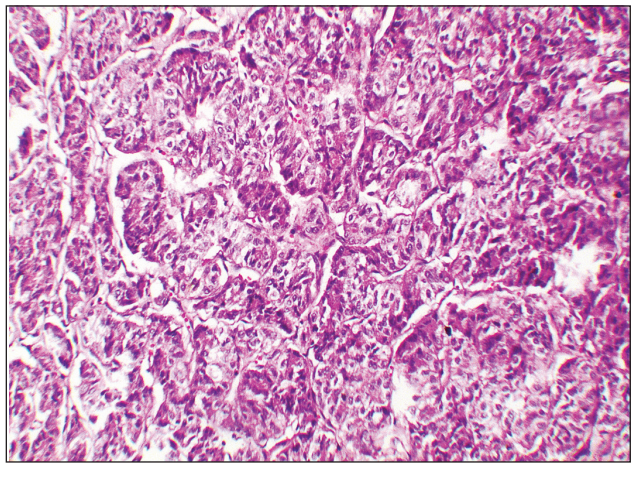

Fig. 3. Medullary thyroid carcinoma. Polygonal cells with eosinophilic cytoplasm and little mitosis. Hematoxylin and eosin (H & E) staining. x200.

early diagnosis is necessary for improving recurrence and survival rates among these patients [20].

The most common presentation of sporadic MTC is a painless solitary thyroid nodule, and multifocality and bilaterally nodules of the hereditary forms. Cervical lymph node metastasis is approximately found in 50% of the cases, whereas distant metastases are present in 10% of the cases; higher incidence being those with large tumor size or multifocal tumors [18]. In our study, the female presented with multiple nodules and cervical metastasis.

The literature states that MTC included various histological types: encapsulated, follicular, oncocytic, squamous, cribriform, rosette formation, osteogenic sarcoma type, and pseudopapillary types [22]. The histology did not seem to influence the course of the disease.

Calcitonin is the most sensitive and specific tumor marker at the preoperative diagnosis and the post surgery follow up. Calcitonin values decrease into the normal range after resection of the tumor. Thus, according to the American Thyroid Association, it is not routinely recommended and hence preoperative normal calcitonin value always cannot exclude the diagnosis of MTC [19]. Another biomarker, Carcinoembrionic Antigen (CEA,) is also produced by the neoplastic C-cells, and it has been useful in predicting the prognosis of MTC patients, more importantly when preoperative serum calcitonin values are negative [16]. CEA may be found in more than 50% of the MTC patients, and levels above 30 ng/ml strongly indicate a poor prognosis [25]. It is also seen that CEA values more than 100 ng/mL are found to be associated with extensive lymph node involvement and distant metastasis [25]. Our patient had significantly raised level of serum calcitonin which regressed to following the surgery.

Neck ultrasound should be performed as the traditional approach to thyroid nodules. Although MTC has no classical feature on ultrasound, it can be helpful to show the nodule characteristics, enlarged lymph nodes. FNAC is usually the first line of investigation for diagnosing thyroid nodules [2, 8]. In our case, classical features of MTC in FNAC were seen which included plasmacytoid appearance of cells and multiple spindle-shaped cells.

Total thyroidectomy along with central compartment neck dissection is the treatment of choice for the patients with medullary carcinoma of thyroid. The incidence of central neck metastasis can be as high as 80% in patients with palpable tumors and thus, central compartment neck dissection provides a better survival and cure rate than total thyroidectomy alone [23]. In respect that a huge risk of neck metastasis, even in tumors less than 1 cm, many surgeons do recommend bilateral lateral neck dissection in all patients with MTC [24].

In the 2009 American Thyroid Association guidelines for the surgical management of MTC, the extent of calcitonin preoperative elevation guides the selection of preoperative imaging studies, which in turn influence the extent of surgery [10]. A majority of guideline authors agreed to a consensus view that sporadic MTC should be treated with total thyroidectomy and central node dissection. The ipsilateral level II–V dissection is best justified by suspicious lymph nodes on examination [11]. A prophylactic approach to ipsilateral neck dissection is favored by some authors because the incidence of lateral node metastases in macroscopic MTC is roughly 80% [6].

All patients with MTC who limited to the thyroid gland without neck node involvement tend to have a low recurrence rate and rarely die from their disease [13]. A lot of patients with MTC with nodal metastasis have a great risk for developing recurrent or persistent disease. They have to be on a strict postoperative follow-up and monitoring. The postoperative follow-up should begin 2-3 months after operation and it is based on serum calcitonin and CEA levels. For localization of the recurrence or residue of the MTC, scintigraphic methods are used with the radio-labeled molecules [14]. Our patient through six months after operation have no recurrence or residue of the MTC.

The prognosis for patients with MTC with a 10-year survival rate being 75-85% [20]. About 50% of the patients with MTC have disease restricted to the thyroid gland, and have a 10-year survival rate of 95%. About 30% of the patients have locally invasive tumors or with metastasis to the regional lymph nodes. Distant metastases may be seen in 13% of the patients at the initial diagnosis and have a poor prognosis, with a 10-year survival rate of only 40%.

Radio-active iodine therapy seems to have no role in MTC as the tumor originates from parafollicular C-cells which do not accumulate iodine [21]. Both radiation therapy and conventional chemotherapy have limited place in the treatment of patients with MTC [15].

CONCLUSION

MTC being an uncommon and a rare thyroid malignancy, its management is different than that for differentiated thyroid cancers. Early diagnosis offers a successful cure and long-term survival. Total thyroidectomy plus central compartment neck dissection is the mainstay of treatment. All patients must be kept on regular follow-up to avoid recurrence.

ЛІТЕРАТУРА

1. Almeida M. Q., Hoff A. O. Recent advances in the molecular pathogenesis and targeted therapies of medullary thyroid carcinoma. Curr Opin Oncol. 2012. 24. 229-34.
2. Alagarsamy J., Satish S., Nirmala. Cytological diagnosis of metastatic medullary thyroid
carcinoma: a case report. Int J Adv Med. 2015. 2. 51-3.
3. Balakrishnan V., Saroshkumar K. K., Sarin S. M. A Rare Presentation of Medullary Carcinoma Thyroid. Journal of Medical Case Reports. 2016. Vol. 4. No. 1. 8-11.
4. Barbieri R. B., Bufalo N. E., Secolin R., Silva A. C., Assump o L. V., Maciel R. M., Cerutti J. M., Ward L. S. Evidence that polymorphisms in detoxification genes modulate the susceptibility for sporadic medullary thyroid carcinoma. Eur J Endocrinol. 2012. 166(2). 241–5.
5. Cakir M., Grossman A. B. Medullary thyroid cancer: Molecular biology and novel molecular therapies. Neuroendocrinology. 2009. 90. 323-48
6. Greenblatt D. Y., Elson D., Mack E., Chen H. Initial lymph node dissection increases cure rates in patients with medullary thyroid cancer. Asian J Surg. 2007. 30. 108-12.
7. Grozinsky-Glasberg S., Benbassat C. A., Tsvetov G., Feinmesser R., Peretz H., Shimon I, Medullary thyroid cancer: A retrospective analysis of a cohort treated at a single tertiary care center between 1970 and 2005. Thyroid. 2007. 17. 549-56.
8. Hsieh M. H., Hsiao Y. L., Chang T. C. Fine needle aspiration cytology stained with Rius method in quicker diagnosis of medullary thyroid carcinoma. J Formos Med Assoc. 2007. 106. 728-35
9. Hung W. W., Wang C. S., Tsai K. B., Ou-Yang F., Shin S. J., Hsiao P. J. Medullary thyroid carcinoma with poor differentiation and atypical radiographic pattern of metastasis. Pathol Int. 2009. 59. 660-3.
10. Kloos R. T., Eng C., Evans D. B., Francis G. L., Gagel R. F., Gharib H., Moley J. F., Pacini F., Ringel M. D., Schlumberger M. Medullary thyroid cancer: management guidelines of the American Thyroid Association. Thyroid. 2009. 19. 565–612.
11. Links T. P., Verbeek H. H., Hofstra R. M., Plukker J. T. Endocrine tumours: Progressive metastatic medullary thyroid carcinoma: First- and second-line strategies. Eur J Endocrinol. 2015. 172. R241-51.
12. Machens A., Hauptmann S., Dralle H. Increased risk of lymph node metastasis in multifocal hereditary and sporadic medullary thyroid cancer. World J Surg. 2007. 31. 1960-5.
13. Machens A., Hofmann C., Hauptmann S., Dralle H. Locoregional recurrence and death from medullary thyroid carcinoma in a contemporaneous series: 5-year results. Eur J Endocrinol. 2007. 157. 85-93.
14. Maia A. L., Siqueira D. R., Kulcsar M. A., Tincani A. J., Mazeto G. M., Maciel L. M. Diagnosis, treatment, and follow-up of medullary thyroid carcinoma: Recommendations by the Thyroid Department of the Brazilian Society of Endocrinology and Metabolism. Arq Bras Endocrinol Metabol. 2014. 58. 667-700.
15. Meijer J. A., Bakker L. E., Valk G. D., de Herder W. W., de Wilt J. H., Netea-Maier R. T., Radioactive iodine in the treatment of medullary thyroid carcinoma: A controlled multicenter study. Eur J Endocrinol. 2013. 168. 779-86.
16. Meijer J. A., le Cessie S., van den Hout W. B., Kievit J., Schoones J. W., Romijn J. A. &Smit J. W. Calcitonin and carcinoembryonic antigen doubling times as prognostic factors in medullary thyroid carcinoma: a structured meta-analysis. Clinical Endocrinology. 2010. Vol. 72(No.4). 534-542.
17. Moo-Young T. A., Traugott A. L., Moley J. F. Sporadic and familial medullary thyroid carcinoma: State of the art. Surg Clin North Am. 2009. 89. 1193-204.
18. Mozafar M., Sobhiyeh M. R., Tadayon N., Bolouri N. Cervical Lymph Node Involvement by Medullary Carcinoma of Unknown Origin; a Rare Presentation. Int J Endocrinol Metab. 2010. 1. 51—54.
19. Panagiotakou A., Ioannidis D., Lilis D., Karageorgos G. "Atypical" Non-Secretory Medullary Thyroid Carcinoma: Case Report and Review of the Literature. Endocrinol Metab Int J. 2017. 4(3). 00085.
20. Roman S., Lin R., Sosa J. A. Prognosis of medullary thyroid carcinoma: Demographic, clinical, and pathologic predictors of survival in 1252 cases. Cancer. 2006. 107. 2134-42.
21. Roy M., Chen H., Sippel R. S. Current understanding and management of medullary thyroid cancer. Oncologist. 2013. 18. 1093-100.
22. Priya R., Virmani N., Dabholkar J. P. Medullary carcinoma of thyroid: Case report and a review of literature. J Head Neck Physicians Surg. 2016. 4. 80-4.
23. Scollo C., Baudin E., Travagli J. P., Caillou B., Bellon N., Leboulleux S. Rationale for central and bilateral lymph node dissection in sporadic and hereditary medullary thyroid cancer. J Clin Endocrinol Metab. 2003. 88. 2070-5
24. Sippel R. S., Kunnimalaiyaan M., Chen H. Current management of medullary thyroid cancer. Oncologist. 2008. 13. 539-47.
25. vanVeelen W., de Groot J. W., Acton D. S., Hofstra R. M., H ppener J. W., Links T. P. &Lips C. J. Medullary thyroid carcinoma and biomarkers: past, present and future. Journal of Internal Medicine. 2009. Vol. 266(No.1). 126-140.

REFERENCES

1. Almeida M. Q., Hoff A. O. (2012). Recent advances in the molecular pathogenesis and targeted therapies of medullary thyroid carcinoma. Curr Opin Oncol., 24, 229-34.
2. Alagarsamy J., Satish S., Nirmala. (2015). Cytological diagnosis of metastatic medullary thyroid carcinoma: a case report. Int J Adv Med., 2, 51-3.
3. Balakrishnan V., Saroshkumar K. K., Sarin S. M. (2016). A Rare Presentation of Medullary Carcinoma Thyroid. Journal of Medical Case Reports., 4, 1, 8-11.
4. Barbieri R. B., Bufalo N. E., Secolin R., Silva A. C., Assump o L. V., Maciel R. M., Cerutti J. M., Ward L. S. (2012). Evidence that polymorphisms in detoxification genes modulate the susceptibility for sporadic medullary thyroid carcinoma. Eur J Endocrinol., 166(2), 241–5.
5. Cakir M., Grossman A. B. (2009). Medullary thyroid cancer: Molecular biology and novel molecular therapies. Neuroendocrinology, 90, 323-48
6. Greenblatt D. Y., Elson D., Mack E., Chen H. (2007). Initial lymph node dissection increases cure rates in patients with medullary thyroid cancer. Asian J Surg., 30, 108-12.
7. Grozinsky-Glasberg S., Benbassat C. A., Tsvetov G., Feinmesser R., Peretz H., Shimon I. (2007). Medullary thyroid cancer: A retrospective analysis of a cohort treated at a single tertiary care center between 1970 and 2005. Thyroid, 17, 549-56.

8. Hsieh M. H., Hsiao Y. L., Chang T. C. (2007). Fine needle aspiration cytology stained with Rius method in quicker diagnosis of medullary thyroid carcinoma. J Formos Med Assoc., 106, 728-35
9. Hung W. W., Wang C. S., Tsai K. B., Ou-Yang F., Shin S. J., Hsiao P. J. (2009). Medullary thyroid carcinoma with poor differentiation and atypical radiographic pattern of metastasis. Pathol Int., 59, 660-3.
10. Kloos R. T., Eng C., Evans D. B., Francis G. L., Gagel R. F., Gharib H., Moley J. F., Pacini F., Ringel M. D., Schlumberger M. (2009). Medullary thyroid cancer: management guidelines of the American Thyroid Association. Thyroid., 19, 565–612.
11. Links T. P., Verbeek H. H., Hofstra R. M., Plukker J. T. (2015). Endocrine tumours: Progressive metastatic medullary thyroid carcinoma: First- and second-line strategies. Eur J Endocrinol., 172, R241-51.
12. Machens A., Hauptmann S., Dralle H. (2007). Increased risk of lymph node metastasis in multifocal hereditary and sporadic medullary thyroid cancer. World J Surg., 31, 1960-5.
13. Machens A., Hofmann C., Hauptmann S., Dralle H. (2007). Locoregional recurrence and death from medullary thyroid carcinoma in a contemporaneous series: 5-year results. Eur J Endocrinol., 157, 85-93.
14. Maia A. L., Siqueira D. R., Kulcsar M. A., Tincani A. J., Mazeto G. M., Maciel L. M. (2014). Diagnosis, treatment, and follow-up of medullary thyroid carcinoma: Recommendations by the Thyroid Department of the Brazilian Society of Endocrinology and Metabolism. Arq Bras Endocrinol Metabol., 58, 667-700.
15. Meijer J. A., Bakker L. E., Valk G. D., de Herder W. W., de Wilt J. H., Netea-Maier R. T. (2013). Radioactive iodine in the treatment of medullary thyroid carcinoma: A controlled multicenter study. Eur J Endocrinol., 168, 779-86.
16. Meijer J. A., le Cessie S., van den Hout W. B., Kievit J., Schoones J. W., Romijn J. A. &Smit J. W. (2010). Calcitonin and carcinoembryonic antigen doubling times as prognostic factors in medullary thyroid carcinoma: a structured meta-analysis. Clinical Endocrinology, 72(4), 534-542.
17. Moo-Young T. A., Traugott A. L., Moley J. F. (2009). Sporadic and familial medullary thyroid carcinoma: State of the art. Surg Clin North Am., 89, 1193-204.
18. Mozafar M., Sobhiyeh M. R., Tadayon N., Bolouri N. (2010). Cervical Lymph Node Involvement by Medullary Carcinoma of Unknown Origin; a Rare Presentation. Int J Endocrinol Metab., 1, 51-54.
19. Panagiotakou A., Ioannidis D., Lilis D., Karageorgos G. (2017). “Atypical” Non-Secretory Medullary Thyroid Carcinoma: Case Report and Review of the Literature. Endocrinol Metab Int J., 4(3), 00085.
20. Roman S., Lin R., Sosa J. A. (2006). Prognosis of medullary thyroid carcinoma: Demographic, clinical, and pathologic predictors of survival in 1252 cases. Cancer, 107, 2134-42.
21. Roy M., Chen H., Sippel R. S. (2013). Current understanding and management of medullary thyroid cancer. Oncologist., 18, 1093-100.
22. Priya R., Virmani N., Dabholkar J. P. (2016). Medullary carcinoma of thyroid: Case report and a review of literature. J Head Neck Physicians Surg., 4, 80-4.
23. Scollo C., Baudin E., Travagli J. P., Caillou B., Bellon N., Leboulleux S. (2003). Rationale for central and bilateral lymph node dissection in sporadic and hereditary medullary thyroid cancer. J Clin Endocrinol Metab., 88, 2070-5.
24. Sippel R. S., Kunnimalaiyaan M., Chen H. (2008). Current management of medullary thyroid cancer. Oncologist., 13, 539-47.
25. vanVeelen W., de Groot J. W., Acton D. S., Hofstra R. M., H ppener J. W., Links T. P. &Lips C. J. (2009). Medullary thyroid carcinoma and biomarkers: past, present and future. Journal of Internal Medicine., 266(1), 126-140.

Резюме

МЕДУЛЛЯРНАЯ КАРЦИНОМА ЩИТОВИДНОЙ ЖЕЛЕЗЫ: СЛУЧАЙ ИЗ ПРАКТИКИ И ОБЗОР ЛИТЕРАТУРЫ

Ткаченко Р.П.[1], Курик Е.Г.[1, 2], Головко А.С.[2], Денисенко А.И.[1]
Государственное научное учреждение «Научно-практический центр профилактической и клинической медицины» Государственного управления делами, Киев[1]
Национальный медицинский университет имени А.А. Богомольца, Киев[2]

Медуллярная карцинома щитовидной железы (МКЩЗ) является редким заболеванием, которое составляет приблизительно 4-5% от всех видов рака щитовидной железы и происходит из кальцитонин-секретирующих парафолликулярных С-клеток. МКЩЗ - редкая злокачественная опухоль, которая часто метастазирует в шейные лимфатические узлы. Встречается в спорадических (75-80%) и семейных (20-25%) формах.
Представлен случай МКЩЗ с метастазами в шейные лимфатическое узлы у 67-летней женщины. Пациентке была проведена тотальная тиреоидэктомия с шейной лимфодиссекцией. Заключительный патогистологический диагноз подтвердил МКЩЗ. Были обнаружены метастазы в двух лимфатических узлах 6 групп и двух лимфатических узлах 2,3,4 групп слева.
В обсуждении представлен обзор классификаций, патогенеза, морфологической картины, диагностики и лечения МКЩЗ. Отмечено, что у нашей пациентки через шесть месяцев после операции не выявлено рецидива или метастазов МКЩЗ.

Таким образом, МКЩЗ является редким злокачественным новообразованием щитовидной железы, характеризуется частым метастазированием и плохим прогнозом при отсутствии лечения. Ранняя диагностика дает более высокую вероятность успешного излечения и долгосрочного выживания. Тотальная тиреоидэктомия с лимфодиссекцией шеи являются основой лечения. Все пациенты должны проходить регулярное обследование с целью возможного выявления рецидива или метастазов МКЩЗ.

Ключевые слова: **медуллярная карцинома щитовидной железы, спорадическая форма, тотальная тиреоидэктомия, лимфодиссекция шеи, кальцитонин.**

Summary

MEDULLARY CARCINOMA OF THYROID: CASE REPORT AND A REVIEW OF LITERATURE

R.P.Tkachenko[1], O.G.Kuryk[1, 2], A.S.Golovko[2], A.I. Denisenko[1]
State Scientific Institution "Scientific-Practical Centre of Preventive and Clinical Medicine" State Administration of Affairs, Kyiv[1]
Bogomolets National Medical University, Kyiv[2]

Medullary thyroid carcinoma (MTC) is a rare disease which accounts for approximately 4-5% of all thyroid cancers and originates from the calcitonin-screening parafollicular C cells. MTC is a rare malignancy, which frequently spreads to cervical lymph nodes. Occurring in both the sporadic (75-80%) and familial (20-25%) forms.
We report a case of MTC with neck nodal's metastasis in 67-year-old woman. Our patient underwent a total thyroidectomy with neck exploration. Final histopathology came out to be medullary carcinoma of the thyroid. There were found two lymph nodes of 6 group and two lymph nodes of 2,3.4 groups in left side with metastasis of MTC.
In the review we provide a general overview of the classification, pathology, and clinical management of MTC. Our patient through six months after operation have no recurrence or residue of the MTC.
So, MTC being an uncommon and a rare thyroid malignancy, its management is different than that for differentiated thyroid cancers. Early diagnosis offers a successful cure and long-term survival. Total thyroidectomy plus central compartment neck dissection is the mainstay of treatment. All patients must be kept on regular follow-up to avoid recurrence.

Keywords: **medullary thyroid carcinoma, sporadic, total thyroidectomy, neck dissection, calcitonin**

ІНФОРМАЦІЯ ПРО АВТОРІВ:

Ткаченко Римма Петрівна - к. мед. н., науковий співробітник наукового відділу малоінвазивної хірургії ДНУ «НПЦ ПКМ» ДУС, 01014 м. Київ, вул. Верхня 5, тел. (044) - 284- 62-72; моб. 067-700-68-27.
e-mail: rimmatkachenko@i.ua

Курик Олена Георгіївна - головний науковий співробітник наукового відділу малоінвазивної хірургії, Державна Наукова Установа «Науково-практичний центр профілактичної і клінічної медицини» Державного Управління Справами, м. Київ, вул. Верхня, 5;
тел. (044) 284-61-03; моб. 067-647-17-35
профессор кафедри патологічної анатомії №1 (за сумісництвом, 0,5 посади) НМУ ім. О.О. Богомольця
O_Kurik@ukr.net

Головко Алла Сергіївна, студентка 6 курсу I медичного факультету Національного медичного університету імені О.О.Богомольця, м.Київ, бульвар Шевченка, 13.
Тел.моб. 063-218-91-42
e-mail: golovko-alla@ukr.net

Денисенко Анатолій Іванович – старший науковий співробітник наукового відділу малоінвазивної хірургії ДНУ «Науково-практичний центр профілактичної та клінічної медицини» ДУС; м.Київ, вул. Верхня, 5,
тел. (044) - 284- 62-72; моб. 067-284-09-95
anatolyd@ukr.net