

FLUORESCENT DIAGNOSIS AND PHOTODYNAMIC THERAPY FOR C6 GLIOMA IN COMBINATION WITH ANTIANGIOGENIC THERAPY IN SUBCUTANEOUS AND INTRACRANIAL TUMOR MODELS

D.A. Tzerkovsky*, V.V. Osharin, Y.P. Istomin, E.N. Alexandrova, M.A. Vozmitel
N.N. Alexandrov National Cancer Center of Belarus, 223040 Minsk, Belarus

Objective: Investigating the distinctions pharmacokinetics of chlorin e6 conjugated with polyvinyl pyrrolidone photosensitizer (Ce6CPPPS) in healthy and tumor tissues of rat brain and evaluating the antitumor efficacy of combination treatment for C6 rat glioma including photodynamic (PDT) and antiangiogenic therapy (AAT). **Materials and Methods:** The study was performed on 50 white random-bred rats in subcutaneous and intracranial models of C6 glioma. Photosensitizer (PS) Ce6CPPPS single injection at a dose of 2.5 mg/kg was made into the animal's caudal vein. The PS accumulation level in brain tissues and C6 rat glioma was measured with spectral fluorescence technique using LESA-01-Biospek spectrum analyser (Russian Federation, Moscow; $\lambda = 632.8$ nm). Photoirradiation of intracranial and subcutaneous C6 glioma was carried out with a light exposure dose of 50 J/cm² (IMAF-Axicon, Republic of Belarus; $\lambda = 661$ nm). AAT drug bevacizumab, single injection was made intravenously at a dose of 10 mg/kg 24 h after tumor photoirradiation. The criteria for efficacy evaluation were mean survival time (MST) and median survival of the animals in the study group vs the control and the percentage of tumor necrosis areas induced by the above-mentioned treatment. **Results:** The optimal time for photoirradiation of intracranial C6 glioma is 0.5 h after Ce6CPPPS injection. The combination therapy group demonstrated a statistically significant MST increase (38.4 ± 4.39 days) compared with the PDT group (29.2 ± 3.5 days) ($p = 0.02$) and the AAT group (27.1 ± 2.74 days) ($p = 0.02$). Necrosis areas in tumor tissue were as follows: the intact control — $10.0 \pm 2.55\%$, PDT — $54.87 \pm 6.95\%$ ($p = 0.003$), AAT — $57.83 \pm 6.53\%$ ($p = 0.003$) and combination therapy — $89.43 \pm 5.57\%$ ($p = 0.001$). **Conclusions:** This paper is the first report about feasibility of efficient use of PDT with a PS of chlorin series and AAT with bevacizumab for the treatment of brain tumors in experimental models. **Key Words:** Ce6CPPPS, bevacizumab, glioma C6, photodynamic therapy, antiangiogenic therapy.

Malignant brain tumors have acquired social significance, being in many respects an unsettled issue. Over the past decade, the mean malignant brain tumors incidence rate of 550 new patients a year was registered in Belarus [1]. The malignant brain tumors treatment includes combination modalities: surgical ablation of the tumor, radio- and chemotherapy. The major limitation for surgical intervention is insufficient visualization of tumor margins and its location in functionally important brain areas. In most of cases radical tumor resection is impossible as the excision of healthy brain tissue with tumor cells infiltrating it may cause severe neurological morbidity. Radio- and chemotherapy are employed mainly in the post-operative period to affect the area of subclinical tumor spread. The median survival after radiotherapy does not exceed 10–12 months, after stereotaxic radiotherapy — 5–14 months, with surgery or radiosurgery in combination with radiotherapy — 12–16 months [2–4]. Local (interstitial) hyperthermia, laser therapy, exposure of focused ultrasound have certain potentials for malignant brain tumors. However, the aforesaid treatment modalities have limited indications for their use. They are mostly utilized in the cases of conventional treatment modalities failing to produce the expected curative effect [5, 6].

At present, the current malignant brain tumors treatment modalities have reached their limits. A painstaking search is being made for novel alternative treatment modes for this disease. One of them

is photodynamic therapy (PDT). The PDT technique is based on the use of the effect of selective laser photodestruction of tumor tissue sensitized beforehand. The efficacy of photodynamic damage of the sensitized cell is determined by intracellular concentration and location of the sensitizer, its photochemical activity and the light dose of laser irradiation [7, 8].

A number of experiments *in vitro* [9–11] and *in vivo* [12, 13], as well as clinical studies [14, 15] confirmed PDT efficacy for brain tumors, using hematoporphyrins, aminolevulinic acid derivatives and chlorins as photosensitizers (PS).

In the recent years, several scientific studies dealt with investigation of neoangiogenesis in brain tumors and sought new ways to disrupt its links. One of such avenues is antiangiogenic therapy (AAT). Since glial tumors are among the most vascularized ones, they are an excellent target to be hit by AAT. The inhibition of vascular endothelial growth factor (VEGF) expression resulted in considerably reduced growth of glial cells. Moreover, AAT administration facilitated restoration of normal blood flow, decreased hypoxia and increased of tumor cell sensitivity to radio- and chemotherapy [16].

The most known and advantageous drug in VEGF blocker series is bevacizumab which is a humanized monoclonal antibody. The first findings on possible efficiency of bevacizumab in combination with irinotecan in high-grade glioma management were published by V. Stark-Vance in 2005. The objective response rate in his study was 43% [17–19].

The results of the research demonstrated a significant rise of survival rates, improvement or stabilization of the neurocognitive function and also a decrease

Submitted: January 10, 2014.

*Correspondence: E-mail: tzerkovsky@mail.ru

Abbreviations used: AAT – antiangiogenic therapy; MST – mean survival time; PDT – photodynamic therapy; PS – photosensitizer; VEGF – vascular endothelial growth factor.

in steroid doses in malignant brain tumors treatment using AAT [20, 21]. However, the interest in AAT employment has been recently declining due to the absence of the expected improvement of long-term outcomes and high cost of the targeted drugs [22, 23].

Thus the issue of the search for new approaches to the management of malignant glial tumors of the brain is left open. A very promising approach is the combination of two and more treatments modalities for this disease. There are a few reports supporting the feasibility of efficient and safe use of PDT with porphyrin PS and AAT with monoclonal antibodies [24]. These studies are purely experimental ones needing further investigation and development.

The objective of this study is to investigate chlorin e6 conjugated with polyvinyl pyrrolidone photosensitizer (Ce6CPPPS) pharmacokinetics in healthy and tumor tissues of rat brain and to evaluate the antitumor efficacy of the treatment modality including PDT with Ce6CPPPS and AAT with bevacizumab in an *in vivo* experimental model.

MATERIALS AND METHODS

The study was conducted on 50 white rats (160 ± 20 g) bred in the vivarium of N.N. Alexandrov National Cancer Center of Belarus. Animal experiments were performed according to the Rules of Ethic Committee.

The experimental research on Ce6CPPPS pharmacokinetics in healthy and tumor tissues of rat brain was carried out on 10 laboratory animals.

The experimental research *in vivo* on the antitumor efficacy of the proposed treatment modality was done on 40 laboratory animals distributed to 4 groups, 10 rats in each: group 1 — intact control, group 2 — PDT, group 3 — AAT and group 4 — combination therapy.

The tumor strain. The research was done on the experimental tumor strain of C6 glioma. The tumor cell culture was obtained from the National Center of Epidemiology and Microbiology (Minsk, Republic of Belarus).

Subcutaneous experimental tumor model. To evaluate tumor sensitivity to the above-mentioned modalities, subcutaneous tumor implantation was made into the left inguinal region by injection 0.5 ml of 20% tumor suspension in 0.6% Hanks' solution. The treatments were administered 11–13 days after C6 glioma implantation, with tumor diameter reaching 1.5–2.0 cm.

The orthotopic model of experimental tumor. To create the orthotopic model of experimental tumor, intracranial implantation of C6 glioma was made. A trephine opening was drilled with a bur 1.5 mm in diameter in the rats skull, 3.0 mm off the sagittal suture in the in the left parietal region, after the animal having been introduced into the state of neuroleptanalgesia (0.1% phentanyl + 0.025% droperidol). Tumor cells in 25 μ l of DMEM medium, $500 \cdot 10^6$ cells in number, were implanted in the projection of the left lateral ventricle with a syringe having a restrictor at the end of the needle [25].

PS. A single injection of the PS Photolon (RUE "Belmedpreparaty", Minsk, Republic of Belarus) was made at a dose of 2.5 mg/kg into the animal's caudal vein.

Fluorescent diagnostics. The PS accumulation level was measured with spectral fluorescence technique using LESA-01-Biospek spectrum analyser (Russian Federation, Moscow; $\lambda = 632.8$ nm).

AAT. A single intravenous injection of Avastin® (bevacizumab, F. Hoffmann-La Roche Ltd.) for AAT was made at a dose of 10 mg/kg.

PDT. The PDT treatment was carried out 0.5 h after Ce6CPPPS administration. Photoirradiation of intracranial C6 glioma with a light exposure dose of 50 J/cm² was performed through the trephine opening on day 17 after tumor cell inoculation, with clinical signs of tumor growth being apparent. The semiconductor laser unit "IMAF-Axicon" (Minsk, Republic of Belarus; $\lambda = 661$ nm) was used as a radiation source.

The same light energy exposure dose was used for subcutaneously implanted tumors. The PDT treatment was conducted 2.5 h after Ce6CPPPS injection [26].

Criteria for antitumor efficacy evaluation. The efficacy of the therapy was evaluated by C6 glioma pathomorphism, by the data on mean survival time (MST), median survival and by induced necrosis areas in the tumor, using the technique of intravital staining of the bloodstream channel with 0.6% Evans blue solution.

Statistical processing of the results. Statistical processing of survival outcomes was done with the Kaplan — Meier method using log-rank test (statistical software package Statistica 8.0). To evaluate necrosis areas in tumor tissue, a special ImageJ program (NIH, Bethesda, USA) was applied. Statistical significance of differences was relevant at $p < 0.05$.

RESULTS AND DISCUSSION

At the first stage of the research, to evaluate the time of PDT administration after PS injection, the dynamics of its accumulation was investigated in healthy and tumor tissues of the brain on days 15–19 after tumor cell implantation. The Ce6CPPPS accumulation level was measured 0, 1, 3, 6 and 24 h after PS injection. The results are presented in Fig. 1.

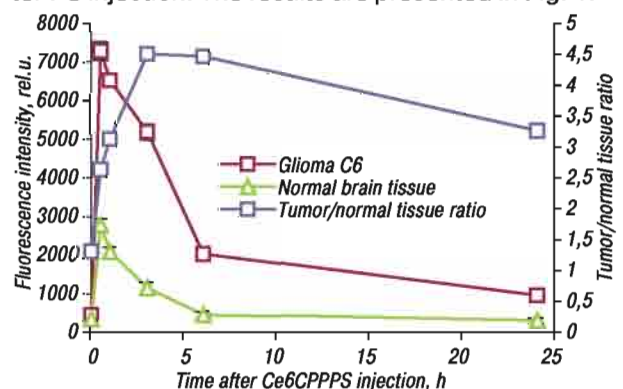


Fig. 1. The dynamics of Ce6CPPPS fluorescence intensity in healthy brain tissue and in C6 glioma after its 2.5 mg/kg injection

Our experimental findings pertaining to Ce6CPPPS PS accumulation in healthy brain tissues and C6 glioma obtained using the technique of laser-induced fluorescence spectroscopy *in vivo*, validate high tropism of this agent to C6 glioma tissues in laboratory animals.

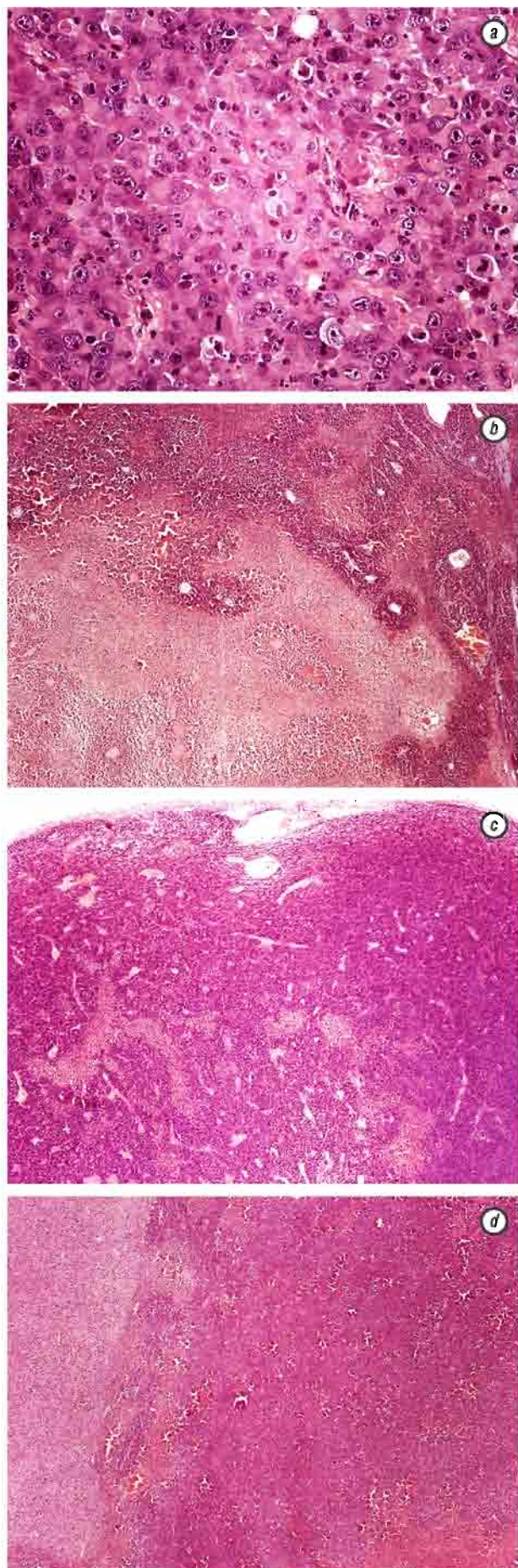


Fig. 2. C6 glioma. The state after AAT (a, c), combination therapy (b) and PDT (d)

Based on the data on Ce6CPPPS accumulation dynamics, C6 glioma photoirradiation was performed with the maximal value of PS fluorescence signal in tumor tissue. Ce6CPPPS and bevacizumab were injected in groups 2 and 3, in the combination therapy group bevacizumab was administrated 24 h after PDT, laser photoirradiation of the tumor being carried out at a light exposure dose of 50 J/cm^2 0.5 h after PS injection (group 4). Tumor pathomorphism was evaluated 72 h after PDT (group 2) and AAT (group 3), and 48 h after bevacizumab administration in combination therapy group (group 4).

A PDT treatment resulted in local necrotic changes in the exposure area without thermodestruction of tumor and brain tissue. In addition to considerable necrosis areas, hemorrhage foci were noted, mainly in the central parts of the lesion. Hemorrhages and insignificant edema in the tissue surrounding the tumor growth region were observed in the normal parenchyma encircling the tumor. The combination therapy produced a synergetic effect manifested in a proportional extension of necrosis areas in tumor tissue. The results obtained are presented in Fig. 2.

Our study investigated sensitivity of C6 glioma subcutaneously implanted into the rat's right inguinal area. According to our findings, all the animals subjected to combination therapy presented with necrotic changes of maximal size 72 h after the treatment. In the control group, this index showing the emergence of spontaneous central necrosis was insignificant. The results obtained are presented in Fig. 2–4 and the Table.

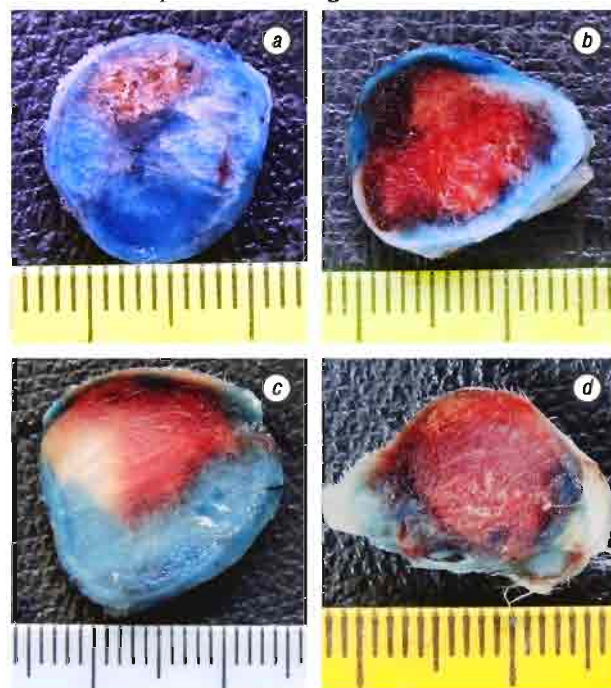


Fig. 3. Histotopographic sections of C6 glioma in the control group (a), after AAT (10 mg/kg bevacizumab) (b), after PDT with Ce6CPPPS (2.5 mg/kg, 50 J/cm^2) (c) and after combination therapy (PDT with Ce6CPPPS (2.5 mg/kg, 50 J/cm^2) + AAT (10 mg/kg bevacizumab) (d)

In conclusion, the study of distinctions of Ce6CPPPS pharmacokinetics in healthy and tumor tissues of rat brain validated the fact of high tropism

of this PS to C6 rat glioma. The spectral fluorescent diagnostic technique determined the optimal time of PDT treatments for intracranial tumor. PS concentration was demonstrated to reach its maximal value 0.5 h after Ce6CPPPS injection into tumor tissues.

Table. MST and median survival rates and tumor tissue necrosis indices in the control and study groups

Group	MST, days	Median, days	p	Necrosis area, %	p
Intact control	15.4 ± 1.95	16	–	10 ± 2.55	–
AAT*	27.1 ± 2.74	27	0.02	57.83 ± 6.53	0.003
PDT*	29.2 ± 3.5	29	0.02	54.87 ± 6.95	0.003
Combination therapy	38.4 ± 4.39	40	0.01	89.43 ± 5.57	0.001

Note: * $p = 0.31$ (AAT vs PDT)

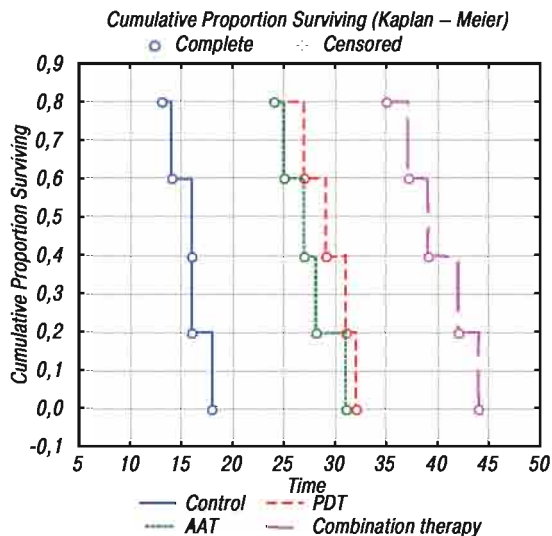


Fig. 4. Survival curves of animals with C6 glioma regarding treatment modality

Antitumor efficacy of malignant brain tumors treatment modalities was evaluated in an experiment on animals. The Table presents necrosis areas on histotopographic sections of subcutaneously transplanted glioma C6 after AAT 10 mg/kg bevacizumab), PDT with Ce6CPPPS at the light dose 50 J/cm² and combination therapy (PDT with Ce6CPPPS at the light dose 50 J/cm²) + AAT (10 mg/kg bevacizumab) being performed 2.5 h after PS administration at a dose of 2.5 mg/kg. The percentage of tumor necrosis areas was 57.83 ± 6.53%, 54.87 ± 6.95% and 89.43 ± 5.57%, respectively ($p = 0.001$). Also showed a significant increase in MST and median survival rates of laboratory animals with intracranial C6 glioma in the combination therapy group compared with each of its components individually (38.4 ± 4.39; 40 days vs 27.1 ± 2.74; 27 days and 29.2 ± 3.5; 29 days; $p = 0.01$). Our data on MST, median survival of the animals and pathomorphological changes in tumor tissue demonstrated that PDT with Ce6CPPPS and AAT with bevacizumab improved treatment outcomes in animals with experimental brain tumors.

The studies in this field are at the stage of experimental substantiation. This paper is the first report about feasibility of efficient use of PDT with a PS of chlorine series and AAT with bevacizumab for the treatment of brain tumors in experimental models. Our findings demonstrate that the tumor

strain, implanted either subcutaneously or intracranially, is sensible to the proposed treatment regimen. However, E. Lindsay et al. reported that intracranial rat gliomas are less sensible to PDT with m-THPP (porphyrin derivate) than subcutaneously implanted ones. The authors attribute this fact to hematoencephalic barrier impeding the penetration of sufficient PS amount to the tumor tissue, needed to achieve the curative effect, and also to the peculiarities of tumor blood supply [27].

The findings of our experimental study corroborate high tropism of Ce6CPPPS to C6 rat glioma which is associated with the possibility of penetrating through hematoencephalic barrier, and sizable increase in antitumor efficacy of PDT in its combination with AAT.

ACKNOWLEDGEMENT

This study was financially supported by the Belarusian National Foundation for Basic Research (Grant № B10M-025).

REFERENCES

1. Sukonko OG, Sachek MG. Malignant tumors in Belarus 2001–2010. Minsk: RNPC MT, 2011. 220 p. (in Russian).
2. Uzuka T, Aoki T, Natsumeda M, et al. Effectiveness of maximal safe resection for glioblastoma including elderly and low Karnovsky performance status patients: retrospective review at a single institute. *Neurol Med Chir (Tokyo)* 2012; 52: 570–6.
3. Chissov V, Filonenko E, Reshetov I, et al. Intraoperative fluorescence diagnostic and photodynamic therapy of patients with metastatic brain tumors. *Rus J Oncol* 2011; 2: 4–7 (in Russian).
4. Noël G. Stereotactic radiotherapy of intracranial benign tumors. *Cancer Radiother* 2012; 16: 410–7.
5. Takahashi H. Radiofrequency interstitial hyperthermia of malignant brain tumors: development of heating system. *Exp Oncol* 2000; 22: 186–90.
6. Yang F, Teng M, Lu M, et al. Treating glioblastoma multiforme with selective high-dose liposomal doxorubicin chemotherapy induced by repeated focused ultrasound. *Int J Nanomedicine* 2012; 7: 965–74.
7. Casas A, Di Venosa G, Hasan T, et al. Mechanisms of resistance to photodynamic therapy. *Curr Med Chem* 2011; 18: 2486–515.
8. Weiss A, den Bergh H, Griffioen A, et al. Angiogenesis inhibition for the improvement of photodynamic therapy: The revival of a promising idea. *Biochim Biophys Acta* 2012; 1826: 53–70.
9. Zelenkov P, Baumgartner R, Bise K, et al. Acute morphological sequelae of photodynamic therapy with 5-aminolevulinic acid in the C6 spheroid model. *J Neurooncol* 2007; 82: 49–60.
10. Flores-Ancona R, Garcia-Gomez F, Jimenez-Betanzos A, et al. Effects of sodium butyrate on cell death induced by photodynamic therapy in U373-MG and D54-MG astrocytoma cell lines. *Photochem Photobiol* 2009; 85: 1182–8.
11. Tirapelli L, Morgueti M, da Cunha Tirapelli D, et al. Apoptosis in glioma cells treated with PDT. *Photomed Laser Surg* 2011; 29: 305–9.
12. Zhang X, Jiang F, Kalkanis S, et al. Combination of surgical resection and photodynamic therapy of 9L gliosarcoma in the nude rat. *Photochem Photobiol* 2006; 82: 1704–11.

13. **Hong X, Qiong L, Ming C, et al.** 5-Amino-4-oxopentanoic acid photodynamic diagnosis guided microsurgery and photodynamic therapy on VX2 brain tumour implanted in a rabbit model. *Chin Med J* 2009; **122**: 1316–21.
14. **Aziz F, Telara S, Moseley H, et al.** Photodynamic therapy adjuvant to surgery in metastatic carcinoma in brain. *Photodiagnosis Photodyn Ther* 2009; **6**: 227–30.
15. **Akimoto J, Haraoka J, Aizawa K, et al.** Preliminary clinical report on safety and efficacy of photodynamic therapy using talaporfin sodium for malignant gliomas. *Photodiagnosis Photodyn Ther* 2012; **9**: 91–9.
16. **Smolin A, Kobiakov G, Konev A.** Opportunities of antiangiogenic therapy for recurrent high-grade gliomas. *Pharmateca (Oncology)* 2009; **18**: 41–8 (in Russian).
17. **Stark-Vance V.** Bevacizumab (Avastin) and CPT-1 (Camptosar) in the treatment of relapsed malignant glioma. *Neurooncol* 2005; **7**: Abstract 342.
18. **de Groot J, Yung W.** Bevacizumab and irinotecan in the treatment of recurrent malignant gliomas. *Cancer J* 2008; **14**: 279–85.
19. **Pechman K, Donohoe D, Bedekar D, et al.** Evaluation of combined bevacizumab plus irinotecan therapy in brain tumors using magnetic resonance imaging measures of relative cerebral blood volume. *Magn Reson Med* 2012; **68**: 1266–72.
20. **Jiang F, Zhang H, Kalkanis S, et al.** Combination Therapy with Antiangiogenic Treatment and Photodynamic Therapy for the Nude Mouse Bearing U87 Glioblastoma. *Photochem Photobiol* 2008; **84**: 128–37.
21. **Gil-Gil M, Mesia C, Rey M, et al.** Bevacizumab for the treatment of glioblastoma. *Clin Med Insights Oncol* 2013; **7**: 123–35.
22. **Chinot O.** Bevacizumab-based therapy in relapsed glioblastoma: rationale and clinical experience to date. *Expert Rev Anticancer Ther* 2012; **12**: 1413–27.
23. **Zhang G, Huang S, Wang Z.** A meta-analysis of bevacizumab alone and in combination with irinotecan in the treatment of patients with recurrent glioblastoma multiforme. *Clin Neurosci* 2012; **19**: 1636–40.
24. **Zhan Q, Wu Y, Hu S.** The inhibitory effect of photodynamic therapy and of an anti-VCAM-1 monoclonal antibody on the *in vivo* growth of C6 glioma xenografts. *Braz J Med Biol Res* 2011; **44**: 489–96.
25. **Smirnova Z, Kubasova I, Borisova L, et al.** Photodynamic therapy malignant rats brain tumors with Photosence. *Rus J Biother* 2005; **3**: 54–9 (in Russian).
26. **Tserkovsky D, Alexandrova E, Chalau V, et al.** Effects of combined sonodynamic and photodynamic therapies with photolon on a glioma C6 tumor model. *Exp Oncol* 2012; **34**: 332–5.
27. **Lindsay E, Berenbaum M, Bonnett R, et al.** Photodynamic therapy of a mouse glioma: intracranial tumours are resistant while subcutaneous tumours are sensitive. *Br J Cancer* 1991; **63**: 242–6.