

V.V. Ilina, M.D. Chemych, N.I. Ilina, V. Kusi

CLINICAL AND EPIDEMIOLOGICAL FEATURES OF INFECTIOUS MONONUCLEOSIS IN THE NORTH-EASTERN REGION OF UKRAINE

Sumy State University

The aim of the study – to learn and research clinic-epidemiological features of infectious mononucleosis in the North-Eastern region of Ukraine.

Materials and methods. There were 122 patients with infectious mononucleosis, who were hospitalized in 2012–2014 in the Sumy regional infectious clinical hospital named after Z.Y. Krasovytskyi. The diagnosis «infectious mononucleosis» was made on the grounds of epidemiological and clinical data, results of additional laboratory and instrumental examination techniques according to the common criteria clinical practice.

Results. The incidence of infectious mononucleosis in the North-Eastern region of Ukraine is high and has increasing tendency. Infectious mononucleosis more often affects children and young people. In epidemiological anamnesis shows a long-term contact with the similar infectious patients in vast majority of patients. Clinic of infectious mononucleosis is characterized by the extensive polymorphism. The most characteristic features of infectious mononucleosis is generalized lymphadenopathy, tonsillitis, hepatolienal syndrome. Diagnostic criterion for infectious mononucleosis among the indicators of total blood values are leukocytosis due to lymphocytosis and monocytosis, reduction of level segmented neutrophils, slight increase of maintenance banded neutrophils, erythrocyte sedimentation rate (ESR) and also presence of atypical mononuclear cells. Desintoxication therapy is widely used for treatment of patients with an infectious mononucleosis as the toxication takes place. Combination of antiviral group ANA with immunomodulating drugs is considered perspective therapy of patients with infectious mononucleosis, that considerably increases the efficiency of antivirals. Prescription of antibiotics for infectious mononucleosis is necessary in cases when there are indications (secondary bacterial infection, about indicators of inflammatory changes during 5 and even more in blood analysis with lacunar tonsillitis or necrotic tonsillitis).

Conclusions. The incidence for infectious mononucleosis in the North-Eastern region of Ukraine is high and has

increasing tendency and often affects children and young people.

Key words: infectious mononucleosis; Epstein-Barr virus; clinic-epidemiological features.

The problem of infectious mononucleosis (IM) caused by γ -herpesvirus 4 types has become more and more important nowadays. Firstly, it is connected with high spread of Epstein-Barr virus (EBV) among the world's population, which reaches 80–100 % polyetiologic disease, ease of infection, polymorphism of clinical manifestations, frequent development of complications, high infant mortality (up to 15.8 %), lack of means of specific prevention and etiotropic therapy, long-term ability of the virus to persist in the body, a tendency to recurrent and chronic disease [1, 2].

IM is traditionally considered as childhood diseases. However, recently many cases of IM are registered in adults. There are diagnosed 2.8-3.5 mln cases of IM every year in the world, 1/3 of them are in adults. Index of incidence of IM generally in Ukraine ranges from 12-14 to 100 thousand population during 2012-2014 years [3, 4].

After primary infection the virus stays in the body of immunocompetent individuals in a latent form and is located in the epithelial cells of the mucous membrane of the oropharynx, the system B-lymphocytes in the form of numerous episoms that are located in the nucleus, at the same time not integrating with cellular genome. Episoms replication occurs only as a result of cells division and daughter cells also contain the virus. Activation of Epstein-Barr virus infection is a marker of immunosuppression and it is always evident as affection of the blood and lymphatic system [1, 4–8].

IM belongs to groups of «new» infectious diseases of XXI century. At the present stage, studying of etiologic factors, new pathogenetic mechanisms, clinical manifestations, diagnostic features and treatment issues doesn't lose its relevance. In the recent years, a significant increase of IM morbidity is registered in Ukraine. Previously, progress of IM was associated with EBV, now the role of other causative

agents, predominantly, sets of herpesviruses, is proved [9, 10]. One important problem of an action-oriented health protection is an inadequate efficiency of common laboratory techniques of etiological diagnostics, ambiguous interpretation of findings, which does not allow making the exclusion of IM. As of today, it is assigned that disease is associated with set of cancer, predominantly lymphoproliferative disorders and autoimmune diseases. The relevance of the problem and need for diagnostics of IM are also connected with frequent formation of auxiliary immune deficiency in survivors [11].

By studying the clinical and epidemiological features of infectious mononucleosis in Sumy, recommendations for its early diagnosis and prevention among the general population.

Materials and methods

There were 122 IM patients under supervision, who were hospitalized in 2012–2014 in the Sumy Regional Infectious Diseases Hospital named after Z. Y. Krasovytskyi. The age of patients ranged from 18 to 79 years, among them were 66 females and 56 males.

The procedure of examination corresponds to the standards of the Ethical Committee.

The inclusion of patients into the examination was carried out according to the following criterion:

- presence of typical clinic implications;
- complex clinic laboratory examination.

The results of clinical and laboratory examination of 122 IM cases, which were randomized by gender and age, were analyzed. Diagnosis of "infectious mononucleosis" was made on the grounds of epidemiological and clinical evidence, results of extra laboratory and instrumental examination techniques according to the common criterion of clinical practice.

Etiological decoding was carried out by detection of antibodies to EBV by method of enzyme-linked immunosorbent

assay (ELISA) and finding DNA of this virus in the blood serum by method of polymerase chain reaction (PCR). To exempt viral hepatitis, the part of patients underwent the identification of anti-HAV IgM, HBsAg and anti-HCV IgG. The presence of cytolysis syndrome was diagnosed on the grounds of activity of alanine aminotransferase (ALAT), and mesenchymal inflammatory syndrome on the grounds of thymol turbidity test.

Besides physical examination, all the cases were run by laboratory examinations. The parameters of peripheral blood such as concentration of hemoglobin, red blood cells, platelets, white blood cells, ratio of different types of white blood cells in the leukogram, ESR (Cobas Micros) were determined. Expected integrative hematological indicators (Leukocytal index (LI), leucocyte intoxication index (LII), Leukocytal intoxication index 2 (LII 2), index of leukocytes shift (ISL), lymphocytic-granulocytic index (ILG), Index of lymphocyte ratio and CM (ILCM), the general index (GI), neutrophil-lymphocyte ratio (NLR), the index of neutrophils and monocytes ratio (INM).

Results and discussion

According to supervision, 122 patients with infectious mononucleosis were treated in 2012–2014 in Sumy Regional Infectious Diseases Hospital named after Z. Y. Krasovytskyi. The distribution by gender: women – 66 (54.1%) men – 56 (45.9%). After analyzing, it can be concluded that significant differences in the distribution of the incidence of IM based on gender is not observed.

The average age of patients was (23.94±1.08) years (from 18 to 79 years). The students dominated (59%). Analyzing the age structure of patients it was detected that 85 patients were hospitalized between the ages of 18 and 39 (69.7%), 33 patients (27.0%) – from 40 to 60 years, and 4 patients (3.3%) – aged 60 (Fig. 1).

Among hospitalized patients urban population prevailed. It is about 75,4% (92 persons), while the rural population occupied only 24,6% (30 people).

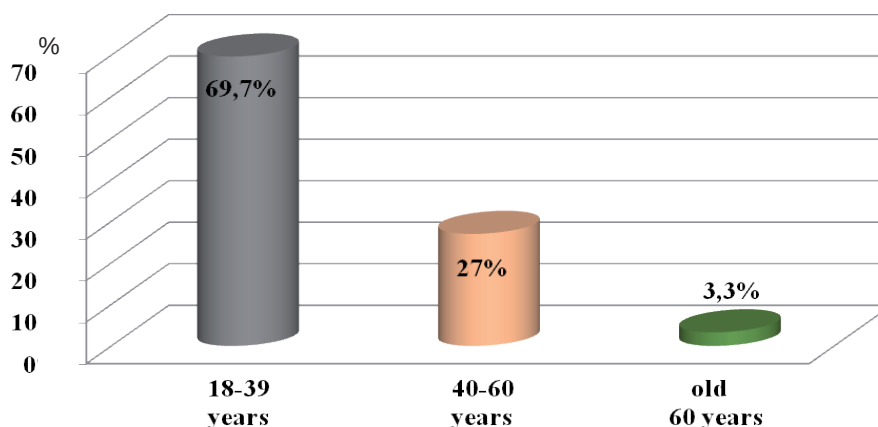


Fig. 1. Distribution of patient for IM by age.

Thus urban population suffers IM more often.

The vast majority of IM patients was an indication of contact with such infectious patients – in 103 of all the 122 patients, as a percentage of 84.4 %, while concerning the last 19 patients (15.6 % as a percentage according to comparison with the previous data less than 5 times), there was not such data.

After analyzing the data presented in the chart, it can be concluded that the epidemiological anamnesis of the vast majority of patients have an indication of prolonged contact with such infectious patients.

The disease often had intermedius severity in 90 (73.8 %) of IM patients. It was light course in 30 patients (24.6 %), and severe course was observed in only 2 patients (1.6 %).

Chills was found in 13 patients (11.0 %), sweating – in 23 patients (19 %), muscle pain – in 23 patients (19 %), pain in the joints – in 33 patients (27 %). Often weakness was observed in 93 patients (76 %), headache in 57 patients (47 %), loss of appetite in 45 patients (37 %). 73 patients (60 %) from the first days of illness complained of sore throat, 32 patients (26 %) – to nasal congestion. There were cases of severe right hypochondrium, and it was inherent among 76 patients (62.3 %) (Tabl. 1).

Table 1

The frequency of the main complaints of IM patients

The main complaints of patients	The detection rate	
	n=122	%
Chills	13	10.7
Sweating	23	18.9
Muscle pain	23	19.0
Joint pain	33	27.0
General weakness	93	76.2
Headache	57	47.0
Loss of appetite	45	37.0
Sore throat	73	60.0
Nasal congestion	32	26.0
Heaviness in the right hypochondrium	76	62.3

Having analyzed the data presented in the table it is possible to draw a conclusion that the main complaints of patients for IM are (cold fit, hidrosis, myoneuralgia, arthralgia, general weakness, headache, loss of appetite), pharyngalgia when swallowing, stuffiness in nose, heaviness in the right hypochondrium.

Fever was the most constant manifestation (it was observed in 113 patients, that in a percentage ratio makes 93 %). The temperature of body was rising from subfebrile

to pyretic, more often were constant (80 patients, 65.6 %), remittent (31 patients, 25.4 %) or hectic (2 patients, 1.6 %) for the character. Normal body temperature remained in 9 of 122 patients that in a percentage ratio makes only 7 %. In 41 patients (34 %) duration of fever made up to 1 week, in 49 patients (40 %) – up to 2 weeks, in other 23 patients (19 %) – more than 3 weeks.

Conspicuous findings on tonsils were observed in majority of patients (94.3 %) and appeared from the 3-6th day. There was hyperemia and «granulosity» of back of the throat. Generalized lymphadenopathy was one of the leading syndromes for infectious mononucleosis. Post and anterior cervical and angular gnathic lymph glands enlarged more often. It size was 2.5 cm, they were moderate density, floating, not soldered with subiculum, slightly morbid (painful). Besides, hepatomegalia and splenomegaly, there was moderate. Jaundice of sclera and skin integument were detected. All of them were referred to a hospital with provisional diagnosis of an acute viral hepatitis. The jaundice was low-grade or moderate and short-term (5-8 days). Hepatitis Viral Marker A, B, C were not detected in these patients. In 20 patients (16 %) typhoid maculopapular rash, maculopapular rash occurred, it was hemorrhagic rash in 3 cases, maintained from 6 to 8 days, ill-defined sloughing of skin occurred in 2 patients (Tabl. 2).

Table 2

Frequency of detection of the main objective data in patients with IT

Objective status	Frequency of	
	absolute count	manifestation, %
Tonsillitis	115	94.3
Hyperemia and «granulosity» of back of throat	93	76.2
Generalized lymphadenopathy	89	72.5
Banti's syndrome	74	60.7
Furred tongue	82	67.2
Heaviness in the right hypochondrium	69	56.6
Ochrodermia	6	4.9
Rash	20	16.0

Characteristic changes in clinical blood analysis were leukocytosis ($12.90 \pm 3.20 \times 10^9/l$), lymphocytosis (the indicator averaged $(57.23 \pm 2.57) \%$) and monocytosis (the indicator averaged $(12.3 \pm 0.40) \%$), nadir of segmented neutrophils ($(32.96 \pm 2.32) \%$), slight increase of maintenance of stab neutrophils ($(7.62 \pm 0.64) \%$), acceleration of ESR (17.0 ± 1.0) mm/h. Atypical mononuclearalls occurred

Table 4

Integrated hematological indexes of IM cases

Integrated hematological indexes	Healthy	IM cases
LI	0.52±0.04	2.84±0.46*
LII	0.98±0.16	0.53±0.10*
LII2	1.60±0.50	0.73±0.09*
LSI	1.99±0.15	0.76±0.03*
LESRI	1.87±0.76	0.65±0.08
ILG	4.56±0.37	21.88±2.74*
GI	6.13±0.47	22.53±2.75*
NLI	2.47±0.21	0.86±0.12*
NMI	11.83±1.3	9.92±0.85

Note. * – Significant difference in performance compared to the norm ($p < 0.05$).

in 55 % of patients and averaged (18.8 ± 1.8) %. Average values of other indicators of haemogram didn't differ from normal range (Tabl. 3) [12].

Table 3

Blood values of patients with IM

Blood value	Normal range	Mean value of blood values of patients
Leucocytes, $\times 10^9/l$	6.50±2.50	12.90±3.20
Band, %	3.50±2.50	7.62±0.64
Segmented neutrophils, %	59.50±12.50	32.96±2.32*
Eosinophils, %	2.75±0.25	1.0±0.40
Basophils, %	1.0±0.02	0
Lymphocytes, %	28.0±9.0	57.23±2.57*
Monocytes, %	7.0±1.4	12.30±0.40
Atypical mononuclears, %	0	18.80±1.80*
Platelets, $\times 10^9/l$	270.0±6.7	207.0±5.40
Erythrocytes, $\times 10^{12}/l$	4.50±0.50	4.50±0.55
Hemoglobin, g/l	130.0±4.5	132.0±2.20
ESR, mm/h	8.0±1.5	17.0±1.0*

Note. * – Significant difference in performance compared to the norm ($p < 0.05$).

Therefore, leukocytosis by means of lymphocytosis and monocytosis, decrease of segmented neutrophils, slight increase of stab neutrophils level, ESR acceleration were detected, and also presence of atypical mononuclear cells is diagnostic criterion of infectious mononucleosis [13, 14].

Usage of integrated hematologic indexes (IHI) allows to estimate the condition of different segments of immune system, to identify types of adaptive organism response, disease severity, its state and prognosis without using of specific examination techniques (Tabl. 4).

It was established that, in comparison with healthy individual, positive increase of LI, LGI, GI, positive decrease of LII, NLI, LSI were observed, LII2, NMI, LESRI, that denotes the presence of endogenous toxicosis, which is caused by infectious process and abnormality of immunological reactivity.

In this way, IHI examination showed that unspecific immunological reactivity of IM cases is different from one of healthy individuals.

The specific diagnostics suggests the carrying out of ELISA. Among inspected cases, 68 individuals (55.3 %) have IM caused by EBV, 16 (12.8 %) – CMV, markers of both viruses. All the cases were HVI-negative. Anti-HAV, IgM, HBsAg and anti-HCV IgG were not detected in any case (fig. 2) [15].

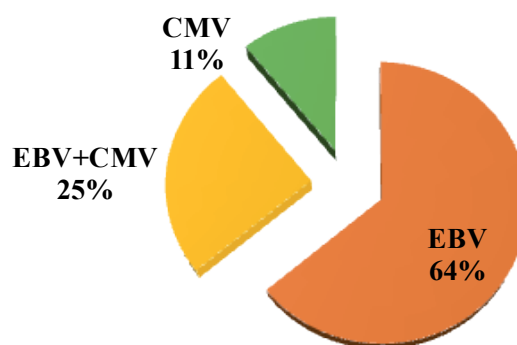


Fig. 2. Distribution of IM cases according to ELISA results.

Having analyzed the data shown on the diagram, one can conclude, that IM is not caused only by EBV, but other herpes viruses, especially CMV and also it is often concurrent infection EBV+CMV.

Conclusions

Conducted studies suggest the following conclusions according clinical and epidemiological features of infectious mononucleosis in the North-Eastern region of Ukraine.

1. The incidence of infectious mononucleosis in the North-Eastern region of Ukraine is high and has increasing tendency.

2. Infectious mononucleosis more often affects children and young people.

3. In epidemiological anamnesis shows a long-term contact with the similar infectious patients in vast majority of patients.

4. Clinic of infectious mononucleosis is characterized by the extensive polymorphism. The most characteristic features of infectious mononucleosis is generalized lymphadenopathy, tonsillitis, hepatolienal syndrome.

5. Diagnostic criterion for infectious mononucleosis among the indicators of total blood values are leukocytosis due to lymphocytosis and monocytosis, reduction of level segmented neutrophils, slight increase of maintenance banded neutrophils, erythrocyte sedimentation rate (ESR), and also presence of atypical mononuclear cells.

6. Disintoxication therapy is widely used for treatment of patients with an infectious mononucleosis as the toxication takes place. Combination of antiviral group ANA

with immunomodulating drugs is considered perspective therapy of patients with infectious mononucleosis. That considerably increases efficiency of antivirals. Prescription of antibiotics for infectious mononucleosis is necessary in cases when there are indications (secondary bacterial infection, about indicators of inflammatory changes during 5 and even more in blood analysis with lacunar tonsillitis or necrotic tonsillitis).

References

1. Razgulyayeva, A.V., Ukhanova, O.P., & Bezrodnova, S. M. (2012). Sovremennyye predstavleniya ob etiologii i patogeneze infektsionnogo mononukleozu [Modern presentation of about etiology and pathogenesis of infectious mononucleosis]. *Nauka i sovremennost [Science and Modernity]*, 2, 62-67 [in Russian].
2. Sharipova, Ye.V., & Babachenko, I.V. (2013). Gerpes-virusnyye infektsii i infektsionnyy mononukleoz (obzor literatury) [Herpes-viral infections and infectious mononucleosis (literature review)]. *Zhurnal infektologii [Journal of Infectiology]*, 2, 40-44 [in Russian].
3. Oludare, A., Kristin, A., Hogquist, H. H., Balfour, Jr. (2011). Progress and problems in understanding and managing primary Epstein-Barr virus infection. *Clin. Microb. Rev.*, 1, 193-209.
4. Bravender, T. (2010). Epstein-Barr-virus, cytomegalovirus and infectious mononucleosis. *Adolesc. Med. State Art Rev.*, 2, 251-264.
5. Varfolomeieva, Yu.V., Partoieva, O.H., Triukhanova, T.I., Tereshchenko, V.V. (2014). Dodatkoviy metod dyferentsiinoi diahnostyky infektsiinoho mononukleozu ta hostroho tonzylofaryngitu na osnovi hematolohichnykh danykh [An additional method of differential diagnosis of infectious mononucleosis and acute tonsilopharyngitis based on hematologic data]. *Infektsiini khvoroby [Infectious Diseases]*, 2, 27-32 [in Ukrainian].
6. Dubinskaya, G.M., Koval, T.I., Bodnar, V.A., Litvinenko, Yu.V., Izyumskaya Ye.M., Kotelevskaya, T.M., ... Sizova, L.M. (2012). Podkhody k diagnostike khronicheskikh form Epshteyna-Barr virusnoy infektsii u vzroslykh na osnovi kompleksnoy otsenki kliniko-immunologicheskikh pokazateley [Approaches to the diagnosis of chronic forms of Epstein-Barr virus infection in adults on the basis of a comprehensive assessment of clinical and immunological indicators]. *Klinicheskaya infektologiya i parazitologiya [Clinical Infectiology and Parazitology]*, 3-4, 55-67 [in Russian].
7. Zhurakovska, N. O. (2015). Patohenetychne znachennia porushen u systemi POL/AOS, trombotsytarnii lantsi hemostazu pry infektsionomu mononukleozu ta yikh korektsiia [Pathogenetic significance of violations in the system of LP / AOS, thrombocyte linkage of hemostasis in infectious mononucleosis and their correction]. *Extended abstract of Candidate's thesis* [in Ukrainian].
8. Kramarev, S.A. (2011). Infektsionnyy mononukleoz u detey: voprosy patogeneza i lecheniya [Infectious mononucleosis in children: issues of pathogenesis and treatment]. *Zdorovia Ukrainy [Health of Ukraine]*, 4, 57-59 [in Russian].
9. Pokrovska, T.V. (2014). Khronichna Epshteyna-Barr virusna infektsiia – aktualni pytannia [Chronic Epstein-Barr viral infection – current issues]. *Infektsiini khvoroby [Infectious Diseases]*, 2, 70-74 [in Ukrainian].
10. Pokrovska, T.V., Zinchuk, O.M., & Potyomkina, H.O. (2011). Fenotypichna kharakterystyka limfotsytiv u khvorykh na hostru ta khronichnu EBV-infektsiiu [Phenotypic characteristics of lymphocytes in patients with acute and chronic EBV-infection]. *Visnyk morfolohii [Journal of Morphology]*, 3, 624-628 [in Ukrainian].
11. Bobrovytska, A.I., Yatsenko, I.V., Shvetsova, N.V., & Orlenko, V.V. (2013). Osoblyvosti dyferentsiinoi diahnostyky infektsiinoho mononukleozu ta optymizatsiia terapii [Features of differential diagnosis of infectious mononucleosis and optimization of therapy]. *Infektsiini khvoroby [Infectious Diseases]*, 1, 20-24 [in Ukrainian].
12. Kazmirchuk, V.Ye., & Maltsev, D.V. (2011). Diagnostika i lecheniye infektsii, vyzvannoy Epshteyna-Barr virusom [Diagnosis and treatment of infection caused by Epstein-Barr virus]. *Klinichna imunologiya. Alergologiya. Infektologiya [Clinical Immunology. Allergology. Infectiology]*, 4, 69-75 [in Ukrainian].
13. Kish, P.P., Koval, H.M., Petrov, V.O. Rusyn, Ye.I., Turianytsia, S.M., Kohutykh, A.I., ... Maroshan, M.T. (2013). Kliniko-laboratorni osoblyvosti perebihu infektsiinoho mononukleozu u doroslykh [Clinical and laboratory features of the course of infectious mononucleosis in adults]. *Naukovyi visnyk Uzhhorodskoho universytetu [Scientific Journal of Uzhhorod University]*, 47, 139-144 [in Ukrainian].
14. Kozko, V.M., Mohylenets, O.I., Merkulova, N.F., Solomennyk, H.O., Bondarenko, A.V., Yurko, K.V., ... Nikitina, V.V. (2013). Kliniko-laboratorni pokaznyky u khvorykh na infektsiinyi mononukleoz riznoi etiologii [Clinical and laboratory parameters in patients with infectious mononucleosis of different etiology]. *Infektsiini khvoroby [Infectious Diseases]*, 1, 17-20 [in Ukrainian].
15. Tierioshyn, V.O., Yuhan, Ya.L. (2014). Suchasni aspekty patohenezu ta likuvannia infektsiinoho mononukleozu [Modern aspects of pathogenesis and treatment of infectious mononucleosis]. *Infektsiini khvoroby [Infectious Diseases]*, 2, 5-13 [in Ukrainian].
16. Nishikava, J., Miyazaki, T., Fujinami, H., Miyazono, T., Murakami, J., Sugiyama, T. (2011). Infectious mononucleosis with atypical manifestations accompanied by transient IgM antibody response for cytomegalovirus. *J. Infect. Chemother.*, 5, 686-688.
17. Olson, D., & Hantington, M.K. (2010). Co-infection with cytomegalovirus and Epstein-Barr virus in mononucleosis: case report and review of literature. *S.D. Med.*, 9, 351-353.
18. Wang, X., Yang, K., Wey, C., Huang, Y., & Zhao, D. (2010). Coinfection with EBV/CMV and other respiratory agents in children with suspected infectious mononucleosis. *Virology*, 7, 247.

Література

1. Разгуляева А. В. Современные представления об этиологии и патогенезе инфекционного мононуклеоза / А. В. Разгуляева, О. П. Уханова, С. М. Безроднова // Наука и современность. – 2012. – № 2. – С. 62-67.
2. Шарипова Е. В. Герпес-вирусные инфекции и инфекционный мононуклеоз (обзор литературы) / Е. В. Шарипова, И. В. Бабаченко // Журнал инфектологии. – 2013. – № 2. – С. 40-44.
3. Progress and problems in understanding and managing primary Epstein-Barr virus infection / A. Oludare, A. Kristin, H. H. Hogquist, Jr. Balfour // Clin. Microb. Rev. – 2011. – N 1. – P. 193-209.
4. Bravender T. Epstein-Barr-virus, cytomegalovirus and infectious mononucleosis / T. Bravender // Adolesc. Med. State Art Rev. – 2010. – N 2. – P. 251-264.
5. Додатковий метод диференційної діагностики інфекційного мононуклеозу та гострого тонзиліфарингіту на основі гематологічних даних / Ю. В. Варфоломєєва, О. Г. Партоєва, Т. І. Трюханова, В. В. Терещенко // Інфекційні хвороби. – 2014. – № 2. – С. 27-32.
6. Подходы к диагностике хронических форм Эпштейна-Барр вирусной инфекции у взрослых на основе комплексной оценки клинико-иммунологических показателей / [Г.М. Дубинская, Т. И. Коваль, В.А. Боднар и др.] // Клиническая инфектология и паразитология. – 2012. – № 3-4. – С. 55-67.
7. Жураковська Н. О. Патогенетичне значення порушень у системі ПОЛ/АОС, тромбоцитарній ланці гемостазу при інфекційному мононуклеозі та їх корекція: Автореф. дис. ... канд. мед. наук / Н. О. Жураковська. – К., 2015. – 23 с.
8. Крамарев С. А. Інфекційний мононуклеоз у дітей: вопросы патогенеза и лечения / С. А. Крамарев // Здоров'я України. – 2011. – № 4. – С. 57-59.
9. Покровська Т. В. Хронічна Епштейна-Барр вірусна інфекція – актуальні питання / Т. В. Покровська // Інфекційні хвороби. – 2014. – № 2. – С. 70-74.
10. Покровська Т. В. Фенотипічна характеристика лімфоцитів у хворих на гостру та хронічну EBV-інфекцію / Т. В. Покровська, О. М. Зінчук, Г. О. Потьомкіна // Вісник морфології. – 2011. – № 3. – С. 624-628.
11. Особливості диференційної діагностики інфекційного мононуклеозу та оптимізація терапії / А. І. Бобровицька, І. В. Яценко, Н. В. Швецова, В. В. Орленко // Інфекційні хвороби. – 2013. – № 1. – С. 20-24.
12. Казмирчук В. Е. Діагностика и лечение инфекции, вызванной Эпштейна-Барр вирусом / В. Е. Казмирчук, Д. В. Мальцев // Клінічна імунологія. Алергологія. Інфектологія. – 2011. – № 4. – С. 69-75.
13. Клініко-лабораторні особливості перебігу інфекційного мононуклеозу у дорослих / [П. П. Кіш, Г. М. Коваль, В. О. Петров та ін.] // Науковий вісник Ужгородського університету. – 2013. – Вип. 47. – С. 139-144.
14. Клініко-лабораторні показники у хворих на інфекційний мононуклеоз різної етіології / [В. М. Козько, О. І. Могиленець, Н. Ф. Меркулова, та ін.] // Інфекційні хвороби. – 2013. – № 1. – С. 17-20.
15. Терьошин В. О. Сучасні аспекти патогенезу та лікування інфекційного мононуклеозу / В. О. Терьошин, Я. Л. Юган // Інфекційні хвороби. – 2014. – № 2. – С. 5-13.
16. Infectious mononucleosis with atypical manifestations accompanied by transient IgM antibody response for cytomegalovirus / J. Nishikava, T. Miyazaki, H. Fujinami [et al.] // J. Infect. Chemother. – 2011. – N 5. – P. 686-688.
17. Olson D. Co-infection with cytomegalovirus and Epstein-Barr virus in mononucleosis: case report and review of literature / D. Olson, M. K. Hantington // S. D. Med. – 2010. – N 9. – P. 351-353.
18. Coinfection with EBV/CMV and other respiratory agents in children with suspected infectious mononucleosis / X. Wang, K. Yang, C. Wey [et al.] // Virol. J. – 2010. – N 7. – P. 247.

КЛІНІКО-ЕПІДЕМІОЛОГІЧНІ ОСОБЛИВОСТІ ІНФЕКЦІЙНОГО МОНОНУКЛЕОЗУ У ПІВНІЧНО-СХІДНОМУ РЕГІОНІ УКРАЇНИ

В.В. Ільїна, М.Д. Чемич, Н.І. Ільїна, В. Кусі
Сумський державний університет

Мета роботи – вивчення та дослідження клініко-епідеміологічних особливостей інфекційного мононуклеозу (ІМ) у Північно-Східному регіоні України.

Матеріали та методи. Було обстежено 122 пацієнти на інфекційний мононуклеоз, які були госпіталізовані у 2012-2014 рр. у Сумську обласну інфекційну клінічну лікарню імені З. Й. Красовицького. Діагноз ІМ встановлений на підставі епідеміологічних і клінічних даних, результатів додаткових лабораторних та інструментальних методів дослідження відповідно до загальних критеріїв у клінічній практиці.

дження відповідно до загальних критеріїв у клінічній практиці.

Результати. Встановлено, що захворюваність на ІМ у Північно-Східному регіоні України висока і має тенденцію до зростання. Визначено, що на ІМ частіше хворіють діти та особи молодого віку. Підтверджено, що в епіданамнезі у більшості обстежених є вказівка на тривалий контакт з подібним інфекційним хворим. З'ясовано, що хвороба переважно має середньотяжкий перебіг. Визначено, що основними скаргами при ІМ є інтоксикація, біль у горлі при ковтанні, закладеність носа, тяжкість у правому підребер'ї. Встановлено, що у типових випадках гарячка є одним з найбільш постійних ознак хвороби. Підтверджено, що клініка ІМ характеризується вираженим поліморфізмом. Найхарактернішими ознаками при цьому є генералізована

лімфаденопатія, тонзиліт, гепатолієнальний синдром. Визначено, що серед показників загального аналізу крові діагностичними критеріями для ІМ є лейкоцитоз за рахунок лімфоцитозу та моноцитозу, зменшення рівня сегментоядерних нейтрофілів, незначне підвищення вмісту паличкоядерних нейтрофілів, прискорення ШОЕ, а також наявність атипичних мононуклеарів. Дослідження інтегральних гематологічних показників показало, що неспецифічна імунологічна реактивність у хворих на ІМ відрізняється від такої у здорових осіб. З використанням методів специфічної діагностики встановлено, що ІМ викликає не тільки вірус Епштейна-Барр (ВЕБ), а й інші герпесвіруси, особливо цитомегаловіруси (ЦМВ), а також часто це є мікст-інфекція – ВЕБ+ЦМВ. Виявлено, що перспективним у лікуванні хворих на ІМ вважається поєднання протівірусних препаратів групи АНА з імуномодулюючими препаратами, призначення антибіотиків необхідне лише в разі приєднання бактерійної інфекції.

Висновок. Захворюваність на інфекційний мононуклеоз у Північно-Східному регіоні України висока і має тенденцію до зростання, часто вражає дітей і молодих людей.

Ключові слова: інфекційний мононуклеоз, вірус Епштейна-Барр, клініко-епідеміологічні особливості.

Information about authors:

Iliina V. – PhD, Associate Professor of the Infectious Diseases with Epidemiology Department of Sumy State University, ilinaviktoria888@gmail.com

Chemych M. – DMS, Professor, Head of the Department of Infectious Diseases and Epidemiology of Sumy State University, chemych@gmail.com

Ilyina N. – PhD, Associate Professor of Infectious Diseases with Epidemiology Department of Sumy State University, ilyina@kinf.sumdu.edu.ua

Kusi Vincent – 5th year student of Sumy Institute of Sumy State University, vincentkusi30@gmail.com

Відомості про авторів:

Ільїна Вікторія Валеріївна – канд. мед. наук, доцент кафедри інфекційних хвороб з епідеміологією Сумського державного університету, ilinaviktoria888@gmail.com

Чемич Микола Дмитрович – доктор мед. наук, професор, завідувач кафедри інфекційних хвороб з епідеміологією Сумського державного університету, chemych@gmail.com

Ільїна Ніна Іванівна – канд. мед. наук, доцент кафедри інфекційних хвороб з епідеміологією Сумського державного університету, ilyina@kinf.sumdu.edu.ua

Кусі Вінсент – студент 5 курсу медичного інституту Сумського державного університету, vincentkusi30@gmail.com

Конфлікт інтересів: немає.

Authors have no conflict of interest to declare.

Отримано 29.06.2017 р.