

UDK 616-006.2.04+618.11-006.2.04-08-053.34

V.S. Konoplitskiy<sup>1</sup>, V.V. Pogorily<sup>1</sup>, A.G. Dubrovin<sup>2</sup>, O.A. Moravska<sup>1</sup>, T.V. Chuhu<sup>1</sup>,  
A.G. Yakymenko<sup>1</sup>, O.A. Lukiyanets<sup>1</sup>

## Strategy and medical approach to treatment of giant sacrococcygeal teratoblastoma with concomitant teratoma in a newborn child

<sup>1</sup>National Pirogov Memorial Medical University, Vinnitsia, Ukraine

<sup>2</sup>Bogomolets National Medical University, Kyiv, Ukraine

PAEDIATRIC SURGERY.UKRAINE.2018.1(58):61-65; doi 10.15574/PS.2018.58.61

The work presents a clinical case of successful treatment of a giant sacrococcygeal teratoblastoma of external-internal localization and teratoma of internal localization in a newborn child. A preoperative preparation, surgery, and postoperative chemotherapy were administered to ensure a satisfactory result.

**Key words:** giant sacrococcygeal teratoblastoma, combined treatment, newborn child.

### Тактика і стратегія лікування гігантської крижово-куприкової тератобластоми у поєднанні з тератомою у новонародженої дитини

**В.С. Коноплицький<sup>1</sup>, В.В. Погорілий<sup>1</sup>, О.Г. Дубровін<sup>2</sup>, О.А. Моравська<sup>1</sup>, Т.В. Чугу<sup>1</sup>, О.Г. Якименко<sup>1</sup>, О.О. Лукіянець<sup>1</sup>**

<sup>1</sup>Вінницький національний медичний університет ім. М.І. Пирогова, Україна

<sup>2</sup>Національний медичний університет імені О.О. Богомольця, м. Київ, Україна

Описано клінічний випадок успішного лікування гігантської крижово-куприкової тератобластоми зовнішньо-внутрішньої локалізації та тератоми внутрішньої локалізації у новонародженої дитини. Проведено передопераційну підготовку, оперативне лікування, післяопераційну хіміотерапію для забезпечення задовільного результату.

**Ключові слова:** гігантська крижово-куприкова тератобластома, комбіноване лікування, новонароджена дитина.

### Тактика и стратегия лечения гигантской крестцово-копчиковой тератобластомы в сочетании с тератомой у новорожденного

**В.С. Коноплицький<sup>1</sup>, В.В. Погорельий<sup>1</sup>, А.Г. Дубровин<sup>2</sup>, О.А. Моравская<sup>1</sup>, Т.В. Чугу<sup>1</sup>, А.Г. Якименко<sup>1</sup>, О.А. Лукіянець<sup>1</sup>**

<sup>1</sup>Вінницький національний медичний університет ім. Н.І. Пирогова, Україна

<sup>2</sup>Національний медичний університет імені А.А. Богомольця, г. Київ, Україна

Описан клинический случай успешного лечения гигантской крестцово-копчиковой тератобластомы наружно-внутренней локализации и тератомы внутренней локализации у новорожденного. Проведено передоперационную подготовку, оперативное лечение, послеоперационную химиотерапию для обеспечения удовлетворительного результата.

**Ключевые слова:** гигантская крестцово-копчиковая тератобластома, комбинированное лечение, новорожденный.

Sacrococcygeal teratoma (SCT) is the most common extragonadal embryonic cell tumor in infants, which starts developing in utero, with clinical manifestations that may occur at any age [5, 6].

SCT involves elements of all three germ layers (ectoderm, endoderm, and mesoderm) [2].

Microscopically, in most cases, differentiated tissue is well determined. The main part of SCT consists of ectodermal tissues, which involve glia, vascular plexus, ganglion cells, and epidermis with derivatives.

The endodermal component is of the smallest distinctiveness; usually, this formation resembles endodermal canal, less frequently – thyroid, liver and respiratory tract tissues.

Mesodermal component is represented mainly with fat, connective tissue, mucous, less frequently with cross-striated and smooth muscle tissue, even more rarely with kidneys and heart tissues [1, 3].

According to morphological classification by F. Gonzalez-Crussi (1982), three SCT types are distinguished: mature, immature, and malignant teratomas [4]. The American Academy of Pediatrics identifies 4 types of SCT according to its localization: type I – prevail external lesions, a tumor is covered with skin with a minimal presacral component, protruding from the perineal area; type II – mostly outer tumor with a significant presacral component; Type III – prevail internal component and

Клінічний випадок

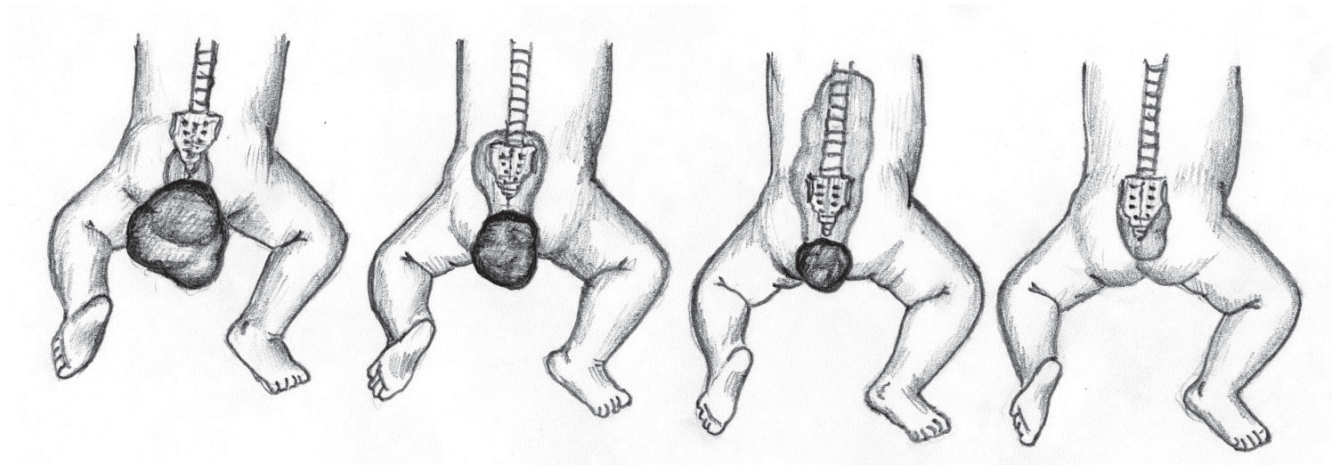
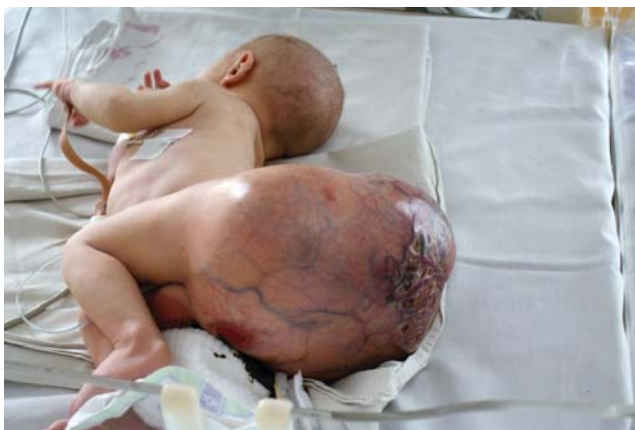
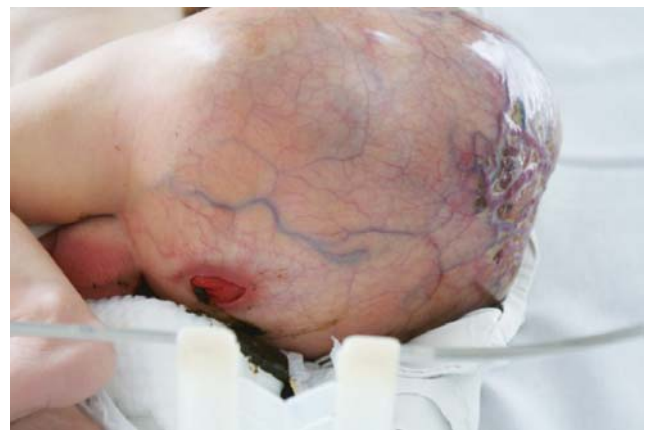
Fig. 1. Types of sacrococcygeal teratoma



A



B

Fig. 2. The patient R., the patient's medical chart No. 9607, age – 1 day: A – general view, B – growth

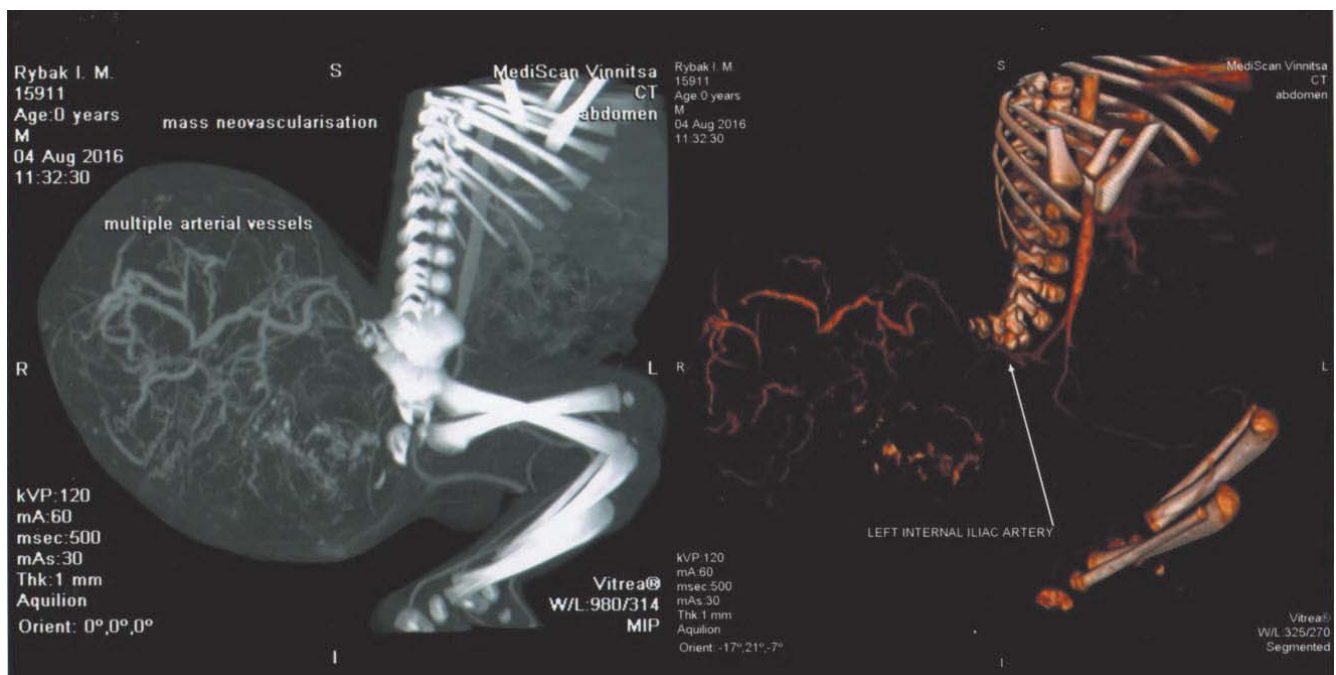


Fig. 3. The patient R., the patient's medical chart No. 9607. Contrast-enhanced MLSCT of abdominal and pelvic cavities

**Table 1**  
Trends in biochemical parameters during the course of treatment

Examination date	Indicator			
	$\alpha$ -fetoprotein, ng/ml	Reference interval, ng/ml	$\beta$ -CGT, general (general chorionic gonadotropin), mIU/ml	Reference interval, mIU/ml
04.08.2016	56754	up to 16400.0	6.55	up to 2.0
19.08.2016	2719	up to 16400.0	0.329	up to 2.0
13.09.2016	97.07	up to 9.0	0.50	up to 2.69
08.11.2016	209.54	0.5-23.5	0,41	up to 2.0
19.12.2016	98.5	0.5-23.5	3.22	up to 2.0

external growth; type IV – presacral tumor without external component (Fig. 1).

The only SCT treatment is surgery that involves removal of tumor with coccyx and pelvic diaphragm muscle plasty. Not removed coccyx is usually associated with tumor recurrence in 40% of cases. Treatment period normally depends on clinical course of the disease, but the sooner tumor is removed, the better is prognosis. This is because SCT, diagnosed after a 2-month age, has a high risk of malignancy, which arrives at 80% after 6 months of age, thus making recovery practically impossible.

The large SCTs and their complications (malignancy, pyopoesis, formation of pelvic abscesses and fistulous passages) are particularly dangerous for patients [7].

In the article the case of the successful treatment of a giant sacrococcygeal teratoblastoma of external-internal localization along with teratoma of internal localization in a newborn child is presented.

The patient R. was born on 20<sup>th</sup> August 2016, delivered by Cesarean section at 40 weeks of gestation, with birth weight 4300 g, body length 51 cm, head circumference 33 cm, chest circumference 32 cm, the 1<sup>st</sup> min. Apgar score – 7 and 5<sup>th</sup> min. Apgar – 8, in a specialized maternity hospital, close to the Clinic of Pediatric Surgery. The mother is 28 year old woman, with a history of mild anemia in the second trimester with underlying cervical erosion and gestational edema, negative results of RW and HIV. The fetal ultrasonography in 33 GWs revealed a congenial malformation – a sacrococcygeal growth. Diagnosis at birth: a large sacrococcygeal teratoma.

In twenty one hours after birth, the child was transferred to the Regional Children's Hospital, the Department of Newborn Anesthesiology and Intensive Care with the diagnosis of giant sacrococcygeal teratoma (Fig. 2).

The additional methods of examination on admission: the abdominal ultrasound revealed multiple encapsulated structures of different sizes, with hypo- and iso-echoic irregular shapes and density, localized in the lower pelvic cavity, with inner blood circulation. Liver

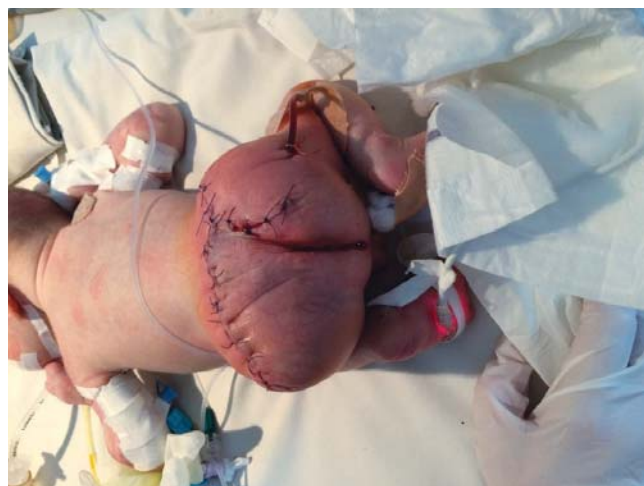was not enlarged, homogeneous, of normal echogenicity, vascular system unchanged, contracted gallbladder, pancreas of normal size, spleen measuring 42×28 mm, of homogeneous structure, no kidney pathology revealed.

The contrast-enhanced MLSCT of abdomen and pelvic cavity with Ultravist-300 6 ml intravenously revealed a large mass lesion, expansively protruding from the lower parts of the back and gluteal areas. The formation had smooth, regular margins, which internal structure was nonuniform and represented by multiple areas of lower density (cystic cavities separated by membranes), measuring 18×14×13 cm, protruding from lumbosacral spine section, which had the signs of severe external deviation. S1, S2, S3 vertebrae did not present any pathological changes. The S4 body is visualized fragmentarily. The well-developed vascular bed of veins dilated up to 3 mm, almost completely filling the vertebral canal, was defined in coccygeal channel at the level of above-mentioned vertebrae. The tumor blood supply carried out through the left internal iliac artery. The structure of the artery presented clear manifestations of neovascularization in the form of multiple tortuous arteries with 3 mm in diameter. The anastomosis was revealed between the left internal and external iliac arteries (at the level of proximal section). The anterior loop of the formation was flat against the back wall of the rectum, deforming it. Infrapiriform and suprapiriform foramina were not changed on both sides. No free fluid was found in the abdominal cavity; the abdominal and retroperitoneal lymph nodes were not enlarged. Liver is of normal size, with unchanged parenchyma density. Pancreas is of normal shape and size, spleen is not enlarged, of homogeneous structure (Fig. 3).

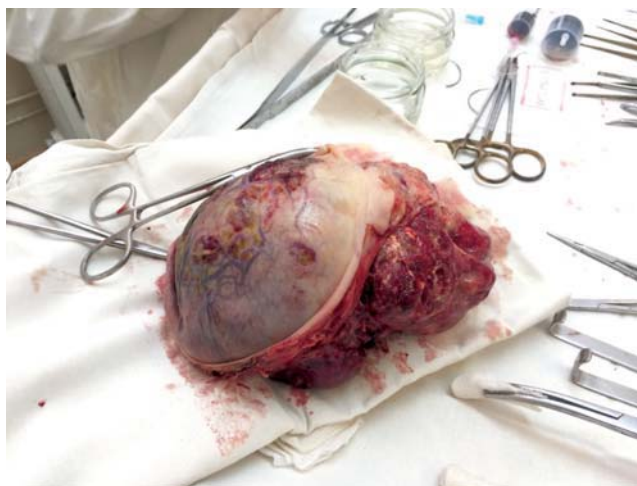
The surgery was performed on 16<sup>th</sup> August 2016, after preoperative preparation, at the age of 13 days after birth: the formation was removed, coccygeal-pelvic ligament plasty was provided. The weight of the removed mass was 1,700 g (Fig. 4).

The histological examination of surgical material specimen No. 38717-22 diagnosed immature teratoma

Клінічний випадок



A



B

**Fig. 4.** The *patient R.*, the patient's medical chart No. 9607: A – the final stage of the surgery, B – the formation removed

(teratoblastoma) of type I with presence of embryonic cartilage, glia, atypical glands, and immature cells of endocrine type.

According to the clinical protocol, treatment of MAKEI germ cell tumor started with chemotherapy, PE unit (cystoplastin + etoposide).

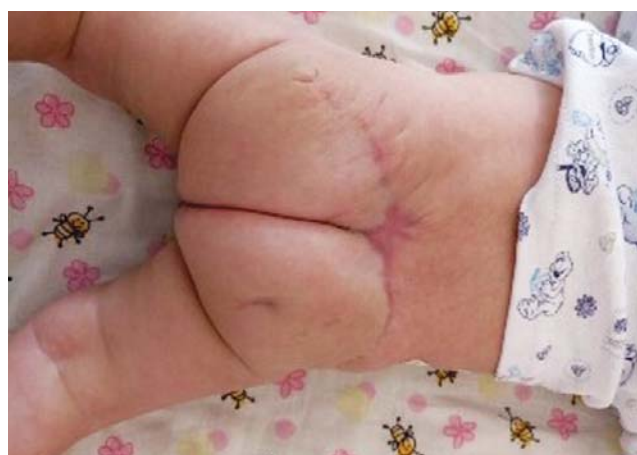After the second PE unit, the control ultrasound (on 17 November 2016) revealed a liquid mass lesion measuring 24×13 mm with a 2.5 mm-thick membrane in the right mesogastric area. Dx: enterocystoma.

The surgery was performed on 23 November 2016: new mass lesion and ileocecal angle were removed (the inspection of abdominal cavity revealed two new growths, 2.8×2.1 mm and 0.6×0.6 mm with their own mesenteriolum in the region of ileocecal angle). During the revision of the small intestine up to lig. duodenojejunalis the lymph nodes sized from 0.4 to 0.6 cm in diameter were revealed.

The histological examination of a new growth No. 57397-8: the removed formation has the structure of hollow body of the colon type with hypertrophied and fibrosing muscular wall, flattened crypts, covered with intestinal type epithelium. The serous membrane presents hemangiomas, while the intestinal wall presents glandular formations of glandular passage type, covered with epithelium of intestinal type.

The histological examination of a lymph node No. 57399 revealed fibrosis and significant vascular component on the background of unchanged structure, areas of lymphoid tissue depletion with symptoms of lymphangiomatosis.

The control contrast-enhanced MLSCT of abdominal and pelvic cavity with Ultravist-300 7 ml intravenously was carried out on 08 December 2016. No pathological



**Fig. 5.** The *patient P.*, the patient's medical chart No. 9607. General view upon discharge on 23 December 2016.

formation in coccygeal area defined in a series of tomogram scans.

The above changes correspond to a mature teratoma.

In the postoperative period, 2 PE blocks (cisplatin 20 mg/m<sup>2</sup> on Days 1-5 + etoposide 100 mg/m<sup>2</sup> on Days 1-3) were additionally administered. The chemotherapy was complicated with the development of toxic post-chemotherapy enteropathy and anemia, which required medical correction.

The control ultrasound examination of the lower third of the gallbladder performed on 12 December 2016 after 4 PE blocks PE presented echogenic inclusion measuring 9.5×4.6 mm with hypoechoic central part, Ø 1.8 mm choledochus.

The analysis of biochemical parameters during the course of treatment was carried out not only for definition of absolute values, but also for prognostic assessment in pre- and post-operative periods (Table. 1).

The final diagnosis: pelvic teratoblastoma, grade 3, clinical group III. Abdominal teratoma. Intra- and ex-

tra-hepatic portal hypertension. Esophagus vein varicose, grade 1. Cholelithiasis.

On 23 December 2016, the child was discharged in satisfactory condition to be followed up and treated outpatiently (Fig. 5). The total duration of inpatient treatment was 142 days.

Rehospitalization was on 30 January 2017. The ultrasound examination performed on 31 January 2017 revealed +1.5 cm enlargement of liver and its increased echogenicity, medium-grained structure, indurated parenchyma, changed vascular system, and recanalization of the umbilical vein. The portal vein was 4 mm in diameter, choledochus – 3.5 mm, contracted gallbladder filled with echo-positive content (calculus measuring 9×4.2 mm). Signs of portal hypertension. No lesions found in the area of postoperative scar.

The contrast-enhanced MLSCT of the abdominal and chest cavities was performed on 03 February 2017, with impression: CT signs of changes following operative treatment of sacrococcygeal teratoblastoma with scarring changes at the level of missing S4, S5 vertebrae and coccyx; CT signs of calculous cholecystitis, cholangitis, intra- and extra-hepatic biliary hypertension, CT signs of solitary sub-pleural foci in D2, D6, D9 segments of the right lung.

The above clinical case is rare; a combination of malignant tumor of external-internal localization and benign tumor of inner localization presents both scientific and practical usefulness. The proposed strategy and medical approach to treatment of the patient's pathology were effective, lifesaving and allow achieving good functional and cosmetic results.

## Conclusions

1. Given the complexity of anatomical localization of SCT, the most informative diagnostic method is contrast-enhanced CT, which allows clearly defining the topographical location of tumor and its positioning against surrounding anatomical structures.
2. Early surgical treatment of SCT, namely removal of the tumor with coccyx, is the only feasible and justified approach to treatment of the pathology.
3. Morphological verification of operational preparation and determination of  $\alpha$ -fetoprotein in the course of disease can determine the malignancy of formation and predict possible outcome.

## References

1. Lev-Chelouche D, Gutman M, Goldman G. (2003). Presacral tumors: a practical classification and treatment of a unique and heterogeneous group of diseases. *Surgery*. 133(5): 473–478.
2. Norris HJ, Zirkin HJ, Benson WL. (1976). Immature (malignant) teratoma of the ovary: a clinical and pathologic study of 58 cases. *Cancer*. 37(5): 2359–2372.
3. Pappalardo G, Frattaroli FM, Casciani E. (2009). Retrorectal tumors: the choice of surgical approach based on a new classification. *Am. Surg.* 75(3): 240–248.
4. Ritchie AC. (Eds.). (1990). *Boyd's Textbook of Pathology*. (9th ed.). Philadelphia and London. 1, 2.
5. Srivastava A, Jaiswal AK, Jain K. (2010). Sacrococcygeal teratoma. *J. Pediatr. Neurosci.* 5. 1: 30–31.
6. Swamy R, Embleton N, Hale J. (2008). Sacrococcygeal teratoma over two decades: birth prevalence, prenatal diagnosis and clinical outcomes. *Prenat. Diagn.* 28, 11: 1048–1051.
7. Urioste M, Garcia-Andrade MC, Valle L. (2004). Malignant degeneration of presacral teratoma in the Currarino anomaly. *Am. J. Med. Genet. A.* 128A(3): 299–304.

## Відомості про авторів:

**Коноплицький Віктор Сергійович** – д.мед.н., зав. каф. дитячої хірургії Вінницького національного медичного університету ім. М.І. Пирогова. Адреса: м. Вінниця, вул. Пирогова, 56.

**Погорілий Василь Васильович** – д. мед. н, проф. каф. дитячої хірургії Вінницького національного медичного університету імені М.І. Пирогова. Адреса: м. Вінниця, вул. Пирогова, 56.

**Дубровін Олександр Глібович** – д. мед. н, проф. каф. дитячої хірургії Національно медичного університету імені О.О. Богомольця. Адреса: м. Київ, вул. В. Чорновола, 28/1.

**Моравська О.А.** – каф. дитячої хірургії Вінницького національного медичного університету імені М.І. Пирогова. Адреса: м. Вінниця, вул. Пирогова, 56.

**Чузу Т.В.** – каф. дитячої хірургії Вінницького національного медичного університету імені М.І. Пирогова. Адреса: м. Вінниця, вул. Пирогова, 56.

**Якименко Якименко Олександр Григорович** – к. мед. н, доц. каф. дитячої хірургії Вінницького національного медичного університету імені М.І. Пирогова. Адреса: м. Вінниця, вул. Пирогова, 56.

**Лукіянець Олег Олександрович** – аспірант каф. дитячої хірургії Вінницького національного медичного університету імені М.І. Пирогова. Адреса: м. Вінниця, вул. Пирогова, 56.

Стаття надійшла до редакції 30.09.2017 р.