

УДК [617.736-005.98-02:616.379-008.64]-085.357-089.855-031: 611.844.7]-06

Accidental intralenticular injection of dexametasone intravitreal implant during the treatment of refractory diabetic macular oedema

M. I. Kovtun ¹, V. V. Klymenko ², V. V. Sardaryan ³, N. M. Kovtun ¹

¹ City Clinical Hospital № 14 named after Prof. L. L. Gyrschman, Kharkiv (Ukraine)

² Kharkiv National Medical University, Ophthalmology Department Kharkiv (Ukraine)

³ International Medical Center Oftalmika Kharkiv (Ukraine)

This article deals with the clinical case of accidental intralenticular injection of dexamethasone implant during the treatment of refractory diabetic macula oedema. The paper is based on a comprehensive research of similar clinical cases regarding this complication. The therapy algorithm chosen by the authors is early-surgery approach with cataract phacoemulsification and relocation of Ozurdex to the vitreous body, which showed positive clinical effect.

Key words: diabetic retinopathy, diabetic macular oedema, dexamethasone intravitreal implant, complication, intralenticular Ozurdex implantation.

Topicality

Diabetes mellitus (DM) is one of the most common chronic diseases. According to the International Diabetic Federation, 415 million people aged 20-79 suffered from DM in 2015 (1 out of 11 adults on the planet), and by 2040 the number of patients might rise to 642 million (1 out of 10 adults). The rising numbers of DM patients will bring about an increase in the number of complications such as diabetic retinopathy and diabetic macular oedema (DMO). Diabetic retinopathy is the main reason of blindness among working-age population (20-72 years of age). DMO affects approximately 7 % of people with DM, which is 29,05 million people if the said data is extrapolated with regard to the whole population.

There are several options for DMO treatment: laser treatment, anti-vascular endothelial growth factor (anti-VEGF), corticosteroids. The research of new treatment methods continues. In 2014 the Food and Drug Association (FDA) approved dexamethasone intravitreal implant Ozurdex (Allergan, Inc., Irvine, CA, USA) for DMO. Apart from this, Ozurdex is also used in cases of macular oedema following branch retinal vein occlusion (BRVO) or central retinal vein occlusion (CRVO) and noninfectious uveitis.

We have been applying the foregoing method in our clinic since 2015. In Kharkiv City Hospital # 14 named after prof. Gyrschman were made 22 intravitreal dexamethasone implant injections during this period with positive effects. In 2017 we had one side effect after this procedure – that is the clinical case of intralenticular implantation of Ozurdex (Allergan, Inc., Irvine, CA, USA).

Clinical case and discussion

Anamnesis morbid. A 53-year old patient has been suffering from DM type 2 for 10 years. He had diabetic retinopathy for 4 years and had a 2-year history of diabetic macular oedema in the right eye (see fig. 1). Visual acuity

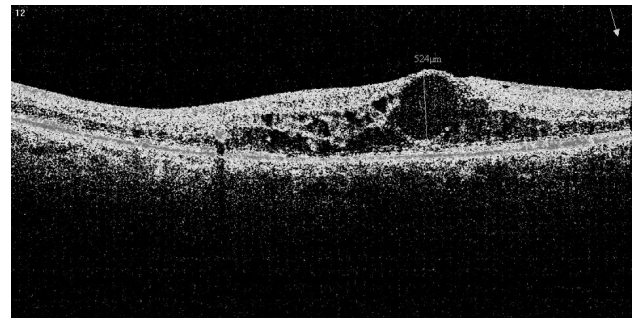


Figure 1. OCT of patient with DMO

was 0,2 (decimal) and he has had 3 injections of aflibercept since 2015 and 1 injection of ranibizumab in 2016 with no positive dynamic. He had an Ozurdex injection 1 year ago with positive clinical effect and it was decided to continue treatment with Ozurdex injection.

Treatment. For dexamethasone intravitreal implantation topical anesthesia was applied with proparacaine hydrochloride 0,5%. The procedure was performed by a highly qualified ophthalmologist. The patient was examined on the next day following the procedure and Ozurdex implant was revealed in the crystalline lens (see fig. 2). The pressure in the eye was 15 mmHg and the vision dropped to 0.05 (decimal). On the ultrasound the thickness of lens was 5,76 mm.

We have never seen this complication before and therefore a number of questions appeared: should we reimplantate Ozurdex? Is it necessary to do vitrectomy? When is it better to do cataract surgery? How to deal with the outcome? First of all, we had to choose the future strategy of treatment and the Internet search with MEDLINE/PubMed and Embase was conducted. Several

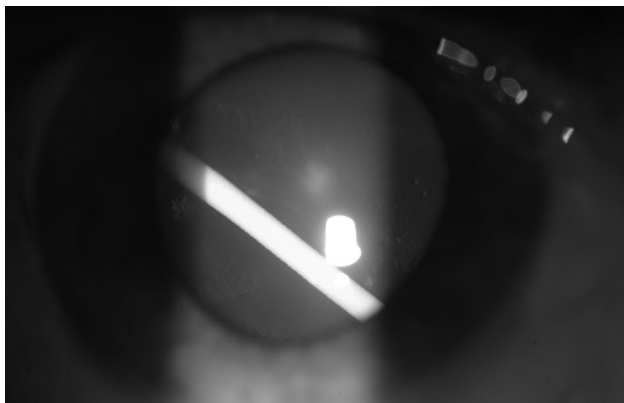


Figure 2. Biomicroscopy - intralenticular injections of dexamethasone implant

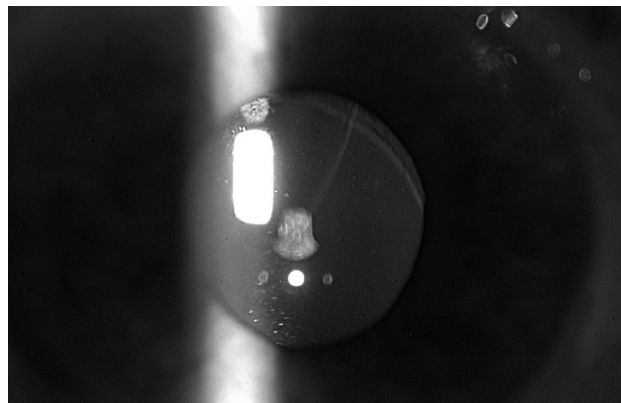


Figure 3. Biomicroscopy - first day after surgery

similar clinical cases were found in the world. In particular, Dr. J. Coca-Robinot from Spain described two similar cases and recommended early cataract surgery to avoid an elevation of intraocular pressure (IOP), cataract maturation and more difficult surgery. Dr. A. Berarducci from West of England Eye Unit (the UK) successfully treated an intravitreal dexamethasone implant injection into the lens body by surgical extraction of the implant from the lens and implant of a 3-piece intraocular lens in the sulcus. In addition, there were a few cases where Ozurdex stayed in lens for a longer period. Dr. B. Baskan from Turkey observed the patient after 14 months of intralenticular location of Ozurdex and reported that Ozurdex does not work in crystalline lens as well as it does in the vitreous, and dissolved longer. In the article “Immortal Ozurdex: A 10-month follow-up of an intralenticular implant” Dr. B. Poornachandra from India recommended his patient to have a late date cataract surgery and regular follow-up. The said patient didn't experience a rise in IOP and the OCT showed the reduction of macular oedema. There are several approaches to choosing time for cataract surgery: late-date or early-date surgery. These are no strict recommendations on how to manage these patients, and the approach may vary from case to case. In fact, several indicators should be considered - IOP, lens density and changes in macular thickness.

Pending the doctor's consilium headed by Dr. M.I. Kovtun the strategy of early cataract surgery (during the first month) was chosen. The stages of surgical intervention were as follows: at first, the phacoemulsification of cataract with posterior capsulorhexis and relocation of implant from capsule to vitreous body was made, and then the surgery continued with anterior vitrectomy through corneal paracentesis and an injection of one-piece lens in the capsular.

The results were assessed in one month after the surgery. The vision in the right eye was 0,7 (decimal); pressure - 12 mmHg; the lens were in a capsular bag and

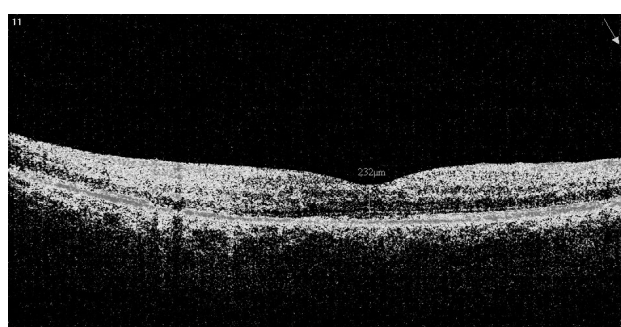


Figure 4. Catamnesis – patient's OCT one month after Ozurdex relocation to the vitreous

dexamethasone implant was located in vitreous (see fig. 3). Macular thickness changed from 524 μm to 232 μm (see fig. 4).

It was presented as a successful case of early-date surgery, when the cataract was not dense and Ozurdex was relocated to vitreous body in order to increase its distribution to retina. The patient didn't have any problems with an increase of intraocular pressure during the period of treatment and the maximum value of IOP was 16 mmHg. Based on our experience, subconjunctival anesthesia is better for the injection of Ozurdex to decrease discomfort of patient and increase compliance in the course of the procedure.

This kind of complication may occur even with highly qualified professionals. Therefore, it is important to give information about this side effect in the patient's informed consent before proceeding with Ozurdex implantation.

Conclusion

Early cataract surgery with Ozurdex dislocation to the vitreous body may be used for treatment of accidental intralenticular injection of dexametason intravitreal implant.

References

1. **Prokofyeva E.** Epidemiology of major eye diseases leading to blindness in Europe: a literature review / E. Prokofyeva, E. Zrenner // *Ophthalmic Res.* – 2012. – Vol. 47, № 4. – P. 171-88.
2. Diabetic Retinopathy Clinical Research Network. A Randomized Trial Comparing Intravitreal Triamcinolone Acetonide and Focal/Grid Photocoagulation for Diabetic Macular Edema // *Ophthalmology.* – 2008. – Vol. 115, № 9. – p. 1447-9.
3. Cunningham E.T. A phase II randomized double-masked trial of pegaptanib, an anti-vascular endothelial growth factor aptamer, for diabetic macular edema / E.T.Cunningham, A.P. Adamis, M. Altaweel, L.P. Aiello, N.M. Bressler, D.J. D'Amico, M. Goldbaum, D.R. Guyer, B. Katz, M. Patel, S.D. Schwartz // *Ophthalmology.* – 2005. – Vol. 112, №10. – P. 1747-57.
4. <http://www.ozurdex.com/DME/About-DME>
5. **Coca-Robinot J.** Accidental injections of dexamethasone intravitreal implant (Ozurdex) into the crystalline lens / J. Coca-Robinot, B. Casco-Silva, F. Armada-Maresca, J. García-Martínez // *Eur J Ophthalmol* – 2014. – Vol. 24. – P. 633-6.
6. **Berarducci A.** Inadvertent dexamethasone implant injection into the lens body management / A. Berarducci, I.S. Sian, R. Ling // *Eur J Ophthalmol.* – 2014. – Vol.24, №4. – P. 620-2.
7. Baskan B. Ozurdex completely located inside a crystallized lens - Results of 14 months / B. Baskan, A. Cicek, A. Gulhan, M. Gundogan, S. Goktas // *American Journal of Ophthalmology.* – 2016. – Vol. 4. – P. 38-40
8. **Poornachandra B.** Immortal Ozurdex: A 10-month follow-up of an intralenticular implant / B. Poornachandra, V. Kumar, C. Jayadev, S.H. Dorelli, N.K. Yadav, R. Shetty // *Indian J Ophthalmol.* – 2017. – Vol. 65, №3. – P. 255-257.

Received 26.12.2017

Непреднамеренное интраленткулярное введение импланта дексаметазона при лечении рефрактерного диабетического отека макулы

Ковтун М. И., Клименко В. В., Сардарян В. В., Ковтун Н. М.

Городская клиническая больница им. проф. Л.Л. Гиршмана № 14; Харьков (Украина)

Харьковский национальный медицинский университет; Харьков (Украина)

Международный медицинский центр "Офтальмика"; Харьков (Украина)

Описан клинический случай – непреднамеренное интраленткулярное введение импланта дексаметазона при лечении рефрактерного диабетического макулярного отека. Проведен литературный поиск по проблеме лечения данного осложнения. Выбран

алгоритм терапии - ранний хирургический подход с факоэмульсификацией катаракты и дислокацией импланта Озурдекса в стекловидное тело, при котором отмечен положительный клинический результат.

Ключевые слова: диабетическая ретинопатия, диабетический макулярный отек, имплант дексаметазона, осложнение, интраленткулярное введение Озурдекса.