

© V.L. Denysenko, 2015

УДК 616.345/.35 – 006.6 – 007.272 – 089:[616 – 072 – 77 +621.791.318

V.L. DENYSENKO

*Establishment of public health «Second Vitebsk regional clinical hospital»*

## COMPLEX TREATMENT OF COLORECTAL CANCER COMPLICATED WITH INTESTINAL OBSTRUCTION

In surgery, as well as oncology, the trend of complex treatment based on the concept of “rapid (enchanced) recovery”, the so called «Fast-Track Recovery» or «Fast-Track Surgery», is coming into force. It is founded on the modern high-technology approaches application in the treatment of obstructing colorectal cancer complicated with intestinal obstruction including the effective use of endoscopic stenting at the first stage (self-expanding silicone covered nitinol stent frame expanding bowel lumen in the tumour stenosis zone (CHOOSTENT M.I.Tech, South Korea [CY]), at the second stage of radical operation performance within a single hospitalization. Early endoscopic intestinal decompression as the first stage of “Fast-Track Recovery” concept realization in combination with the program of complex drug correction of homeostasis and intraparietal intestinal hemocirculation disturbances enable to eliminate morphofunctional disturbances of adducting intestinal portions on short notice and perform radical surgical treatment of colorectal cancer on the principle of routine intervention in the absence of problems with adducting intestinal portion and the possibility of reliable single-stage restoration of digestive tract continuity.

The given approach allows to rule out intermediate stages, to decrease the total duration of treatment and rehabilitation of patients, to obtain high quality of patient’s life in the intermediate and distant future. This trend in the practical health service is only coming into force, showing the positive aspects and prospects of usage, which enable to improve qualitative and quantitative indices of treatment of various diseases substantially.

**Key words:** stenting, laser vaporization, colorectal cancer, tumour recanalization

**Introduction.** Colorectal cancer is the most widespread tumour in colorectal surgery, the third common cancer and the second cause in the structure of oncological deaths [7]. The evolution from invariable bowel to diagnosed cancer is 10 years. The annual incidence in the USA is 145000 new cases, 5500 deaths from colorectal cancer (9-10% from other causes oncological mortality). The average morbidity risk during the life period is 1 per 18 Americans (5-6%). The incidence peak is the 7<sup>th</sup> decade of life; though 5% of patients are under 40, 10% are under 50. 90% patients have sporadic tumours, 10% have positive family history [7]. According to cancer register of the Republic of Belarus in the past decade colorectal cancer morbidity has increased 1,5 times (from 363 since 2001 to 528 in 2010) [4]. Up to 70% of patients with obstructing colorectal cancer complicated with intestinal obstruction are delivered to the in-patient department by emergency indications. As a result more than half of the patients are hospitalized in severe condition. The latter is due to accompanying cardiovascular and respiratory pathology [1].

Obstructing colorectal cancer complicated with intestinal obstruction is the most frequent complication of colonic cancer. It develops in 26,4 – 69% patients [2]. This complication is the most common for left colon tumours (67-72 %), which is related to the peculiarities of the local growth (endophytic, circular), the intramural lymphatic outflow specifics, as well as higher density of this localization tumour and smaller diameter of the bowel [3, 5, 6].

Surgical approach in obstructing colorectal cancer complicated with intestinal obstruction against the background of cancer remains the hot topic. The choice of the surgical treatment and operation completion is under discussion, which requires further scientific search and study of the possibility of realization of new directions for solving the problem.

**The aim of the investigation.** To improve the results of complex treatment of obstructing colorectal cancer complicated with intestinal obstruction using “Fast-Track Recovery” technologies.

**Materials and methods.** At present in surgery, as well as oncology, the trend of complex treatment based on the concept of “rapid (enchanced) recovery” (the so called “Fast-Track Recovery” or “Fast-Track Surgery”) is coming into force. It is founded on modern high-technology approaches application including effective use of the main achievements of the VI technological setup of the civilization, which enable to minimize the duration of treatment, to decrease economic expenses, to maximize ultimate results, to ensure high quality of treatment. The given approach allows to rule out intermediate stages, to decrease the total duration of treatment and rehabilitation of patients, to obtain high quality of patient’s life in the immediate and distant future. Minimal invasive and low degree traumatic operative techniques application, with endoscopic stenting, enables to provoke intestinal decompression within a single hospitalization following radical operation with primary anastomosis application. The given approach not only results in rapid recovery with substantial shortening of total duration of treatment and rehabilitation but also leads to considerable reduction in economic expenses for treatment, has a significant social effect due to more rapid and significant quality of patient’s life restoration.

After restoration of natural passage of intestinal contents and motor and evacuating function of the digestive tract, without discharging the patient from the in-patient department, the radical intervention with tumour removal and single-stage restoration of digestive tract continuity is performed.

The analysis of treatment outcomes for 138 patients with colorectal cancer complicated with intestinal obstruction under treatment in the colorectal department of Vitebsk Second Regional Teaching Hospital and

abdominal department of Vitebsk Regional Clinical Oncological Dispensary from 1995 to February 2013 has been made. In the first group the patients (78) were operated for colorectal cancer complicated with intestinal obstruction using general approach (with application two- and more stage interventions). "Fast-Track Recovery" principle was used for the treatment in the second group of patients (40) (at the first stage minimal invasive "closed" stenting of obstructing tumour with resolution of intestinal obstruction episodes was performed, at the second stage the radical operation with primary anastomosis application and restoration of digestive tract continuity was performed). In the third group of patients (20) "Fast-Track Recovery" principle was used for the treatment (at the first stage laser re-

canalization of obstructing tumour was performed by laser radiation with the wave length 1,064 mkm, maximal average power 60 watt, impulses recurrence frequency at maximal radiation power up to 50 Hz, maximal impulse energy 1,2 J, impulse duration 300 msec, laser danger class IV, maximal consumed power 2,5 kilowatt per second, at the second stage radical operation with primary anastomosis application and restoration of digestive tract continuity was performed).

**The results and discussion.** The first group included the patients treated for complicated colorectal cancer in the in the colorectal department of Vitebsk Second Regional Teaching Hospital from 1995 to 2012. The mean age of the patients was  $65,2 \pm 2,5$ . The structure of tumour lesion is presented in Table 1.

Table 1

Tumour lesion structure of the first group patients

Tumour localization and shape	Patients number	%
Caecum cancer	2	3
Ascending colon cancer	1	1
Colon hepatic angle cancer	2	3
Transverse colon proximal cancer	1	1
Transverse colon cancer	4	5
Descending colon cancer	3	4
Sigmoid colon cancer	33	42
Sigmoid colon mesentery adenocarcinoma	1	1
Rectosigmoid cancer	7	9
Upper ampullar rectum cancer	16	21
Middle ampullar rectum cancer	8	10
Total:	78	100

Meanwhile, cancer of the left colon and rectum complicated with intestinal obstruction made up 86%. The structure of operative interventions for acute colonic obstruction in the first group of patients is

presented in Table 2, 3, 4. In 69% cases the operation in the first group patients was completed with intestinal stoma exteriorization. The mean treatment duration in this group was  $30,6 \pm 2,8$  bed days.

Table 2

Operative interventions in the first group patients characteristic

Operations	Patients number	%
Anterior resection of rectum	14	18
Abdominoperineal extirpation of rectum	4	5
Gartman operation	39	50
Abdominoanal resection	1	1
Right hemicolectomy, ileotransversostomy	2	3
Sigmoid colon resection	3	4
Relaparotomy, ileostomy	1	1
Transverse colon resection	5	6
Collateral ileotransversostomy, cholecystectomy	1	1
Left hemicolectomy	2	3
Double-barreled ileostomy, nasogastrintestinal probe decompression	1	1
Loop sigmoidostomy	2	3
Rectosigmoidtransition, sigmoidostomy	1	1
Tumour removal, hysterectomy with uterine appendages, omentum resection, sigmoidostomy	1	1
Tumour conglomerate resection from the cecum and ascending colon, ileostomy	1	1
Total:	78	100

Table 4

## Operative interventions in the first group patients characteristic

Tumour has been removed	Tumour has not been removed	Operations with application of anastomosis and preventive stoma surgery	Operations of removing tumour with stoma surgery	Operations without removing tumour with stoma surgery	Operations of removing tumour with application of primary anastomosis
63	15	3	45	13	18

Table 4

## Operative interventions in the first group patients characteristic

T3 N0 M0	T3 N1 M0	T3 N1 M1	T3 Nx M1	T3 Nx M0	T3 N0 M1
17	8	0	1	5	1

T4a N0 M0	T4a N0 M1	T4a N1 M1	T4a Nx Mx	T4a Nx M0	T4a N1 M0	T4a N2 M1	T4a N2 M0	T4a Nx M1	T4a N2 M1
19	2	7	1	2	5	6	1	2	1

Distant liver metastases were revealed. Two patients had rhythm disturbance in the post-operative period. No patient died.

The second group included the patients treated for complicated colorectal cancer in the abdominal department of Vitebsk Regional Clinical Oncological Dispensary and in the colorectal department of

Vitebsk Second Regional Teaching Hospital over the period from 2011 to 2013. The mean age of the patients was  $70,1 \pm 4,2$ . Under further histological investigation all the patients were revealed moderately differentiated adenocarcinoma. The structure of the colonic and rectal tumours is presented in Table 5, 6.

Table 5

## Tumour lesion structure of the second group patients

Tumour localization and shape	Patients number	%
Upper ampullar rectum cancer	10	25
Sigmoid cancer	12	30
Rectosigmoid cancer	12	30
Colon splenic angle cancer	6	10
Total:	40	100

Table 6

## Tumour lesion structure of the second group patients

T3 N0 M0	T3 N1 M0	T4a N0 M0	T4a N0 M1	T4a N1 M0	T4a N1 M1
7	3	23	3	2	2

The diagnosis of obstructing left colon (rectum) cancer complicated with intestinal obturation obstruction was made in all the cases. The conducted medical and diagnostic technique by Vishnevsky had no effect in all the cases. Following short-term (2 hours) preparation including potassium polarizing mixture transfusion, crystalloides and colloidal solutions (up to 2 litres in volume) and premedication (Promedol solution 2%-1,0 ml + Atropine solution 0,1% – 1,0 ml) all the patients underwent fibrocolonoscopy, which confirmed the diagnosis of left colon tumour. Stenting was performed without narcosis or anaesthesia. Instrumental bougienage of tumour stenosis zone with special guide of the average rigidity with soft J-shaped

tip was carried out. Delivery devise for self-expanding tube prosthesis was placed through dilatation stenosis zone. Further a rigid guide was introduced into the bowel through the lumen of manipulation catheter for a distance of no less than 10 cm proximal to the upper stenosis edge. Self-expanding silicone covered nitinol stent 22 mm in diameter and 140 mm in length frame expanding the bowel lumen in the tumour stenosis zone (CHOOSTENT M.I.Tech, South Korea [CY]) was placed in the constriction zone through the rigid guide. The position of the stent in the bowel was under control (Figure 1). The overall colonoscopy procedure with stent placement lasted about 40 minutes ( $37,6 \pm 4,13$  minutes). The manipulation was

uneventful. There was no aspiration in the lungs. One stent after bougienage and its planting fell out from the medium-ampullar part. There were no bleedings or intestinal perforations. The most simple was the stent planting in the upper ampullar and rectosigmoid parts.

Following the device introduction control radiography of the abdomen was performed (Figure 2). After the stent placement a siphon enema was given, which followed by abundant passage of gases and defecation. The patients were administered saline laxatives, vaseline oil. Potassium polarizing mixture with cardiac glycosides, crystalloides balanced polyelectrolytic

mixtures, Reamberin were given by intravenous dripping. Cefazoline 1,0 was administered three times per day, Fragmin 2,5 was injected subcutaneously once per twenty four hours, the accompanying pathology was corrected. Intestinal obstruction episodes were arrested completely in all the patients by the end of the 24 hour period following the manipulation. Beginning with the second twenty four hour period the patients started receiving enteral feeding. After the complete clinical and metabolic compensation of the patients and complete restoration of motor and evacuating function surgical interventions were made. The following operations were performed (Table 7).

Table 7

## Kinds of operations in the second group

Operations	Patients number	%
Sigmoid colon resection	19	47
Low anterior resection of rectum	14	35
Left hemicolectomy, splenectomy	4	10
Subtotal colectomy, splenectomy	3	8
Total:	40	100

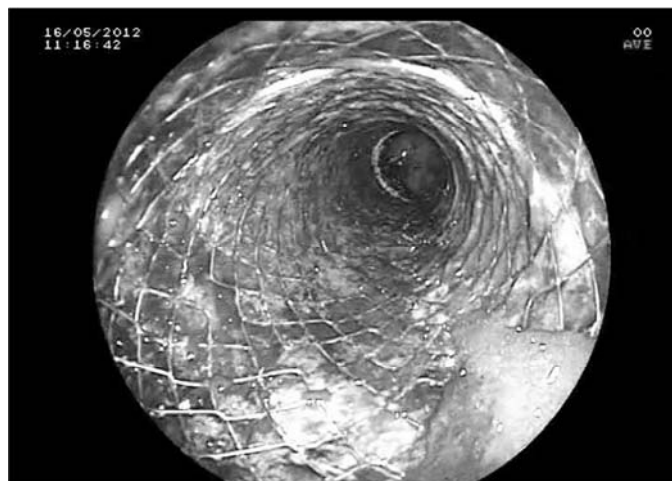

Fig. 1. Dilated sigmoid lumen in the tumour zone following stent placement CHOOSTENT M.I.Tech, South Korea (CY)

All radical operations were completed with the formation of the primary anastomosis without colostomy exteriorization. The postoperative period was uneventful. The duration of treatment in this group was  $19,7 \pm 2,1$  days of bed regimen.

Distant liver metastases were revealed in 5 patients. Such complications as exacerbation of ischemic heart disease occurred in 5 patients. On an average the period between the stenting and the operation was  $4,44 \pm 1,78$  days. Minimum: 1 day, maximum: 7 days. This spread took place on the stage of development of the technique. I consider the period of 4 days as optimal. Laparoscopic operations have not been performed. In 7 cases lymph nodes of the splenic vein were involved in

the process and the spleen was drawn in the conglomerate.

The third group included the patients being treated for complicated colorectal cancer in the abdominal department of Vitebsk Regional Clinical Oncological Dispensary and in the colorectal department of Second Vitebsk Regional Clinical Hospital over the period from 2012 to February 2013. The mean age of the patients was  $62,4 \pm 7,32$ . All the patients had signs of colonic obstruction – failure to pass feces and gases within the last 2-4 days, abdominal distension, pneumatosis coli (revealed by percussion and X-ray) with lumen dilatation 2-2,5 times, pneumatosis of the small intestine. In one case the distant peritoneal metastases and in two cases distant liver metastases were revealed.

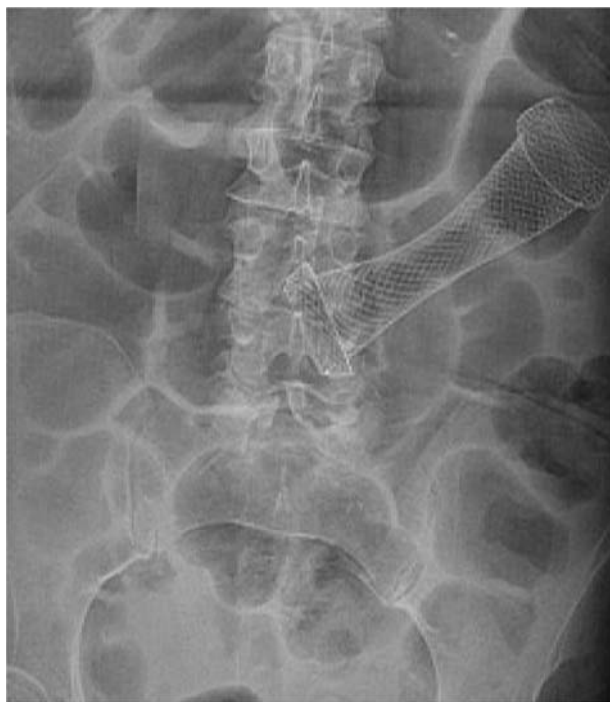

Fig. 2. Plan survey radiograph of the abdominal cavity immediately after self-expanding intestinal stent placement into the sigmoid colon

Table 8

Patients distribution by tumour process localization in the basic and control groups

Obstructing tumour localization		%
Rectal cancer	6	30
Rectosigmoid colon cancer	6	30
Sigmoid colon cancer	4	20
Descending colon cancer	4	20
Total	20	100

On admission to the in-patient department (up to 24 hours) all the patients underwent medical and diagnostic recto- or colonoscopy, under which after making the diagnosis of obstructing tumour of the colon and biopsy laser vaporization of the inner part of the tumour with digestive tube lumen restoration in the tumour zone up to 0,8-1 cm was performed. Following laser recanalization the patients were given a siphon enema, which resulted in effective antegrade colon emptying in 100% cases. The patients were administered laxatives and vaseline oil. The treatment complex included daily infusion therapy (crystalloid and colloid solutions, potassium polarizing mixture, according to indications – parenteral feeding preparations), Diavetol 15-20 mg/kg (by dry substance), Emoxipine 1,5-2,5 mg/kg, Pentoxifylline 0,2% solution 200-400 ml/daily and Reamberin 400-800 ml/daily (or Cytoflavin 10 ml of solution in 100 ml of 0,9% solution sodium chloride) were given intravenously. After 4-6 days without discharging the patient from the in-patient department in the state of clinical and metabolic compensation radical operation with primary restoration of digestive tract continuity was

performed (only in 1 patient tumour recanalization became ultimate symptomatic operation owing to the severity of background pathology with cardiovascular function decompensation). Sigmoid colon resection, low anterior rectal resection, left hemicolectomy with primary digestive tract continuity restoration using circular mechanic suture were made as radical interventions.

Under recto- and colonoscopy during the first stage of “Fast-Track Recovery” concept realization in the third group patients under endoscopic investigation colonic and rectal lumen constriction was found to vary from 5 to 8 mm (the average diameter in the stenosis zone was  $7,32 \pm 2,11$  mm). While the extent of stenosis zone ranged from 5 to 100 mm (on average  $7,12 \pm 1,97$  mm) (Figure 3). Under laser vaporization of the obstructing tumour portion using laser apparatus “Photek LK-50” (“Mediola-Endo”) impulse regimen of energy generation was applied (wave length 1,064 MCM, power – 20-25 watt, impulses recurrence frequency at the maximal radiation power – up to 50 Hz, maximal impulse energy – 1,2 joule, impulse duration 300 msec).

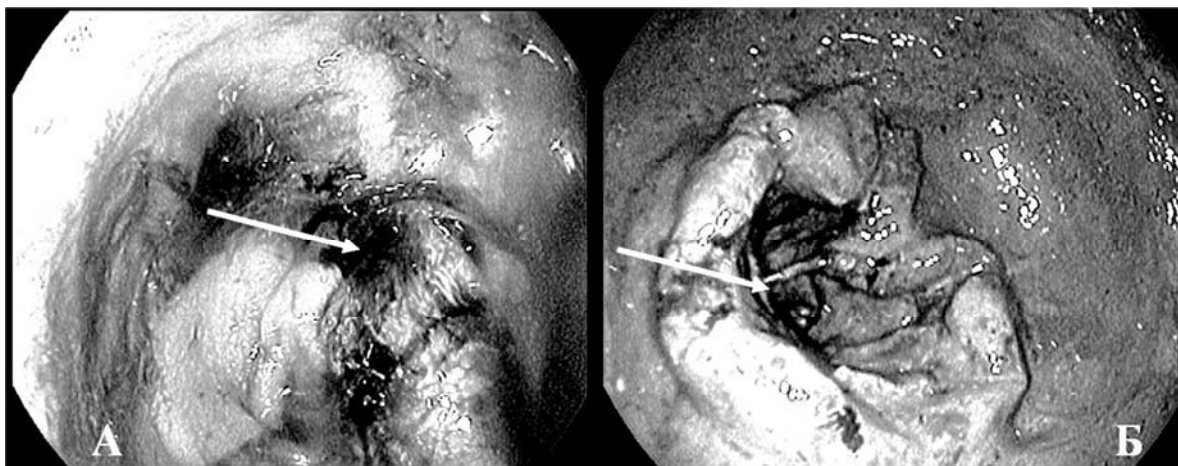


Fig. 3. Obstructing cancer of the descending colon with lumen diameter in the constriction zone 5 mm (A) and obstructing cancer of the rectum with lumen diameter in the stenosis zone up to 6 mm (B). Colonoscopy findings. The stenosis zone is marked with arrows

On practising the regimen of vaporization the most effective distance from the end of quartz optical fiber to the irradiated tissue was found to be 3-5 mm. Meanwhile, the treatment of the protruding tumour portion was conducted in scanning regimen along the perimeter of obstructing tumour tissue. The contact of the end of optical fiber with tissue resulted in optical fiber burning with further vaporization efficacy decrease.

The procedure of laser recanalization lasted from 25 to 65 minutes (on the average  $40,0 \pm 11,4$  min.). Smoke generation and the excess motion (which demanded additional medical sedation in 1 case) had an adverse effect on the duration of the procedure. Laser vaporization of the inner tumour part was conducted

until digestive tube lumen restoration in the tumour zone to no less than 0,8-1 cm. In 5 cases (25%) repeated laser vaporization of tumour tissue was required to reach target size of recanalization. Even with incomplete restoration of colonic lumen in the tumour zone even within the first twenty four hours after the manipulation the patients had abundant passage of gases, 40% had unassisted stool. After twenty four hours all the patients had no clinical and roentgenologic evidence of colonic obstruction. The maximal recanalization effect was observed after 1-2 days following laser procedure (Figure 4), which was due to gradual rejection of necrotic tissues into the bowel lumen. There were no hemorrhages related to devitalized tumour tissues rejection.

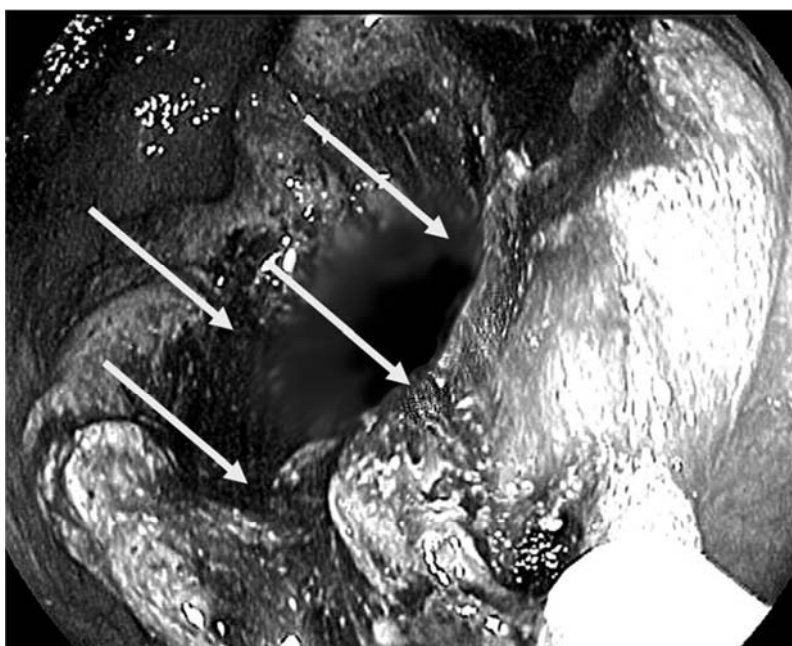


Fig. 4. Sigmoid colon recanalization zone (the borders are marked with arrows)

Laser recanalization was technically complicated in cases of poor visibility of canal orifice in the tumour, in predominantly infiltrating character of its growth, impossibility to fix the endoscope on the axis with tumour canal, as well as marked morbidity in insufflation and “overinflation” of the overlying colon portions due to valve formation in the tumour canal zone. There were no bleedings or intestinal perforations. In 5 cases a repeated laser vaporization of malignant tissue was needed to achieve the wanted recanalization size, while in one case additional drug sedation was required. On an average the period between vaporization and operation lasted  $4,18 \pm 1,8$  days. Minimum: 1 day, maximum: 8 days. This spread took place on the stage of development of the technique. I consider as optimal the period of 4 days. Laparoscopic operations have not been performed.

All the operations have been performed with great care that in whole resulted in successful outcome. In case of the slightest risk the laser vaporization or stenting were stopped.

In one patient tumour recanalization became a final symptomatic operation in view of severe background pathology with decompensation of the cardiovascular function. At the same time we carried out symptomatic treatment of concomitant pathology. In radical surgery stoma has not been delivered.

The performed laser recanalization allowed an uneventful adequate preparation of the colon and routine sigmoid radical resection. After laser destruction and restoration of the colonic lumen in the tumour zone a siphon enema was given, which resulted in abundant defecation and passage of gases. The patients were administered laxatives and vaseline oil. The treatment complex included daily infusion therapy (crystalloid and colloid solutions, potassium polarizing mixture, according to indications – parenteral feeding preparations), Diavetol 15-20 mg/kg (by dry substance), Emoxipine 1,5-2,5 mg/kg, Pentoxifylline 0,2% solution 200-400 ml/day and Reamberin 400-800 ml/day (or Cytoflavin 10 ml solution in 100 ml 0,9% solution of sodium chloride). The latter enabled to reach clinical and metabolic compensation and restoration of motor and evacuating function of the digestive tract in 90% cases within 2-3 days. All the patients started receiving enteral dietary feeding.

After 4-5 days without discharging the patient from the in-patient department in the state of clinical and metabolic compensation radical operation with primary restoration of digestive tract continuity was performed (only in 1 patient aged 83 tumour recanalization became ultimate symptomatic operation due to the severity of background pathology with cardiovascular function decompensation against the background

of CHD, postinfarction major atherosclerosis with circulatory insufficiency 2A, aneurysm of ascending aorta, arterial hypertension 3 risk 4). In this group of patients sigmoid colon resection, low anterior rectal resection, left hemicolectomy with primary digestive tract continuity restoration by means of circular mechanic suture were made as radical interventions. The postoperative period was uneventful. All the patients were discharged from the in-patient department in the satisfactory state for rehabilitation under out-patient conditions. The mean bed day (subject to the first stage of treatment) was  $17,3 \pm 6,72$ .

Thus, the first experience of application of new tactical approach in surgical treatment of colorectal cancer complicated with intestinal obstruction by means of self-expanding silicone covered  $\pi$  stent (CHOOSTENT M.I.Tech, South Korea [CY]) and laser vaporization following radical operation performance with primary anastomosis placement allows to suggest the efficacy of radical complex treatment based on “rapid recovery” (“Fast-Track Recovery”) concept.

**Conclusions.** Using endoscopic placement of self-expanding metallic colorectal stent and laser vaporization enables to perform early antegrade decompression of the digestive tract with rapid restoration of its motor and evacuating function and early clinical and metabolic compensation (without laparotomy and intestinal fistula formation) in obstructing colorectal cancer complicated with intestinal obstruction. The given approach allows efficient preparation of the patient for radical surgical treatment following primary and radical intervention. Significant decrease in patients hospital stay duration, no need for further surgical rehabilitation (in colostomy performance), high economic and social effect of “rapid recovery” concept use (due to saving financial expenses for treatment and rehabilitation, as well as earlier restoration of optimal life quality) make it possible to recommend wider application of surgical and oncological profile in the in-patient departments.

Laser recanalization of tumour allows successful realization of “Fast-Track Recovery” concept basic principles, which in combination with radical surgical treatment and primary digestive tract continuity restoration decreases patients’ hospital stay duration significantly, obviates the need for further surgical rehabilitation under colostomy. It contributes to sufficient economic and social effect (at the expense of hospitalization duration shortening, postoperative complications frequency decrease, disability incidence decline, exclusion of repeated surgical treatment as well as much earlier restoration of optimal life quality of the patients).

## REFERENCES

1. Comparison of uncovered stent with covered stent for treatment of malignant colorectal obstruction / K.M. Lee, S.J. Shin, J.C. Hwang [et al.] // *Gastrointest. Endosc.* — 2007. — Vol. 66. — P. 931 — 936.
2. Davidson R. Endoluminal stenting for benign colonic obstruction / R. Davidson, W.B. Sweeney // *Surg. Endoscopic.* — 1998. — Vol. 12. — P. 353 — 354.

3. Der Stellenwert minimal-invasiver Operationstechniken im Fast-track-Konzept für die Gefäßmedizin / A. Ivoghlі, P. Kruska, T. Kerner [et al.] // *Gefäßchirurgie*. — 2010. — Vol. 15, № 3. — P. 176 — 182.
4. Dunlop M. Colorectal cancer / M. Dunlop // *Br. Med. J.* — 1997. — Vol. 314. — P. 1882 — 1885.
5. Guillem J. Surgical treatment of colorectal cancer / J. Guillem, P. Philip, A. Cohen // *CA Cancer J. Clin.* — 1997. — Vol. 47, № 2. — P. 113—128.
6. Kehlet H. Evidence-Based Surgical Care and the Evolution of Fast-Track Surgery / H. Kehlet, D.W. Wilmore // *Annals of Surgery*. — 2008. — Vol. 248, № 2. — P.189—198.
7. Parkin D.M. Global cancer statistics / D.M. Parkin, P. Pisani, J. Ferlay // *Ca.* — 1999. — P. 49—33.

В.Л. ДЕНИСЕНКО

*Друга Вітебська обласна клінічна лікарня, Білоруська медична академія післядипломної освіти, Вітебськ, Республіка Білорусь*

#### КОМПЛЕКСНЕ ЛІКУВАННЯ РАКУ ПРЯМОЇ КИШКИ, УСКЛАДНЕНОГО КИШКОВОЮ НЕПРОХІДНІСТЮ

У хірургії (в тому числі й в онкології) стає актуальним напрямком комплексного лікування, що спирається на концепцію «швидкого (прискореного) одужання» (так званий «Fast-Track Recovery» або «Fast-Track Surgery»). Він заснований на застосуванні сучасних високотехнологічних підходів при лікуванні стенозуючого колоректального раку, ускладненого кишковою непрохідністю, включає ефективне використання на першому етапі ендоскопічного стентування (саморозширюючого вкритого силіконом нітілового стенту, що каркасно збільшує просвіт кишки в зоні пухлинного стенозу (CHOOSTENT M. I. Tech, Південна Корея [СУ]), на другому етапі – виконання радикальної операції в рамках однієї госпіталізації. Даний підхід дозволяє виключити проміжні етапи, істотно зменшити загальні терміни лікування та реабілітації пацієнтів, досягти в найближчому і віддаленому періоді високої якості життя пацієнта. У практичній охороні здоров'я Республіки Білорусь цей напрям лише починає набирати силу, вказуючи на позитивні моменти та перспективи використання, що дозволяють істотно поліпшити якісні й кількісні показники лікування найрізноманітніших захворювань.

**Ключові слова:** стентування, лазерна вапоризація, колоректальний рак, реканалізація пухлини

**Стаття надійшла до редакції: 10.06.2014 р.**