



Ukrainian Journal of Nephrology and Dialysis

Scientific and Practical, Medical Journal

Founders:

- State Institution «Institute of Nephrology NAMS of Ukraine»
- National Kidney Foundation of Ukraine

ISSN 2304-0238;
eISSN 2616-7352

Journal homepage: <https://ukrjnd.com.ua>

Clinical Case Report

Nihat M Hokenek¹, Mehmet O Erdogan², Davut Tekyol³, Hakan Hançer⁴, Ergul A Kozan¹, Ummahan Dalkilinc Hokenek⁵

doi: 10.31450/ukrjnd.4(64).2019.02

Management of cardiac tamponade due to contrast nephropathy: A case report

¹Department of Emergency Medicine, University of Health Sciences, Kartal Dr. Lütfi Kırdar Training and Research Hospital, İstanbul, Turkey

²Department of Emergency Medicine, University of Bahçeşehir, Göztepe Medical Park Hospital, İstanbul, Turkey

³Department of Emergency Medicine, University of Health Sciences, Haydarpaşa Numune Training and Research Hospital, İstanbul, Turkey

⁴Department of Cardiovascular Surgery, Kartal Koşuyolu High Speciality Educational and Research Hospital

⁵Department of Anesthesiology and Reanimation, University of Health Sciences, Kartal Dr. Lütfi Kırdar Training and Research Hospital, İstanbul, Turkey

Citation:

Nihat M Hokenek, Mehmet O Erdogan, Davut Tekyol, Hakan Hançer, Ergul A Kozan, Ummahan Dalkilinc Hokenek. Management of cardiac tamponade due to contrast nephropathy: A case report. Ukr J Nephrol Dial. 2019;4(64):11-14. doi: 10.31450/ukrjnd.4(64).2019.02

Abstract. *Pericardial effusion secondary to contrast nephropathy is a very rare clinical condition. Patients have a volume load increase secondary to acute renal failure. In such a case, the progression of pericardial effusion with tamponade may follow a very rapid course contrary to what is believed.*

In this case, a 78-year-old male patient with diabetes mellitus and hypertension was admitted to the emergency department with complaints of decreased urine output, nausea, and vomiting. The patient was diagnosed with acute renal failure secondary to contrast nephropathy. Pericardial effusion amount was found to be 2 cm by thorax tomography.

As the patient who had no urine output when his vital signs were stable became unstable during dialysis preparation and manifested clinical symptoms of cardiac tamponade, immediate pericardiocentesis was performed. Following that, he became stable and was transferred to the intensive care unit. In current guidelines regarding indications for pericardiocentesis, it is stated that drainage should be performed when the amount of effusion is more than 2 cm in the absence of tamponade, suspected bacterial infection or neoplastic etiology. However, in contrast to the standard approach to patients with acute renal failure, our suggestion is that the indications for pericardiocentesis may be broader in the presence of pericardial effusion.

Keywords: *cardiac tamponade, contrast nephropathy, case report.*

Conflict of interest statement: all the authors declared no competing interests.

© Nihat M Hökenek, Mehmet O Erdogan, Davut Tekyol, Hakan Hançer, Ergul A Kozan, Ummahan Dalkilinc Hokenek, 2019. All rights reserved.

Correspondence should be addressed to Nihat Müjdat Hökenek: [nihathokenek@gmail.com](mailto:nihat_hokenek@gmail.com)

Article history:

Received October 26, 2019

Received in revised form
November 02, 2019

Accepted November 10, 2019



© Ніхат М. Хокенек, Мехмет О Ердоган, Давут Текіол, Хакан Ганчер, Ергул А. Козан, Уммахан Далкілінк Хокенек, 2019

УДК: 616.61-008.6:616.12-08

Ніхат М. Хокенек¹, Мехмет О Ердоган², Давут Текіол³, Хакан Ганчер⁴,
Ергул А. Козан¹, Уммахан Далкілінк Хокенек⁵

Лікування тампонади серця унаслідок контрастної нефропатії: клінічний випадок

¹Кафедра невідкладної медицини університету медичних наук,
Kartal Dr. Lütfi Kırdar госпіталь, Стамбул, Туреччина

²Кафедра невідкладної медицини університету Bahçeşehir, медичний центр Göztepe, Стамбул, Туреччина

³Кафедра невідкладної медицини університету медичних наук, Numune Haydarpaşa госпіталь,
Стамбул, Туреччина

⁴Кафедра серцево-судинної хірургії спеціалізованого навчально-дослідного госпіталю Kartal Koşuyolu,
Стамбул, Туреччина

⁵Кафедра анестезіології та реанімації університету медичних наук, Kartal Dr. Lütfi Kırdar госпіталь,
Стамбул, Туреччина

Резюме. Перикардіальний випіт на фоні контрастної нефропатії є дуже рідкісним клінічним станом.

До відділення невідкладної допомоги було прийнято 78-річного пацієнта із цукровим діабетом та гіпертонічною хворобою зі скаргами на зменшення сечовиділення, нудоту та блювоту. У пацієнта діагностували гостру ниркову недостатність та перикардіальний випіт близько 2 см за допомогою томографії грудної клітини.

Пацієнту розпочато лікування гемодіалізом, але у зв'язку з маніфестацією клінічних симптомів тампонади серця, йому було негайно проведено перикардіоцентез. Загалом, сучасні настанови рекомендують застосування перикардіоцентезу лише у разі наявності більше 2 см перикардіального випоту та за відсутності тампонади, підозри на бактеріальну інфекцію або неопластичну етіологію. Однак, на відміну від стандартного підходу, ми припускаємо необхідність розширення показань до перикардіоцентезу у пацієнтів з гострою нирковою недостатністю.

Ключові слова: серцева тампонада, контрастна нефропатія, клінічний випадок.

Introduction. Contrast-enhanced tomography is increasingly used in relation to differential diagnosis in emergency departments [1]. Contrast agents are used to improving image quality and perform target-directed screening in patients who had computed tomography scans (CT). Contrast-induced nephropathy is an important side effect. It is defined as an increase in serum creatinine by 25% or 44 mmol/L within 48-72 hours after exposure [2]. It develops in approximately 6% of patients who had contrast computed tomography scans [3]. Pericardial effusion is an important predictor of mortality in a patient who developed acute renal failure [4].

In this case, our objective was to evaluate the applications of pericardiocentesis in a patient who developed pericardial effusion secondary to acute renal failure followed by cardiac tamponade.

Case report. A 78-year-old male patient with hypertension and diabetes mellitus, who use amlodipine and metformin, presented to the emergency department

with a chest complaint, abdominal pain, and decreased urine output. It was found out that the patient was admitted to the emergency department with chest pain 5 days earlier and a thoracic contrast-enhanced computed tomography scan had been done during the etiology investigation. This CT scan had shown no pericardial effusion (figure 1), and the patient on his arrival had been determined to have GCS of 15 with TA: 110/60, pulse:110, and Sato 2:94.

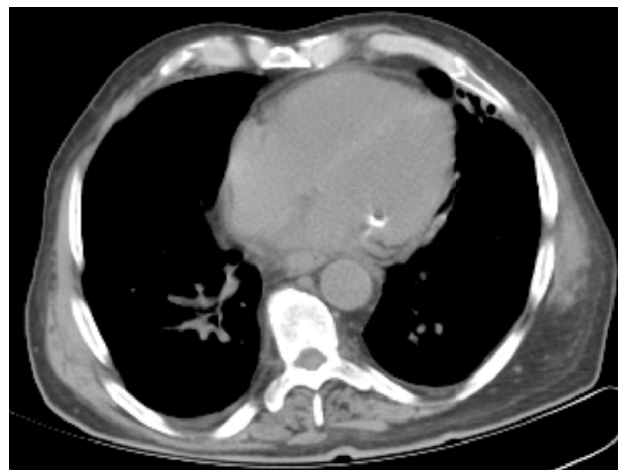


Fig. 1. The thoracic contrast-enhanced CT scan of the patient.

Nihat Müjdat Hökenek
nihathokenek@gmail.com

Biochemical examinations of the patient revealed a creatinine level of 4.16 mg/dL, urea level of 94 mg/dL, albumin level of 27 g/L. As a sign of deep metabolic acidosis, blood gas pH value was found out 7.17. 5 days earlier, the creatinine and urea levels of the patient on his arrival had been 1.01 mg/dL and 41 mg/dL.

Having seen that the patient had no urine output during follow-up, contrast nephropathy was accepted due to his history of 5 days earlier. With the patient having chest pain, physical examination revealed bibasilar crackles in respiratory sounds. Moreover, heart sounds were heard deeply during cardiac auscultation. In the emergency department, a non-contrast thoracic computed tomography scan was performed to the patient who had an increased cardiothoracic index as it was seen by portable chest X-ray. 2 cm of pericardial effusion was detected in his CT scan (figure 2).

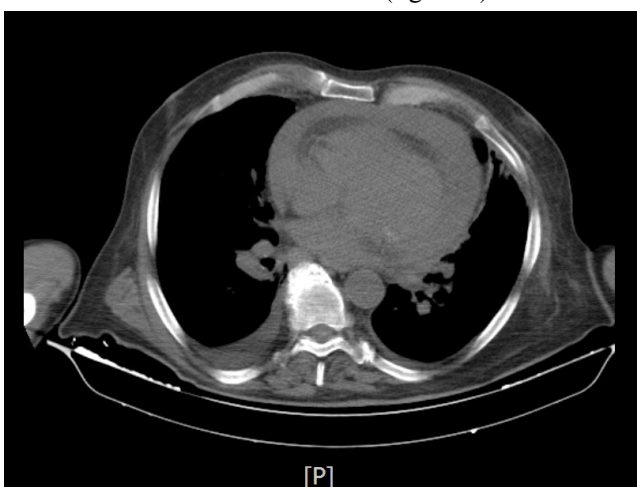

Fig. 2. The second non-contrast CT scan of the patient.

Clinical tamponade was not considered for the patient whose vital signs were stable at that time. The patient was evaluated in favor of uremic pericarditis, and hemodialysis was planned rather than pericardiocentesis. Immediate pericardiocentesis was performed to the patient whose general conditions deteriorated and who became unstable during follow-up in the emergency department (TA: 80/40, pulse: 145, SS: 25). Approximately 400 mL of serohemorrhagic fluid was drained from the patient by ultrasound-guided subxiphoid approach.

He was dialyzed and followed up daily with echocardiography, urea, creatinine and electrolytes. On the first day of follow-up, the levels of creatinine and urea were observed as 4.62 mg/dL and 90.42 mg/dL. On the fifth day of the treatment, the creatinine and urea levels of the patient were 1.4 mg/dL and 98 mg/dL, while echocardiograms showed no pericardial effusion. No growth was observed in the pericardial fluid culture. The patient was diagnosed with uremic pericarditis caused by acute renal failure secondary to contrast nephropathy.

Discussion. Acute renal failure is characterized by a sudden decrease in renal functions. While creatinine increase in contrast nephropathy usually starts within 24 to 48 hours of contrast exposure, creatinine levels

begin to decrease within 3 to 7 days [5]. Diagnosis is made by clinical presentation and exclusion of other causes of acute renal failure because drugs can also make it. In this case, our diagnosis was supported due to the fact that the patient was diabetic, he had received a contrast agent on his first arrival of 5 days earlier, he had no history of any renal disease, the levels of urea and creatinine in his previous records had been always within the reference range, and there was no history of nephrotoxic agent intake.

Although pericardial effusion is generally seen in patients with chronic renal failure or genetic diseases, pericardial effusion is very rare in patients with acute renal failure [6]. This condition is very mortal in patients with acute renal failure. Patients with chronic renal failure are more likely to develop chronic pericardial effusion due to a volume load increase [7]. The incidence of patients with acute renal failure who receive dialysis treatment has decreased to approximately 5% [7].

Algorithmic approaches to pericardial effusion generally recommend that pericardial drainage should be performed when clinical tamponade becomes available [8]. Especially in one of the written algorithms, it is stated that drainage should be performed when the amount of effusion is more than 2 cm in the absence of tamponade, suspected bacterial infection or neoplastic etiology [8]. However, there is no specific recommendation for acute pericardial effusion that develops in patients with acute renal failure. Therefore just like other emergency diagnoses, acute renal failure also needs to have alternative methods to understand and manage [9].

It should be kept in mind that pericardial effusion secondary to acute renal failure may cause a clinical tamponade by showing a rapid and aggressive course. This can be a surprising and new condition for clinician such as drug side effects [10]. Especially in cases such as ours, the indications of pericardiocentesis may be considered widely in the presence of pericardial effusion accompanied by acute renal failure. Although pericardiocentesis is recommended when tamponade occurs clinically, it may be beneficial to consider pericardiocentesis when the patient is stable, due to the fact that pericardial effusions associated with acute renal failure can rapidly become unstable. If a radiological effusion is present in patients with acute pericarditis, pericardiocentesis may decrease the mortality of the patient.

Conclusion. Pericardial effusion can rapidly become life-threatening in patients with acute renal failure. Emergency pericardiocentesis before RRT may reduce mortality in the presence of radiological cardiac effusion, even if no cardiac tamponade occurs clinically.

Conflict of interest statement. The authors declare no conflict of interest.

Authors contribution.

Nihat M Hokenek: constructing the hypothesis of the research, planning methodology to reach the conclusions, organizing and taking the responsibility of the study.

Mehmet O Erdogan: constructing the hypothesis of the research, planning methodology to reach the conclusions, interpretation and conclusion of the results.

Ummahan Dalkilinc Hokenek: organizing and taking the responsibility of the study, collection of relevant biological materials, data management, and reporting.

Ergul A Kozan: taking responsibility in patient's follow-up, collection of relevant biological materials, data management, and reporting

Davut Tekyol: a literature review for the study, scientifically besides spelling and grammar.

Hakan Hançer: a literature review for the study, scientifically besides spelling and grammar.

References:

1. Larson DB, Johnson LW, Schnell BM, Salisbury SR, Forman HP. National trends in CT use in the emergency department: 1995–2007. *Radiology*. 2011;258(1):164-73. doi: 10.1148/radiol.10100640.
2. Morcos S, Thomsen H, Webb J. Contrast-media-induced nephrotoxicity: a consensus report. *European radiology*. 1999;9(8):1602-13. doi: 10.1007/s003300050894.
3. Kooiman J, Pasha SM, Zondag W, Sijpkens YW, van der Molen AJ, Huisman MV, et al. Meta-analysis: serum creatinine changes following contrast enhanced CT imaging. *European Journal of Radiology*. 2012;81(10):2554-61. doi: 10.1016/j.ejrad.2011.11.020.
4. Rudnick MR, Tumlin J. Pathogenesis, clinical features, and diagnosis of contrast-induced nephropathy [Internet]. Up-to-Date Web site. Available from: <https://www.uptodate.com/contents/pathogenesis-clinical-features-and-diagnosis-of-contrast-induced-acute-kidney-injury/print>
5. Ullah W, Roomi S, Sattar Z, Ahmad A, Ali Z, Sarwar U, Figueredo V. Acupuncture related acute purulent pericarditis masquerading uremic pericarditis. *J Community Hosp Intern Med Perspect*. 2019 Jun 19;9(3):230-234. doi: 10.1080/20009666.2019.1622380.
6. Alpert MA, Ravenscraft MD. Pericardial involvement in end-stage renal disease. *The American journal of the medical sciences*. 2003;325(4):228-36. doi: 10.1097/00000441-200304000-00009.
7. Bataille S, Brunet P, Decourt A, Bonnet G, Loundou A, Berland Y, et al. Pericarditis in uremic patients: serum albumin and size of pericardial effusion predict drainage necessity. *Journal of nephrology*. 2015;28(1):97-104. doi: 10.1007/s40620-014-0107-7.
8. Adler Y, Charron P, Imazio M, Badano L, Barón-Esquivias G, Bogaert J, et al. 2015 ESC Guidelines for the diagnosis and management of pericardial diseases: the Task Force for the Diagnosis and Management of Pericardial Diseases of the European Society of Cardiology (ESC) Endorsed by: The European Association for Cardio-Thoracic Surgery (EACTS). *European Heart Journal*. 2015;36(42):2921-64. doi: 10.1093/eurheartj/ehv318.
9. Colak S, Erdogan MO, Sekban H, Afacan MA, Uras AR, Ibrahim A, et al. Emergency diagnosis of upper gastrointestinal bleeding by detection of haemoglobin in nasogastric aspirate. *Journal of International Medical Research*. 2013;41(6):1825-9. doi: 10.1177/0300060513505516.
10. Colak S, Erdogan MO, Afacan MA, Kosargelir M, Aktas S, Tayfur İ, et al. Neuropsychiatric side effects due to a transdermal fentanyl patch: hallucinations. *The American journal of emergency medicine*. 2015;33(3):477.e1-e2. doi: 10.1016/j.ajem.2014.08.051.