

## CLINICAL COURSE OF MYOCARDITIS IN INFECTIOUS MONONUCLEOSIS IN ADULTS

*M. F. Shustval<sup>1</sup>, T. I. Lyadova<sup>2</sup>, O. V. Volobueva<sup>2</sup>*

<sup>1</sup> Kharkiv Medical Academy of Postgraduate Education, Kharkiv, Ukraine

<sup>2</sup> V. N. Karazin Kharkiv National University, Ukraine

---

In conducting of complex examination (clinical, laboratory, virological, instrumental) of 186 patients with infectious mononucleosis acute myocarditis was diagnosed in 50 (26,9 %) cases. In 10 % of patients myocarditis was asymptomatic but the clinical picture was veiled by primary infectious process. Drug treatment of viral myocarditis of infectious mononucleosis must include antiviral drugs (acyclovir), drugs that affect the inflammatory, autoimmune and allergic processes, restoration and maintenance of hemodynamic, metabolic drugs, symptomatic therapy.

**KEY WORDS:** infectious mononucleosis, Epstein-Barr virus, myocarditis, diagnostic, treatment, acyclovir

### КАРДІАЛЬНІ УСКЛАДНЕННЯ ПРИ ІНФЕКЦІЙНОМУ МОНОНУКЛЕОЗІ У ДОРОСЛИХ

*М. Ф. Шустваль<sup>1</sup>, Т. І. Лядова<sup>2</sup>, О. В. Волобуєва<sup>2</sup>*

<sup>1</sup> Харківська медична академія післядипломної освіти, Харків, Україна

<sup>2</sup> Харківський національний університет імені В. Н. Каразіна, Україна

---

При проведенні комплексного обстеження (клінічного, лабораторного, вірусологічного, інструментального) 186 хворих на інфекційний мононуклеоз гострий міокардит діагностовано у 50 (26,9 %) випадків. У 10 % хворих міокардит перебігав безсимптомно, клінічна картина була завуальована первинним інфекційним процесом. Медикаментозна терапія міокардиту при інфекційному мононуклеозі повинна включати противірусні препарати (ацикловір), препарати, що впливають на запальні, автоімунні та алергічні процеси, відновлення та підтримання гемодинаміки, метаболічні препарати, симптоматичну терапію.

**КЛЮЧОВІ СЛОВА:** інфекційний мононуклеоз, міокардит, діагностика, лікування, вірус Епштейна-Барр, ацикловір

### КЛИНИЧЕСКОЕ ТЕЧЕНИЕ МИОКАРДИТА ПРИ ИНФЕКЦИОННОМ МОНОНУКЛЕОЗЕ У ВЗРОСЛЫХ

*Н. Ф. Шустваль<sup>1</sup>, Т. И. Лядова<sup>2</sup>, О. В. Волобуева<sup>2</sup>*

<sup>1</sup> Харьковская медицинская академия последипломного образования, Харьков, Украина

<sup>2</sup> Харьковский национальный университет имени В. Н. Каразина, Украина

---

При проведении комплексного обследования (клинического, лабораторного, вирусологического, инструментального) 186 больных инфекционным мононуклеозом, острый миокардит диагностирован в 50 (26,9 %) случаев. У 10 % больных миокардит протекал бессимптомно, клиническая картина была завуалирована первичным инфекционным процессом. Медикаментозное лечение миокардита при инфекционном мононуклеозе должно включать противовирусные препараты (ацикловир), препараты, оказывающие влияние на воспалительные, аутоиммунные и аллергические процессы, восстановление и поддержание гемодинамики, воздействующие на метаболизм миокарда, симптоматическую терапию.

**КЛЮЧЕВЫЕ СЛОВА:** инфекционный мононуклеоз, вирус Эпштейна-Барр, миокардит, диагностика, лечение, ацикловир

## INTRODUCTION

Infection caused by human herpes virus Type 4 (HHV-4) or Epstein-Barr virus (EBV) takes an important place in the structure of infectious diseases of herpesvirus etiology. It is considered that from 40 to 70 % of population of various regions of the planet are EBV infected. Infectious mononucleosis (IM) is the most wide-spread infant disease which is more often diagnosed among adult population lately. Manifest forms of IM are usually clinically manifested by the triad of symptoms: fever, lymphadenopathy and tonsillitis with further affection of immune system which is characterized by long-term persistence of the virus in B-lymphocytes [1-2].

In clinical practice such forms of IM are met in which among the mentioned triad other clinical manifestations are possible, which are connected with heart affection: myo-, endo- or pericardites; central and periphery nervous system: meningites, meningoencephalites, mono- or polyradiculoneurites; kidneys: nephrites; grandular organs: pancreatitis or orchites, etc [3-4].

Affection of the heart muscle in IM is studied insufficiently and up to now it was considered that myocardites in patients with IM rarely develop. Though according to T.V. Tolsticova et al. [5], in examination of 47 children with IM acute myocarditis was diagnosed in 12,5 %, endocarditis – in 2,4 %, infectious coronaritis – in 37,5%, Kawasaki disease in 17,5 % of patients.

E. Stephen et al. [6] diagnosed the myocardites development in 32 % of patients with IM with typical and atypical form of the disease course. Other authors consider that heart affection can appear only in severe course of IM and can be the fatal course in the given category of the patients [7-9].

It should be mentioned that diagnostics of reactivated, latent and chronic forms of EBV-infection in clinical practice according to clinical signs as it is widely used in infections caused by herpesvirus representatives takes place not in the right time, as it is necessary to conduct modern laboratory tests for diagnosis verification which are inaccessible for many medical establishments of Ukraine. As present data of complicated IM forms frequency development with heart affection were described mostly in children, the aim of our research is the study of development frequency, clinical

course peculiarities and treatment of acute myocardites in adults with IM.

## OBJECTIVE

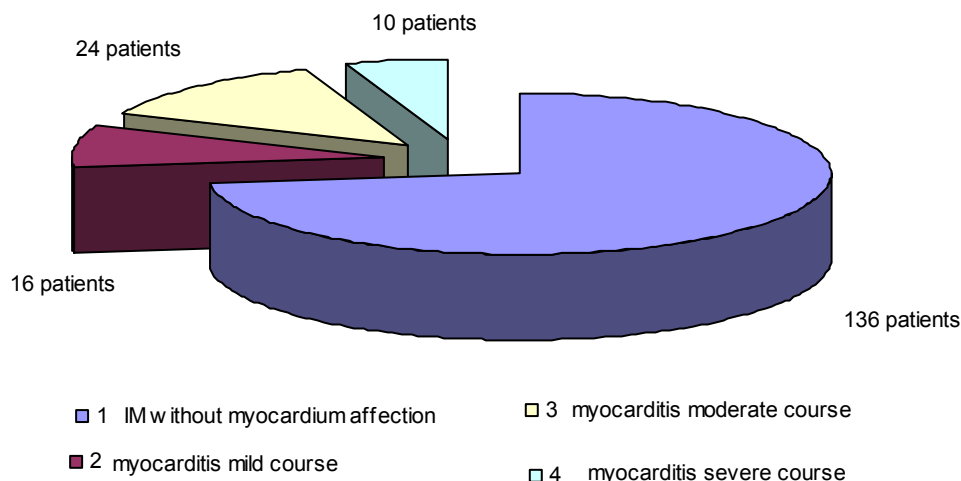
Aim of the research is diagnostics and study of development frequency, clinical course peculiarities and treatment of acute myocardites in adults with IM.

## MATERIALS AND METHODS

186 patients with IM at the age from 18 to 32 (81 women and 75 men) were examined, among which in 50 (26,9 %) cases acute myocarditis was diagnosed. In this category of the patients mild form of myocarditis was diagnosed in 16 (32 %), moderate form – in 24 (48 %), severe form – in 10 (20 %) patients (fig.). According to N.D.Strazhesko and V.H.Vasilenko classification I-st stage blood circulation insufficiency was found in 25 (50 %), II «A» stage – in 8 (16 %) cases. Sorting of the patients was incidental, examination was carried out in acute period of the disease and in dynamics in process of recovery.

Complex of patients examination included clinical blood analysis, revelation of atypical mononuclears, definition of specific Ig to EBV in the way of immune-enzyme analysis (IEA), revelation of DNA by polymerase chain reaction (PCR), asparaginic and alanine transaminase activity (AsAT, AlAT), lactate dehydrogenase (LDG) and creatin-phosphatkinase (CPhK) and its MB-fraction (MB-CPhK), content of C-reactive protein (CP), tropine-I, seromuroids and fibrinogen in blood. Registration of electrocardiogram (ECG) in 12 standard abductions, heart ultrasound research (Echo-CG) and roentgenological study of thorax were carried out.

Statistic processing of the research results was carried out with the use of Statistika 6.0 for Windows (Stat Soft Inc, USA) program on personal computer with Pentium II Celeron 850 PPGA processor. Arithmetic mean (M), average quadratic deviation ( $\sigma$ ), average error of average arithmetic mean (m) were calculated for each variation row. Estimation of average quantities differences probability (p) was carried out with the help of Student-Fisher criterion (t). Disagreement was considered reliable under  $p < 0,05$  meaning. The data of the results got during the examination of this category of patients are presented in the article in the way of absolute and relative meanings.



**Fig. Frequency of myocarditis occurrence in IM patients**

**RESULTS AND DISCUSSION**

In the first days of IM the patients complained about general feebleness, headache, myalgiae, arthralgiae, ache in throat while swallowing, excessive sweating, rise of temperature to 38-39,5°C which kept for 1-3 weeks and sometimes longer. Typical changes being characteristic features of IM were found in clinical blood analysis: moderate hypochromic anemia. In the first 2-3 days of the disease leucopenia was marked which further was replaced by leukocytosis (9-15 x 10<sup>9</sup>/l). Content of uninuclear elements (lympho- и monocytosis) grew sufficiently and reached 50-80 % from the general number of leukocytes. The characteristic feature of IM was the presence of atypical mononuclears in blood (20 % and more) the appearance of which is typical on the 2-3 day of IM. Duration of atypical mononuclears preservation comprises in average 2-3 weeks, sometimes up to 2 months. ESR in the mentioned category of patients remained normal.

In all patients with IM EBV DNA was found in saliva and blood by PCR-method and specific immunoglobulins VCA-IgM, EA-IgG by IFA method.

In most patients with IM myocarditis developed during the first week of the disease and rarely occurred on 2-3 week. Thus, myocarditis clinical picture depended on the level of myocardium affection varying from not symptomatic course to expressed level of cardio-vascular insufficiency.

As our investigation showed among all complains of the patients with IM the complains on heart pain, dyspnea and accelerated cardiopalmus dominated under myocarditis development. Painful sensations (cardialgiae) of nagging or stablign character were found in 43 (86 %) patients and had undefined duration. Thus pain irradiation, legible connection between physical and psychoemotional tension were absent, pain was seldom cut short by nitroglycerin taking. Only in 6 patients (12 %) heart pain was cut short by sublingual taking of nitroglycerin. The latest incident is connected with the fact that a great role can belong to vascular component in mechanisms of pain appearance, which is connected with endothelium dysfunction and vasculitis development [8-10].

Complains on dyspnea at ward and tiny physical loading were marked in 23 patients (46 %). Dyspnea was often subjective and was not considered the cause of blood circulation insufficiency, respiratory rate in this case did not practically change, saturation of arterial blood by oxygen was normal.

Acceleration of cardiopalmus was the complain in 31 (62 %) cases, intermissions in heart activity were marked in 10 patients (20 %) which appeared while walking or changing the body position. 12 (24 %) patients with blood circulation of II «A» stage complained on tiny edemae of feet and ankles.

It should be mentioned that in 10 patients (20 %) the mentioned above complains were absent, and myocarditis was diagnosed during

clinical, electrocardiographic and ultrasound examination. Atypical complains of the patients with myocarditis connected with endured IM included: sweating, quick fatigability, general asthenia, sleepiness, headache, vertigo, mialgiae and arthralgiae.

Under physical examination tachycardia was found in 35 (70 %) patients, bradycardia – in 5 (10 %) and in other 10 (20 %) cases heart rate frequency was normal, heart rhythm disorders were registered in 15 patients (30 %). In patients with acute myocarditis pulse rate did not correspond the increase of temperature and remained increased both in ward and in loading. Propensity to arterial hypotonia was found in 18 (36 %) patients, thus arterial pressure data depended on the level of myocardium affection and periphery compensatory mechanisms activity. Under severe myocardium affection decrease of systolic and increase of diastolic arterial pressure were found. Under mild and intermediate myocarditis in most of the patients systolic and diastolic AP were normal.

Heart dilatation in particular on account of the left ventricle was found in 25 (50 %) patients with acute myocarditis. Heart intensity dilatation depended on the level of heart muscle affection and suffered reverse development in process of the patients recovery.

Auscultative heart changes under myocarditis are of permanent importance in physical examination of the patient, though differ in sufficient polymorphism. Level of these changes sufficiently depended on the process stage and severity of heart muscle affection. Muting of heart tones was usually observed in combination with pathological tones (III and IV) appearance in presence of sufficient myocardium changes and formation of, correspondingly, protodiastolic gallop rhyme and presystolic gallop rhyme. In some patients pendulum-like rhyme was defined. Weakening of the I tone and listening of the systolic noise over the apex were important symptoms of the heart muscle affection. Noise, as a rule, had weak intensity, it began immediately after the I tone, decreased in the direction to the I tone and led to the left axillary region. Regurgitation of blood into the cavity of the left auricle stipulated for the weakness of papillary muscles and prolapse of mitral valve folds is on the basis of the mentioned systolic noise.

The character of heart auscultative manifestations considerably depended on adhe-

rence of rhyme disorders and conductivity. Sometimes under associated pericardium affection the noise of pericardium friction was listened.

All mentioned subjective and objective clinical symptoms of acute myocarditis in patients with IM can mix stipulating different clinical picture. In most cases the patient does not have all symptoms described above and the clinical picture of myocarditis is defined by only some of them.

Estimation of clinical symptoms of acute myocarditis in patients with IM is made more difficult by simultaneous presence of the main infectious disease symptoms. In this connection it is often difficult to say which complains are stipulated for the main disease and which of them are connected with myocarditis, that is why laboratory and instrumental methods of investigation are widely used in myocarditis diagnostics.

Laboratory diagnostics of myocardium affections supposes the study of cardiospecific enzymes level in blood serum (MB fraction, CPhK, AsAT, LDH). Thus it was shown in some studies that activity of the mentioned enzymes authentically exceeds normal indices in less than 10% of patients in acute period of intermediate form of myocarditis [1-2, 10], which is also proved by the results of our research. So, MB-CPhK activity was increased in 7 (14 %) patients, AsAT – in 20 (40 %), LDH-1 – in 10 (20%). Increase of CRP was observed in 15 (30 %) cases, seromuroid – in 13 (25 %), fibrinogen – in 15 (30 %), tropine-I – in 5 (10 %) patients. However increase of LDH-1 and AsAT activity, content of CRP in blood, seromuroid, fibrinogen are atypical and can be stipulated for IM, intoxication, various affections of skeletal muscles, liver, lungs, kidneys, etc., which limits the use of these tests in myocarditis diagnostics under IM.

Hematological changes in patients with IM do not also reflect dynamics of the changes observed in myocardium, that is why we made an attempt to study diagnostic possibilities of instrumental research methods (ECG, Echo-CG, heart roentgenography) in myocardites detection in patients with IM.

Analysis of the received data showed that atypical ECG changes are detected in 96 % (48 patients) with infectious myocardities. Especially valuable information can be received while observing ECG dynamics. Changes of repolarization of ventricles

processes; depression or increase of RS-T segment in standard and thoracic abductions, appearance of lowered, smoothed or negative T wave in thoracic and (or) standard abductions; conductivity violations, including elongation of electric systole of ventricles (QT interval), sino-atrial, atrioventricular blockade of various extent, intraauricular and intraventricular conductivity violations, bundle of His stems blockade; various heart rhythm violations, such as sinuses tachycardia and more seldom sinuses bradycardia, pacemaker migration, auricle and ventricular extrasystole, auricle or nodal tachycardia are commonly registered. In myocarditis complicated by fibrinous pericarditis concordant increase of S-T segment in abductions was detected where R wave is dominating; in diffuse extended myocarditis decrease of R wave voltage took place and in rare cases pathological Q-wave was registered.

During treatment while clinical improvement appears ECG changes were subjected to reverse development and came to norm in most of the patients. Low voltage of R-waves remained for a long time and heart rhythm and conductivity violations were registered.

It should be mentioned that heart rhythm and conductivity violation in separate cases of tiny symptomatic myocarditis can be the only markers of pathological process in heart muscle and demand special attention both in acute period of the disease and in the period of convalescence.

During echocardiographic research (Echo-CG) the following changes are detected in patients with acute myocarditis:

- increase of heart cavities size in 20 (40 %) patients;
- increase of left ventricle wall thickness at the expense of its edema in 20 (40 %) patients;
- decrease of emission fraction less than 50 % in 8 (16 %) patients;
- prolaps of mitral valve – in 15 (30 %) patients;
- hypokinesia zone of myocardium various segments were found in 6 (12 %) patients.

In symptomless and tiny symptomatic myocarditis Echo-CG data were normal, small increase of final diastolic volume (FDV) and final systolic volume (FSV) of the left ventricle were rarely found. In more severe cases accompanied by descent of myocardium contractility decrease of emission fraction less than 50 % and systolic index were detected,

more significant increase of FDV, FSV and left auricle size. Decrease of emission fraction less than 50 % is considered a bad prognostic indication.

Separation of pericardium folium and detection of a small amount of liquid in pericardium cavity found in 6 (12 %) patients prove the development of myocarditis.

Under roentgenological (fluorographic) heart research in 20 (40 %) patients with infectious myocarditis intermediate increase of heart size was found, connected with one or both ventricle cavities widening.

In most patients with myocarditis roentgenological signs of heart chamber dilatation on the background of effective treatment decreased sufficiently or had reverse development.

The results of our study prove that in 50 patients (26,9 %) with IM acute myocarditis can develop, Epstein-Barr virus and opportunistic infection can serve its etiological signs which are connected with humoral immunity violation and active virus replication.

Thus mild course of myocarditis was characterized by the absence of heart growth and cardiac insufficiency manifestations. The course of myocarditis can be symptomless without any subjective manifestations under which heart affection is revealed only during ECG, biochemical (AsAT, MB-CPhK, troponin-I) or ECG research.

Under intermediate course growth of heart dimensions was observed, expressed ECG, Echo-CG and roentgenological changes, symptoms of blood circulation insufficiency were absent or corresponded the I stage.

Cardiomegalia was typical for severe course of myocarditis, rhyme and conductivity disorder, repolarization processes disorder, increase of systolic and diastolic volumes, lowering of emission fraction to 50 % and lower, blood circulation insufficiency of the I and II «A» stage.

At present the following trends are singled out in treatment of acute myocarditis:

- etiotropic therapy;
- pathogenetic;
- symptomatic treatment of complications.

As etiotropic therapy antivirus preparations were used: acyclovir 5-10 mg/kg, intravenous infusions every 8 hours. Pathogenetic therapy included the prescription of anti-inflammatory preparations (ortofen, indometacin, ibuprofen, etc.), desensitizing remedies (loratadin, arius,

claritin), antioxidants (quercetin, ascorbic acid, tocopherol, emoxipin), preparations improving metabolism in myocardium (trime-tazidin, mexicor, corvitan, vazonat, vitamins of B group).

Symptomatic treatment included prescription on reading of antiarrhythmic preparations (nebilet, concor, ethacyzin, propafenone and cordaron); disaggregants (clopidogrel), diuretics (verospiron, gipotiazid, torasemide, etc.).

Duration of staying in bed in mild and intermediate course of myocarditis comprised in average not less than 1-2 weeks, in severe course of myocarditis the duration of staying in bed increased to 2-4 weeks with gradual broadening of the regime under constant control of cardiologist.

The prognosis of the disease depended, first of all, on spreading of heart muscle affection and peculiarities of inflammatory process in myocardium, presence of left ventricle dysfunction and severity of the disease course against the background of which myocarditis develops.

During the conducted complex therapy stable clinical improvement was observed in all patients under study, heart rhythm and conductivity came to normal, parameters of hemodynamics and the condition of electrophysiological processes in myocardium improved, the patients returned to their professional activity or studies.

Duration of the treatment course of the patients with infectious myocarditis depends on the disease severity and effectiveness of the used treatment. According to the data of morphological investigation acute myocardium inflammation in the way of lymphocytic infiltrations lasts from some weeks to some months, its duration on the basis of electrocardiographic changes comprises 1-2 months, according to the laboratory research data – not less than 1 month, according to clinical symptoms – from some weeks to some months [2-3, 5, 11]. It is supposed that inflammatory process in heart muscle

continues after the reverse development and disappearance of myocarditis clinical manifestations coursing further subclinically, transforming gradually into dilated cardiomyopathy [10-12]. Thus long-term treatment courses – from 2 to 6 months and sometimes more prolonged are necessary in treatment of infectious myocarditis. Course of treatment not more than some weeks is surely insufficient. It allows only to eliminate the most acute clinical manifestations, but inflammatory process in heart muscle can last subclinically up to the next aggravation, moreover EBV-infection can transform into chronic active form and support inflammatory process in heart muscle, that is why patients recovering after infectious myocarditis must keep sanitarium supervision of cardiologist and, possibly, infectionists as well, and receive antirecurrent therapy if necessary.

## CONCLUSIONS

1. Acute myocarditis is diagnosed in 26,9 % of patients with infectious mononucleosis caused by Epstein-Barr virus. In 10 % of patients myocarditis can follow its symptomless pattern, the disease clinical picture can be masked by primary infectious process.

2. Clinical, laboratory (LDG-1 activity growth, AsAT, MB-CPhK and tropine-I), ECG, Echo-CG and roengenological research play a great role in myocarditis diagnostics in patients with infectious mononucleosis.

3. In the period of active virus replication conduction of virological and laboratory methods of research are necessary with the aim of infectious process dynamics control and reverse complications development.

4. Drug treatment of myocarditis in patients with infectious mononucleosis must include: antivirus preparations (acyclovir); preparations influencing the inflammatory, autoimmune and allergic reactions, restoration and support of hemodynamic, influence on myocardium metabolism, symptomatic therapy.

## REFERENCES

1. Nikol'skiy I.S. Asotsiyovaniy aktivnoyu khronichnoyu Epshteyna-Barr infektsiyu kliniko-immunologichniy sindrom / I.S. Nikol'skiy, V.D. Yurchenko, K.I. Nikol'skiy // Suchasni infektsii. – 2003. – № 3. – S. 60-62.
2. Markov I.S. Diagnostika i lecheniye gerpeticheskikh infektsiy i toksoplazmoza / I.S. Markov. – K.: «Artek», 2007. – 192 s.

3. Nekoronarogennyye zabolevaniya miokarda / pod red. I.G. Kurenkova. –S.-Pb: «Elbi», 2008. – 237 s.
4. Valgma K. Infektsionnyy miokardit / K. Valgma – Tallin: «Valgus», 1990. – 161 s.
5. Tolstikova T.V. Kardiologicheskiye oslozhneniya pri infektsionnom mononukleoze u detey / T.V. Tolstikova, L.V. Bregel', V.T. Kiklevich, V.M. Subbotin // Sibirskiy meditsinskiy zhurnal. – 2010. – № 5. – S. 33-35.
6. Stephen E. Infection mononucleosis. Complexities of a common syndrome / E. Stephen, M. Yodshall, T. Jeffrey, D.O. Kirchner // Postgraduate medicine. – 2000. – v.107. – № 7. – P. 320-329.
7. Kardiomiopatii i miokardity / P.Kh. Dzhanashev, V.A. Kruglov, B.A. Nazarenko, S.A. Nikolenko – M.: RGMU, 2000. – 107 s.
8. Kuskova T.G. Sostoyaniye serdechno-sosudistoy sistemy pri infektsionnom mononukleoze / T.G. Kuskova, M.I. Rosliy, P.G. Filenkov, T.I. Popova // Zhurnal infektsionnoy patologii. – 1999. – T. 6. – № 1. – S. 13-16.
9. Paleyev N.R. Nekoronarogennyye zabolevaniya miokarda. Sostoyaniye problemy / Paleyev N.R. // Klinicheskaya meditsina. – 1998. – T. 76. – № 9. – S. qA4-9.
10. Feldman A.M. Myocarditis / A.M. Feldman, D. Mc Namara // N. Engl. J. Med. – 2000. – v. 19. – P.1388-1394.
11. Huber S.A. Immunopathogenesis of experimental Coxsackievirus induced myocarditis role of autoimmunity / S.A. Huber, D.C. Zyden, P.A. Zodge // Hezz. – 1995. – v. 10. – №1. – P. 1-7.
12. Pacerschinger M. Enteroviral RNA replication in the myocardium of patients with left ventricular dysfunction and clinically suspected myocarditis / M. Pacerschinger, A. Doerner, U. Kuchl // Circulation. – 1999. – v. 99. – P. 889-893.