

**MORPHOMETRIC CHARACTERISTIC OF RAT SMALL INTESTINE WALL
IN ADMINISTRATION OF CRYOPRESERVED PLACENTA
AND ASEPTIC INFLAMMATION OF PERITONEUM****Higher State Educational Establishment of Ukraine****“Ukrainian Medical Stomatological Academy” (Poltava)****Shepitko73@mail.ru**

The paper is a fragment of the research project, carrying out at the Department of Histology, Cytology and Embryology at Higher State Educational Establishment of Ukraine “Ukrainian Medical Stomatological Academy”, MoH of Ukraine, entitled “Experimental-morphological study of the effect of cryopreserved placenta’s transplants and other exogenous factors onto morpho-functional state of viscera” (State registration number: 0113U006185).

Small intestine pathology is accompanied by chronic inflammatory processes and, consequently, resulting in metabolic disorders, leading to malabsorption syndrome [1]. Considering the fact that such diseases often occur in individuals of working age, treatment of the diseases requires certain material costs, highlighting the social and economic importance of the problem [2].

Clinical symptomatology of various chronic diseases of the small intestine is common and leads to errors in making the correct diagnosis. Major pathophysiological factors of small intestine inflammation are chronic diarrhea, raise of osmotic pressure in the intestine cavity, intestinal hyperexudation, hypersecretion, (exudative enteropathy), accelerated transit of intestinal contents [2]. Pathomorphologically, the pattern of chronic affection of the small intestine is characterized by the signs of inflammation and dystrophic lesions in the mucous coat with subsequent atrophy of the wall. Pathological processes can be extended to the entire area of the intestine or be local in nature [3,4,5].

Recently, many publications have appeared on how to use tissue specimen transplantation in multiple inflammatory diseases of the small intestine. Therefore, transplantation of cryopreserved placental tissues is widely used. At the same time, no evidence of legal and well-reasoned use of these specimens has been found in the literature, as well as detailed experimental studies, demonstrating the efficacy of this therapy.

Thus, the analysis of morphological manifestations of cryopreserved placenta transplantation effect in conjunction with acute aseptic inflammation of rat peritoneum is crucial.

Purpose. The research was aimed at comparative analysis of changes in morphometric parameters of rat small intestine wall in acute aseptic inflammation of the peritoneum and its correction by cryopreserved placenta transplantation.

Material and Methods. The object of the experimental study was the small intestine (duodenum, jejunum and ileum) wall, extracted from 115 Wistar senior male rats. Animal housing and experiments on them have been carried out in compliance with the “General Ethic Rules for Conducting Experiments on Animals” (2006, Annex 4) and Declaration of Helsinki on ethical principles for medical research involving human subjects.

The animals have been assigned to five groups: Group I (n=5) included intact animals; Group II (n=10) included control animals, who were single time administered with 1 ml intraperitoneal saline; Group III (n=10) included control animals, who were single time administered with 1 ml intraperitoneal saline and who were made incision on the outer surface of the hip with subsequent suture ligation; Group IV (n=45) was single time administered with intraperitoneal I-carrageenan (Sigma – USA) (5 mg in 1ml saline per one animal) to induce the acute aseptic inflammation of the peritoneum; Group V (n=45) was single time administered with intraperitoneal I-carrageenan (Sigma – USA) (5 mg in 1ml saline per one animal) to induce the acute aseptic inflammation of the peritoneum with subsequent single time administration of subcutaneous cryopreserved placenta (“Platex-Placental” medical immunobiological agent, State Registration Certificate No.73408-30020000, July, 9, 2008).

The animals were killed under thiopental anesthesia overdose in compliance with the scheduled periods (1, 2, 3, 5, 7, 10, 14, 21, 30 day of the experiment). Pieces of small intestine (duodenum, jejunum and ileum) were compressed by paraffin and epoxy according to conventional technique. The obtained blocks were sectioned and stained with hematoxylin-eosin and methylene blue. The overall thickness of the wall, thickness of mucous coat and submucous layer in rat duodenum, jejunum and ileum has been measured. Microscope with Olympus C 3040-ADU digital microphotohead with Olympus DP – Soft software, adapted for the herein studies (License No. VJ285302, VT310403, 1AV4U13B26802) and BIOREX 3 (serial number 5604) has been used. Mathematical treatment of the material has been carried out using the conventional methods of variation statistics: calculation of mean values (M), error of mean (m), Student’s T-test (t). Differences were considered to be reliable, when $p < 0.05$.

Results and Discussion. The analysis of morphometric parameters of rat small intestine mucosa thickness on all segments (duodenum, jejunum and ileum) in control group II and III has shown no statistical difference between them throughout the experiment. Reliability of differences is insignificant in $p > 0,05$. The comparison of these parameters with similar ones in the intact group of rodents has shown that reliability of difference was insignificant, too ($p > 0,05$). This fact allows further comparison of studied morphometric parameters of animal group IV and V with the similar ones in the intact group only, not considering the data from control groups.

Statistical analysis of the overall thickness of small intestine wall, thickness of mucous coat and submucous layer in various segments has shown that in the group of animals with induced acute aseptic inflammation of the peritoneum (Group IV) the peak values of these parameters became apparent on the 10-14 day of the experiment (**Figure 1A and B**). Reliability of values is significant for the duodenum and jejunum. Starting from the day 21, the values of the analyzed parameters were lowering. On day 30 it was established that these

parameters were decreasing, not always reaching to the values of the similar parameter in the intact group.

Further study of changes in morphometric parameters in Group V, who underwent single time subcutaneous transplantation of cryopreserved placenta as the corrector of inflammation, induced by the simulated acute aseptic inflammation of the peritoneum, has established that changes in the parameters was somehow different.

In this way, the analysis of morphometric parameters of the overall thickness of the duodenum wall in Group V showed that they varied differently throughout the experiment. The results are presented in **Figure 2A**.

Administration of cryopreserved placenta in conjunction with acute aseptic inflammation of the peritoneum promotes the overall thickening of the intestine wall that becomes apparent from day 1 to day 10 of the experiment. On day 1 the overall thickening of the intestine wall was noted; however it was insignificant in comparison with the intact group. From day 2 to day 5 this parameter was increasing. Its comparison with the intact group was significant in $p < 0,05$. Starting from day

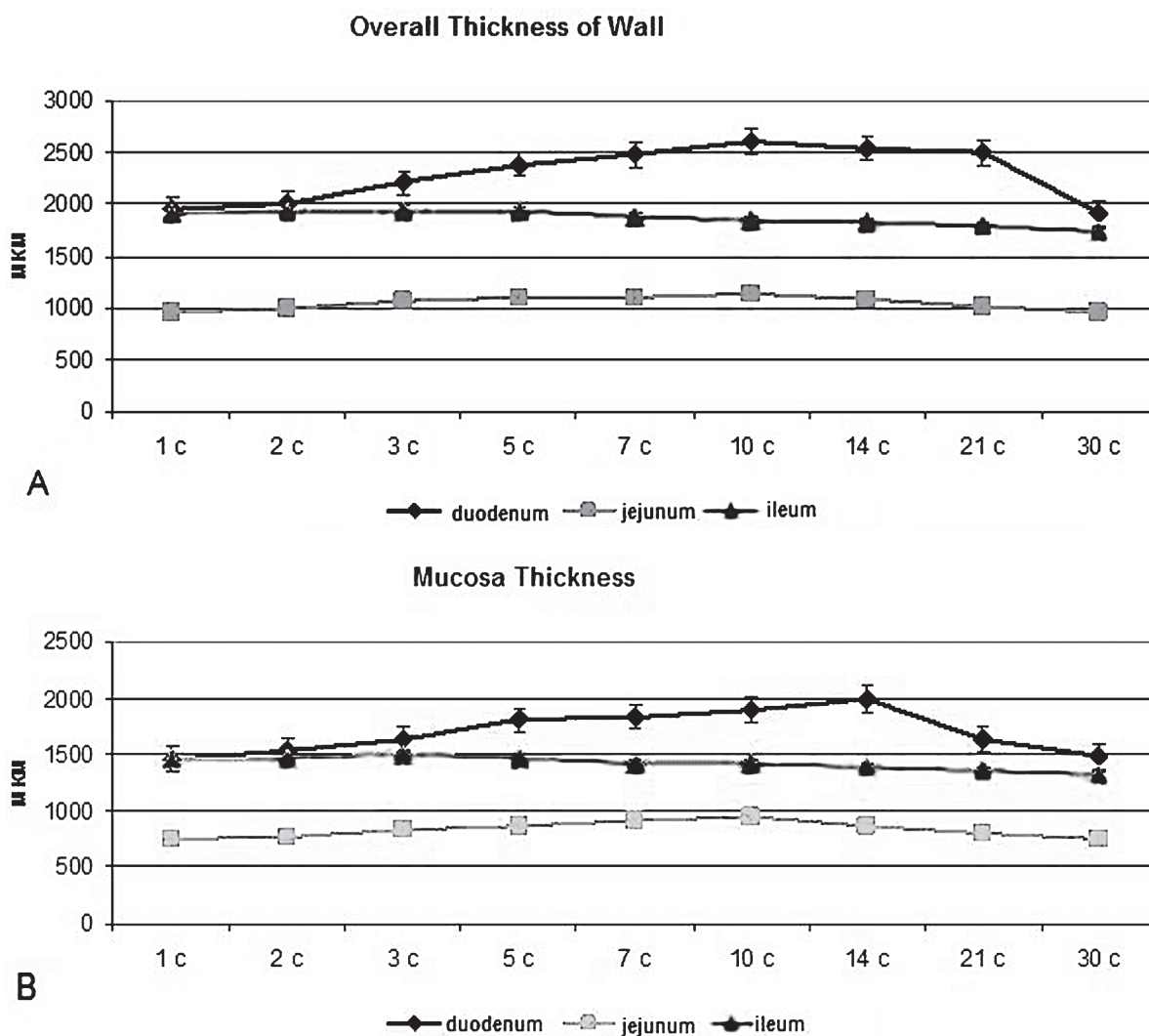


Figure 1. Overall thickness of wall (A); thickness of duodenum, jejunum and ileum mucosa (B) in conjunction with acute aseptic inflammation of the peritoneum.

МОРФОЛОГІЯ

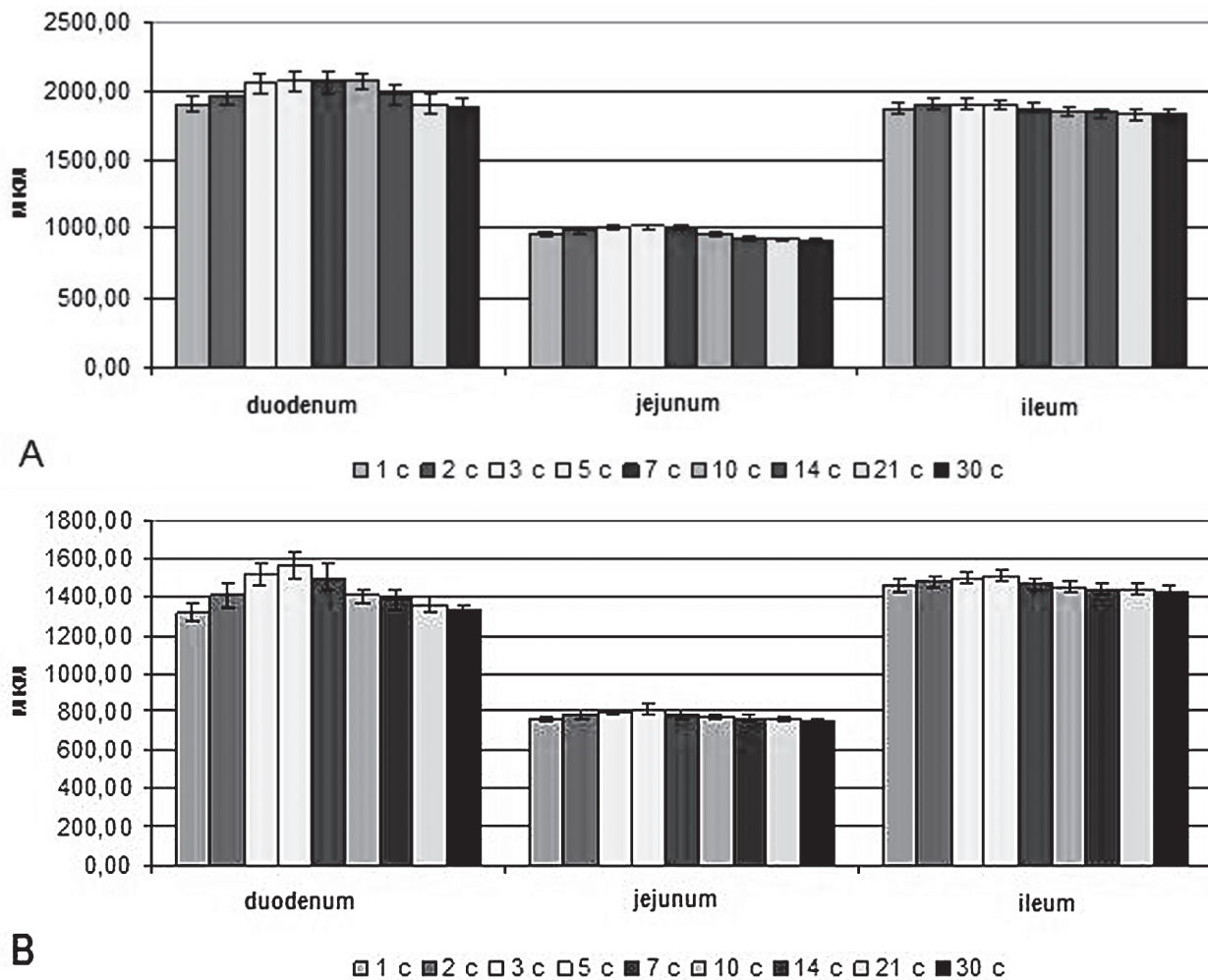


Figure 2. Overall thickness of wall (A); thickness of duodenum, jejunum and ileum mucosa (B) in transplantation of cryopreserved placenta in conjunction with acute aseptic inflammation of the peritoneum.

5 to day 10 of the experiment the parameter of overall thickness of wall remained unchanged, though it was significantly higher, as compared with the intact group. On day 14 the overall thickness of the intestine wall was reduced, but the reliability of difference was significant only in comparison with the intact group. On day 30 the parameter of the overall thickness of wall was within the similar parameter in the intact group.

Statistical analysis of duodenum mucosa thickness showed that it varied throughout the experiment. The results are presented in **Figure 2B**. On day 1-2 no statistical difference in mucosa thickness, as compared with the similar parameter in the intact group, was observed; reliability of difference in $p > 0,05$. From day 3 to day 10 of the experiment this parameter was significantly higher with peak value on day 5, as compared with the intact group ($p < 0,05$). Starting from day 7 to day 10 the mucosa thickness was reducing and this reduce was significant, as compared with the intact group in $p < 0,05$. On day 14-21 of the experiment no significant difference in this parameter was noted, as compared with the intact group, and on day 30 it was within the latter.

Statistical analysis of duodenum submucous layer thickness has shown that it also varied differently throughout the experiment. A significant increase of this parameter has been noted on day 2-5, as compared with the intact group. On day 5-10 a significant thinning of the submucosa was observed, as compared with the similar parameter in the intact group. During the day 14-21 this parameter was decreasing, but such decrease was insignificant. On day 30 the value of this parameter was similar to the same parameter in the intact group.

Administration of cryopreserved placenta in conjunction with acute aseptic inflammation of peritoneum promotes enlargement of the overall thickness of jejunum wall that becomes apparent from day 1 to day 5 of the experiment (**Figure 2A**). The comparison of this parameter with the periods of the experiment showed no reliability of difference. While comparing the parameter between day 1 and day 3 and day 1 and day 5, the reliability of difference was observed in $p < 0,05$. On day 7 a decrease in the overall thickness was noted. The comparison with the previous period showed that this reduction was insignificant ($p > 0,05$). On day 10 this parameter significantly decreased, as compared with

day 7 ($p < 0,05$). From day 14 to day 30 this parameter were decreasing, but reliability of difference was insignificant.

The following changes have been found while comparing the parameter of the overall thickness of the wall with the similar one in the intact group. From day 1 to day 10 this parameter was significantly higher ($p < 0,05$), and starting from day 14 to day 30 no significant difference from the intact group of animals was observed ($p > 0,05$).

The analysis of small intestine mucosa thickness parameter (**Figure 2B**) has shown its increase from day 1 to day 5 of the experiment. The comparison between these periods revealed a significant reliability of difference between the day 1 and 3 and day 1 and 5 ($p < 0,05$). On day 7 a decrease in mucosa thickness was noted. The comparison with day 5 showed that this reduction was insignificant. From day 10 to day 30 the decrease of this parameter was observed, though reliability of difference was insignificant between the periods. While comparing the parameter of mucosa thickness with the group of intact animals we have found that from day 2 to day 10 this parameter was significantly higher ($p < 0,05$). Starting from day 14 to day 30 of the experiment the reliability of differences was insignificant.

The analysis of morphometric parameter of the jejunum submucous layer thickness has revealed the increase of this parameter from day 1 to day 5 of the experiment. The comparison between the periods of experiment showed insignificant reliability of difference. While comparing the day 1 and day 5, the reliability of difference ($p < 0,05$) has been found. Starting from the day 7 this parameter was decreasing, as compared with day 5, but such reduction was insignificant. On day 10 we observed a significant decrease of the parameter, as compared with day 7. From day 14 to day 30 of the experiment no significant decrease of the parameter was noted between the periods of the experiment. The comparison of this parameter with the similar one in the intact group showed its significant increase on day 2-7. On day 10-30 no significant difference from the intact group was noted.

The analysis of morphometric parameter of the ileum wall thickness (**Figure 2A**) of Group III has shown that it varied differently throughout the experiment. In this way, administration of cryopreserved placenta between the periods of the experiment in conjunction with acute aseptic inflammation of peritoneum promotes enlargement of the overall thickness of the ileum wall that becomes apparent from day 1 to day 3 of the experiment with peak values on the 3-5 day, but the reliability of difference between them is insignificant. From day 5 to day 30 the overall thickness of the ileum wall reduced, but the reliability of difference between them was insignificant. The comparison with the intact group established that starting from day 1 the parameter increased, but no significant difference was noted. From day 2 to day 5 a significant growth of this parameter was observed, as compared with intact group ($p < 0,05$). From day 7 a decrease of this parameter was noted, but, as compared with intact group, no reliability of difference between them was found; from day 10 to day

30 this parameter decreased and was within the values of the intact group.

Statistical analysis of the ileum mucosa thickness (**Figure 2B**) between periods of the experiment has shown its variability throughout the experiment. Thus, from day 1 to day 3 it increased. On day 5 this parameter was maximally high, but while comparing it with the previous periods, no statistical difference between them was found. Starting from day 7 to day 14 thickness of mucous coat was reduced, but this reduction was insignificant, as compared with the previous period ($p > 0,05$). Starting from day 21 to day 30 insignificant decrease of this parameter was noted, too. The following dynamics was observed while comparing this parameter with the similar one in the intact group: on day 1 the parameter increased, but no significant difference between the groups was noted. From day 2 to day 5 of the experiment a significant increase of the parameter was detected, as compared with the intact group ($p < 0,05$). Starting from day 7 to day 30 the parameter decreased, but no significant difference from the intact group was noted ($p > 0,05$).

The analysis of statistical data of the ileum submucous layer thickness between the periods of the experiment has revealed the following changes: the increase of the parameter already on day 1 of the experiment with subsequent growth up to day 5, reaching the peak value, but no significant difference between the periods of the experiment was noted ($p > 0,05$). Starting from day 7 to day 14 submucous layer thinning was observed, but it was also insignificant. On day 21-30 the parameter was decreasing, but no significant difference between the periods of the experiment was noted. The comparison with the intact group revealed the following dynamics: on day 1 the parameter increased, but no significant difference between the groups was found. From day 2 to day 5 of the experiment a significant increase of the parameter was observed, as compared it with the intact group ($p < 0,05$). Starting from day 7 and finishing on day 30 the parameter decreased, but no significant difference was noted.

Conclusions. Therefore, the analysis of the parameters (overall thickness of wall, thickness of mucous coat and submucous layer) of three segments of small intestine (duodenum, jejunum and ileum) has shown that in simulated acute aseptic inflammation of the peritoneum the increase of studied parameters was noted on day 14 with subsequent decrease of these parameters to day 30.

In transplantation of cryopreserved placenta in conjunction with acute aseptic inflammation of the peritoneum the increase of studied parameters with peak values on day 5-7 is observed. It should be noted that such increase is significant during the analysis of the parameters of duodenum and jejunum; reliability of difference in $p < 0,05$. In the ileum this increase is insignificant. A decrease of values of these parameters occurs starting from day 7, and on day 21-30 they are within the values of the intact group.

Perspectives of further research will encompass the study of the cellular composition of small intestine lymphatic system.

References

1. Ардаматская М.Д. Дисбактериоз кишечника: эволюция взглядов. Современные принципы диагностики и фармакологической коррекции / М.Д. Ардаматская, О.М. Минушкин // *Consilium medicum*. – 2006. – № 1, Прил. «Гастроэнтерология». – С. 4-17.
2. Білаш С.М. Морфофункціональна характеристика структурних компонентів шлунку інтактних щурів та при введенні кріоконсервованої плаценти на тлі гострого експериментального запалення: автореф. дис д-ра біол. наук / С.М. Білаш. – Тернопіль, 2013. – 36 с.
3. Белобородов В.Б. Антибактериальная терапия больных острыми кишечными инфекциями / В.Б. Белобородов, Ю.С. Алятин // *Consilium Medicum*. – 2002. – № 6. – С. 295-298.
4. Воробьев Г.И. Неспецифические воспалительные заболевания кишечника / Г.И. Воробьев, И.Л. Халиф. – М.: Миклош, 2008. – 422 с.
5. Звягинцева Т.Д. Синдром избыточного бактериального роста: современные подходы к лечению / Т.Д. Звягинцева, А.И. Чернобай // *Сімейна медицина*. – 2013. – № 4. – С. 31-38.
6. Парфенов А.М. Дисбактериоз кишечника: вопросы биологической терапии / А.М. Парфенов, И.Н. Ручкина, Г.А. Осипов, [и др.] // *Трудный пациент*. – 2007. – Т. 5, № 5. – С. 23-28.
7. Парфенов А.И. Энтерология / А.И. Парфенов. – М.; Мед. информ. агентство, 2009. – 886 с.
8. Шепітько В.І. Кріоконсервована плацента вплив на перебіг експериментального сіададеніту / В.І. Шепітько, Г.А. Єрошенко, Т.М. Юрченко [та ін.]. – Полтава: Копирсервіс, 2013. – С. 122.
9. Bernstein C.N. Epidemiology and Natural History Task Force of the international rganization of inflammatory Bowel Disease (IOIBD). eographical variability and environmental risk factors in inflammatory bowel disease / C.N. Bernstein, M.H. Vatn [et al.] // *Gut*. – 2013. – Vol. 2 (4). –P. 630-649.
10. Schreiber S. Genetic etiology of chronic inflammatory bowel disease / S. Schreiber, P. Rosenstiel, A. Franke // *Internist Berl*). – 2014. – Vol. 55 (2). – P. 156-164.

УДК 616.341-002-092.9:618.36-001.17-089.873

МОРФОМЕТРИЧНА ХАРАКТЕРИСТИКА СТІНКИ ТОНКОЇ КИШКИ ПРИ ВВЕДЕННІ КРІОКОНСЕРВОВАНОЇ ПЛАЦЕНТИ І АСЕПТИЧНОМУ ЗАПАЛЕННІ ОЧЕРЕВИНИ У ЩУРІВ

Шепітько К. В., Шепітько В. І.

Резюме. Метою даного дослідження було вивчення в порівнянні змін морфометричних параметрів стінки тонкої кишки у щурів при гострому асептичному запаленні очеревини і його корекції трансплантацією кріоконсервованої плаценти.

Вивчення параметрів (загальна товщина стінки, товщина слизової оболонки і підслизового прошарку) трьох відділів тонкої кишки (12-палої, порожня і клубова) показало, що при моделюванні гострого асептичного запалення очеревини збільшення вивчених параметрів зазначалося на 14 добу з подальшим зменшенням цих показників до 30 діб.

При трансплантації кріоконсервованої плаценти на тлі гострого асептичного запалення очеревини відбувається збільшення вивчених показників з максимальними значеннями на 5-7 добу. Звертає на себе увагу той факт, що це збільшення істотно при аналізі показників 12-палої і тонкої кишки, достовірність різниці при $p < 0,05$. У клубовій кишці це збільшення не суттєво. Починаючи з 7 діб, відзначається зменшення значень цих показників і на 21-30 добу вони знаходяться в межах значень інтактної групи.

Ключові слова: тонка кишка, запалення, очеревина, трансплантація кріоконсервованої плаценти, товщина стінки кишки, морфометрія.

УДК 616.341-002-092.9:618.36-001.17-089.873

МОРФОМЕТРИЧЕСКАЯ ХАРАКТЕРИСТИКА СТЕНКИ ТОНКОГО КИШЕЧНИКА ПРИ ВВЕДЕНИИ КРИОКОНСЕРВИРОВАННОЙ ПЛАЦЕНТЫ И АСЕПТИЧЕСКОМ ВОСПАЛЕНИИ БРЮШИНЫ У КРЫС

Шепитько К. В., Шепитько В. И.

Резюме. Целью данного исследования было изучение в сравнении изменений морфометрических параметров стенки тонкой кишки у крыс при остром асептическом воспалении брюшины и его коррекции трансплантацией креноксервированной плаценты.

Изучение параметров (общая толщина стенки, толщина слизистой оболочки и подслизистой основы) трех отделов тонкой кишки (12-перстная, тощая и подвздошная) показало, что при моделировании острого асептического воспаления брюшины увеличение изученных параметров отмечалось на 14 сутки с последующим уменьшением этих показателей к 30 суткам.

При трансплантации креноксервированной плаценты на фоне острого асептического воспаления брюшины происходит увеличение изученных показателей с максимальными значениями на 5-7 сутки. Обращает на себя внимание тот факт, что это увеличение существенно при анализе показателей 12-перстной и тощей кишки, достоверность разницы при $p < 0,05$. В подвздошной кишке это увеличение не существенно. Начиная с 7 суток, отмечается уменьшение значений этих показателей и на 21-30 сутки они находятся в пределах значений интактной группы.

Ключевые слова: тонкая кишка, воспаление, брюшина, трансплантация креноксервированной плаценты, толщина стенки кишки, морфометрия.

UDC 616.341-002-092.9:618.36-001.17-089.873

MORPHOMETRIC CHARACTERISTIC OF RAT SMALL INTESTINE WALL IN ADMINISTRATION OF CRYO-PRESERVED PLACENTA AND ASEPTIC INFLAMMATION OF PERITONEUM

Shepitko K. V., Shepitko V. I.

Abstract. Small intestine pathology is accompanied by chronic inflammatory processes and, consequently, resulting in metabolic disorders, leading to malabsorption syndrome. Considering the fact that such diseases often occur in individuals of working age, treatment of the diseases requires certain material costs, highlighting the social and economic importance of the problem.

The research was aimed at comparative analysis of changes in morphometric parameters of rat small intestine wall in acute aseptic inflammation of the peritoneum and its correction by cryopreserved placenta transplantation.

The object of the experimental study was the small intestine (duodenum, jejunum and ileum) wall, extracted from 115 Wistar senior male rats. Animal housing and experiments on them have been carried out in compliance with the "General Ethic Rules for Conducting Experiments on Animals" (2006, Annex 4) and Declaration of Helsinki on ethical principles for medical research involving human subjects. Differences were considered to be reliable, when $p < 0.05$.

The analysis of morphometric parameters of rat small intestine mucosa thickness on all segments (duodenum, jejunum and ileum) in control group II and III has shown no statistical difference between them throughout the experiment. Reliability of differences is insignificant in $p > 0.05$. Statistical analysis of the overall thickness of small intestine wall, thickness of mucous coat and submucous layer in various segments has shown that in the group of animals with induced acute aseptic inflammation of the peritoneum (Group IV) the peak values of these parameters became apparent on the 10-14 day of the experiment. Reliability of values is significant for the duodenum and jejunum. Starting from the day 21, the values of the analyzed parameters were lowering. On day 30 it was established that these parameters were decreasing, not always reaching to the values of the similar parameter in the intact group.

Administration of cryopreserved placenta in conjunction with acute aseptic inflammation of the peritoneum promotes the overall thickening of the intestine wall that becomes apparent from day 1 to day 10 of the experiment. On day 1 the overall thickening of the intestine wall was noted; however it was insignificant in comparison with the intact group. From day 2 to day 5 this parameter was increasing. Its comparison with the intact group was significant in $p < 0.05$. Starting from day 5 to day 10 of the experiment the parameter of overall thickness of wall remained unchanged, though it was significantly higher, as compared with the intact group. On day 14 the overall thickness of the intestine wall was reduced, but the reliability of difference was significant only in comparison with the intact group. On day 30 the parameter of the overall thickness of wall was within the similar parameter in the intact group.

Therefore, the analysis of the parameters (overall thickness of wall, thickness of mucous coat and submucous layer) of three segments of small intestine (duodenum, jejunum and ileum) has shown that in simulated acute aseptic inflammation of the peritoneum the increase of studied parameters was noted on day 14 with subsequent decrease of these parameters to day 30.

In transplantation of cryopreserved placenta in conjunction with acute aseptic inflammation of the peritoneum the increase of studied parameters with peak values on day 5-7 is observed. It should be noted that such increase is significant during the analysis of the parameters of duodenum and jejunum; reliability of difference in $p < 0.05$. In the ileum this increase is insignificant. A decrease of values of these parameters occurs starting from day 7, and on day 21-30 they are within the values of the intact group.

Keywords: small intestine, inflammation, peritoneum, transplantation of cryopreserved placenta, intestine wall thickness, morphometry.

*Рецензент – проф. Білаш С. М.
Стаття надійшла 05.03.2016 року*