

PROPHYLAXIS AND TREATMENT OF GASTRIC ULCERS SYNDROME IN HORSES

K. Kubiak¹, M. Jankowski¹, J. Spużak¹, A. Niedźwiedź¹, J. Nicpoń¹, V. Vlizlo², K. Michlik¹,
M. Grzegory¹, I. Maksymovych³

¹Department of Internal Diseases with Clinic for Horses, Dogs and Cats, Faculty of Veterinary
Medicine, University of Environmental and Life Sciences, Poland

²Institute of the Animal Biology of UAAS Ukraine

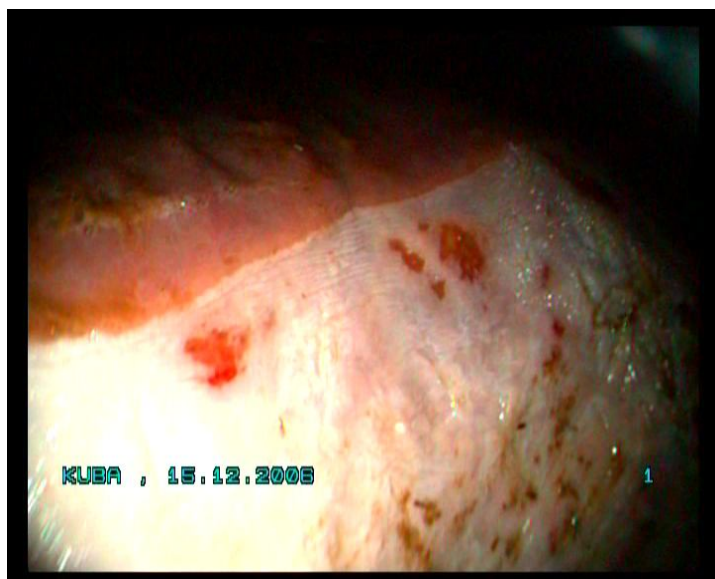
³Department of Clinical Diagnostics, Lviv National University
of Veterinary Medicine and Biotechnology, Ukraine

For several years, we observe a higher frequency of gastric ulcers in horses (Equine Gastric Ulcus Syndrome — EGUS), regardless of age, gender and race. Increased frequency of recognition of this condition, is probably associated with the introduction of diagnostic endoscopy, which allows for accurate inspection of initial gastrointestinal tract [6, 20]. Underlying reason of the formation of ulcers in the stomach mucosa, are wrong nutrition, stressful training and administration of antiinflammatory drugs (NSAIDs) with low selectivity [1–3, 14, 15]. According to reports by various authors, the prevalence of gastric ulcers can reach even 90 % in adult horses, especially those used in sports [6, 12, 19]. Early diagnosis and adequate treatment is able to completely normalize the state of gastric mucosa. The most frequently used drugs are proton pump inhibitors, but in foals due to the slightly different pathomechanism in formation of gastric ulcers, may not be sufficient [8].

The aim of this study was to describe the current knowledge concerning the prevention and treatment of stomach ulcers in horses, based on our own experience.

Materials and methods

The study involved 15 horses of various breeds and sex, main age range from 2 to 10 years, in which based of endoscopy, was diagnosed stomach ulcers. Gastroscope was performed after appropriate dietary preparation, which included a 24 h hunger strike and 6–8 h break in the administration of water. Horses have been sedated with intravenously administered detomidine hydrochloride in dose 40 mg/kg b.w.



The study was performed using Storz videoendoscope with a working length of 3,25 m and a diameter of 1,5 cm. In the treatment of gastric ulcers, we used pharmacological therapy: histamine H₂-receptor antagonists (cimetidine, ranitidine) and the drugs coating of the mucosa (sucralfate). Also recommended appropriate management in the field of nutrition and training of a horses.

In the treatment of gastric ulcers in horses, may be used medications from the following groups:

— histamine receptor antagonists
— it's block H₂ receptors of wall's cell, causing a significant reduction of gastric

acid secretion, the action lasts for up to 8 h, oral bioavailability is quite low, which determines the application of high doses (*cimetidine, ranitidine, famotidine, nizatidine*);

— proton pump inhibitors — the direct inhibition of the proton pump, work up to 24 h (*omeprazole, lansoprazole*);

— antacid's preparations (Antacida) — heighten the gastric pH, operate 30–120 min., administrate in large quantities every 2 h (*aluminum compounds, calcium, magnesium and bismuth*);

— preparations to protect the mucous membrane and support the natural healing process of ulcers (*sucralfate*, preparations containing complex: *natural pectin — lecithin — glycerol*);

— medications that increase gastric motility (*bethanechol* — actually not available in Poland).

Table 1

Dosage of the medicines used in EGUS treatment (2, 5, 10, 12)

RANITIDINE	1,5 mg/kg b.w. IV q 8 h 6–7 mg/kg b.w. PO q 8 h.
CIMETIDINE	6–7 mg/kg b.w. IV q 8 h 10–25 mg/kg b.w. PO q 8 h
FAMOTIDINE	3–5 mg/kg b.w. PO q 8 h
MISOPROSTOL	1,5–2,5 µg/kg b.w. PO q 8 h
SUCRALFATE	10–20 mg/kg b.w. PO q 8 h
OMEPRAZOLE	0,5 mg/kg b.w. IV q 24 h 1–4 mg/kg b.w. PO q 24 h
BETHANECHOL	0,35 mg/kg b.w. PO q 8 h
AlOH	30 g PO q 2 h
MgOH	15 g PO q 2 h

During treatment, the preferred route of drugs administration is oral, due to the possibility of continuing treatment by the owner. Required is to discontinue the horse from training and ensure adequate living conditions. In addition to adjuvant pharmacological agents, it can also be used a dietary supplements coating mucosa and neutralizing acids. It must be remembered that this agents used only as a therapeutic agent, do not produce a satisfactory effect [6, 11]. These preparations can also be administered to prevent relapse after recovery from ulcers or prophylactically, in a period of increased stress and during administration of NSAID's [2, 5, 6].

Table 2

Pattern of gastric ulcer therapy in adult horses (4)

Endoscopy	Changes in the nonglandular mucosa	Changes in the glandular mucosa	Recommended treatment
No	?	?	omeprazole paste ranitidine cimetidine
Yes	Yes	No	omeprazole paste ranitidine cimetidine repeat endoscopic exam. after treatment
Yes	No	Yes	sucralfate repeat endoscopic exam. after treatment
Yes	Yes	Yes	omeprazole paste ranitidine cimetidine sucralfate repeat endoscopic exam. after treatment

In Poland there are preparations containing a special complex combination of natural pectin, lecithin and glycerol, which provides them with a protective effect on gastric mucosa, and also allows to neutralize and reduce the excessive increase in acidity of gastric contents [2, 5, 6]. In the treatment of gastric ulcers in horses, the most widely used drug is omeprazole (proton pump inhibitor), which is as safe as also used in foals, as well as histamine receptor antagonists [13, 16, 18]. Aluminum or magnesium hydroxide, because of the need for frequent administration of large volumes should be avoided in usage during EGUS treatment. The prevention of gastric ulcers in horses undergoing intensive sports, it is worth noting the use of the preparation of omeprazole at a dose of 2 mg/kg, 4–8 h before the competition [7, 9, 10, 17]. This is very important especially in the first month of intense exercise, when the young horses are entered in a stressful demanding, high-performance training. In our first study, both cimetidine and ranitidine were administered intravenously and then orally in the following doses: cimetidine — 6 mg/b.w. q 8 h IV and 20 mg/kg b.w. q 6 h PO, ranitidine 1.5 mg/kg b.w. IV q 8 h and 6 mg/kg b.w. PO q 8 h. Sucralfate was administered orally, every 8 h in dose 15 mg/kg. These drugs, as well as feed additives containing complex pectin-lecithin-glycerol were used for 4 weeks.

In the field of animal nutrition and training we recommended:

- frequent feeding with low amounts of concentrate (4–5 times a day);
- optimizing the production of saliva through the feeding with bulk feed (1–1.5 kg/100 kg b.w.) before concentrate (max 0.5 kg/100 kg b.w./meal);
- permanent access to hay;
- adaptation of the energy value of feed, to the needs of the horse;
- access to the paddock / pasture;
- avoidance hunger strikes, especially before a competition (the last feeding at 1–1.5 h before exercise).

These dietary recommendations, and training should also be applied in the prevention of ulcers in horses [16]. In our study after a 4-week treatment another gastroscopy examination was carried out, which confirmed the healing of gastric ulcers in all horses.

Conclusion

EGUS due to the increasing of its occurrence and also higher frequency of identify, has become an important problem in medical practice of the practitioners. With the introduction of diagnostic endoscopy is possible to accurate assessment of the gastric mucosa, and make a certain diagnosis. Appropriate pharmacotherapy, even lasting for several weeks, in most cases allows for full recovery. However, it should always take into consideration both, the pharmacological therapy and recommendations for training and nutrition.

*К. Кубяк, М. Янковські, Й. Спужак, А. Недзведзь,
Й. Ніцпон, В. Влізло, К. Міхлік, М. Гжегори, І. Максимович*

ПРОФІЛАКТИКА І ЛІКУВАННЯ ВИРАЗКИ ШЛУНКА У КОНЕЙ

Резюме

Протягом декількох років ми спостерігаємо збільшення випадків виразки шлунка у коней (Equine Gastric Ulcer Syndrome — EGUS) незалежно від віку, статі і породи. Очевидно, це пов'язано із запровадженням у діагностику ендоскопічних досліджень, які дають можливість детально обстежити початкові відділи шлунково-кишкового тракту [6, 12]. Причинами формування виразки у слизовій шлунка є неправильна годівля, стреси при тренуванні і використання протизапальних препаратів широкого спектру [1–3, 14, 15]. Згідно

з повідомленнями багатьох авторів на виразку шлунка можуть хворіти до 90 % коней, особливо спортивних [6, 12, 19]. Рання діагностика і правильне лікування можуть повністю нормалізувати стан слизової оболонки. Найчастіше у лікуванні застосовують інгібітори протонної помпи, проте у зв'язку з певними відмінностями патогенезу формування виразок шлунка їх дія може бути не ефективна.

*К. Кубяк, М. Янковски, І. Спужак, А. Недзведзь,
І. Ницпон, В. Влизло, К. Михлик, М. Гжегори, І. Максимович*

ПРОФИЛАКТИКА И ЛЕЧЕНИЕ СИНДРОМА ЖЕЛУДОЧНОЙ ЯЗВЫ У КОНЕЙ

А н н о т а ц и я

Несколько лет мы наблюдаем увеличение случаев язвы желудка у коней (Equine Gastric Ulcer Syndrome — EGUS) независимо от возраста, пола и породы. Очевидно, это связано с внедрением в диагностику эндоскопических исследований, что позволяет тщательно обследовать кишечно-желудочный тракт [6, 12]. Основными причинами язвы желудка является неправильное питание, стрессы при тренировках и употребление противовоспалительных лекарств широкого спектра [1–3, 14, 15]. Согласно отчетов разных авторов язва желудка случается почти в 90 % взрослых коней, особенно спортивных [6, 12, 19]. Ранняя диагностика и правильно подобранное лечение способны нормализовать состояние слизистой оболочки. Наиболее часто в лечении используют ингибиторы протонного насоса, однако в связи с некоторыми отличиями патогенеза язвы желудка их действие может быть неэффективным.

1. *Stephen M. R., Warwick M. B.* Equine Internal Medicine, in: Michael J. Murray, 12.3. Gastroduodenal ulceration. 1998, Philadelphia, W.B. Saunders company.
2. *Dietz O., Huskamp B.* Praktyka kliniczna: KONIE, in: Huskamp B., Kopf N., Scheidemann W., Schusser G.F.: Wrzody żołądka, 2208, Galaktyka Sp. z o. o., Łódź.
3. *Sikora J.* Choroby układu pokarmowego koni, in: Choroby żołądka, Wydawnictwo SI-MA, Warszawa 2008.
4. *Mair T., Divers T., Ducharme N.* Diseases of the Stomach in: Manual of equine Gastroenterology. 2002, W. B. Saunders, London.
5. *Kamionka-Flak A.* II Żywieckie Warsztaty Weterynaryjne 7-8.03.2009 r., Żywiec.
6. *Nicpoń J., Trela T.* Aktualne możliwości leczenia wrzodów żołądka u koni. Weterynaria w Praktyce. 2004, 5.
7. *McClure S. R.* Efficacy of omeprazole paste for prevention of gastric ulcers in horses in race training. / McClure S. R., White G. W., Sifferman R.L., et al. // J. am. vet. med. assoc. — 2005. — 226. — P.1681–1684.
8. *Buchanan B. R.* Treatment and prevention of equine gastric ulcer syndrome / Buchanan B. R., Andrews F. M. // Vet. Clin. North. Am. Equine Pract. — 2003. — 19. — P. 575-597.
9. *Merritt A. M.* Effect of GastroGard and three compounded oral omeprazole preparations on 24 h intragastric pH in gastrically cannulated mature horse / Merritt A. M., Sanchez L. C., Burrow J. A. et al // Equine Vet. J. — 2003. — 35. — P. 691–695.
10. *Doucet M. Y.* Efficacy of a paste formulation of omeprazole for the treatment of naturally occurring gastric ulcers in training standardbred racehorses in Canada / Doucet M. Y., Vrins A. A., Dionne R. et al // Can. Vet. J. — 2003. — 7. — P. 581–585.

11. *Murray M. J.* The effect of a pectin-lecithin complex on prevention of gastric mucosal lesions induced by feed deprivation in ponies / Murray M. J., Grady T. C. // *Equine Vet. J.* — 2002. — 34. — P. 195–198.
12. *Andrews F. M.* Efficacy of omeprazole paste in the treatment and prevention of gastric ulcers in horses / Andrews F. M., Sifferman R. L., Bernard W. et al // *Equine Vet. J.* — 1999. — Suppl. 29. — P. 81–86.
13. *Plue R. E.* Safety of omeprazole paste in foals and mature horses / Plue R.E., Wall H.G., Daurio C., et al // *Equine Vet. J.* — 1999. — Suppl. 29. — P. 63–66.
14. *Luthersson N.* Risk factors associated with equine gastric ulceration syndrome (EGUS) in 201 horses in Denmark / Luthersson N., Nielsen K. H., Harris P., et al // *Equine Vet. J.* — 2009. — 41. — P. 625–630.
15. *Videla R.* New perspectives in equine gastric ulcer syndrome / Videla R., Andrews F. M. // *Vet. Clin. North. Am. Equine Pract.* — 2009. — 25. — P. 283–301.
16. *Reese R. E.* Nutrition and dietary management of equine gastric ulcer syndrome. / Reese R. E., Andrews F. M. // *Vet. Clin. North. Am. Equine Pract.* — 2009. — 25. — P. 79–92.
17. *Javsicas L. H.* The effect of omeprazole paste on intragastric pH in clinically ill neonatal foals / Javsicas L. H., Sanchez L. C. // *Equine Vet. J.* — 2008. — 40. — P. 41–44.
18. *White G.* Effects of short-term light to heavy exercise on gastric ulcer development in horses and efficacy of omeprazole paste in preventing gastric ulceration. / White G., McClure S. R., Sifferman R., et al // *J. Am. Vet. Med. Assoc.* — 2007. — 230. — P. 1680–1682.
19. *Bell R. J.* Equine gastric ulcer syndrome in adult horses : a review / Bell R. J., Mogg T. D., Kingston J. K. // *N Z Vet J.* — 2007. — 55. — P. 11–12.
20. *Slovis N. M.* Atlas of Equine Endoscopy / Bain F. T., Petrizzi L., Valbonetti L., Muttini A. // *Gastrosocopy and Duodenoscopy.* — Mosby, St. Louis, 2004.

Рецензент: завідувач лабораторії живлення ВРХ, доктор сільськогосподарських наук, с. н. с. наук І. В. Вудмаска.