

UDK 619:577.27:602.9:612.753

## EFFECT OF MESENCHYMAL STEM CELLS IN REPARATIVE OSTEOGENESIS IN ANIMALS

**M. O. MALUYK**, *doctor of veterinary science, professor,*

**M. A. KULIDA**, *candidate of veterinary sciences, associate professor*

**A. S. SERDYUKOV**, *candidate of veterinary sciences, associate professor*

**A. V. BOGOSLAVETS**

**National University of Life and Environmental Sciences of Ukraine**

*E-mail: mkulida@ukr.net*

Investigated correlation structure of bone and regenerate fibrinous in rabbits during treatment with allogeneic mesenchymal bone marrow stem cells to correct reparative process in the tissue of animals.

Found that the experimental group of animals regeneration of bone in the defect area occurred much faster and better than animals in the control group. These are the facts: regenerate a large area compared to animals in the control group; more pronounced development periosteum compared to animals in the control group; greater intensity of calcium deposits compared to animals in the control group; no pathological changes (histiocytic infiltration of fibrous connective tissue, vascular congestion) than animals in the control group.

*Keywords: mesenchymal stem cells, bone regenerate*

**Introduction.** Injuries small animals, especially in cities, is quite common. For information E.I. Veremey, V.N. Lakisov in dogs it is 52.1% of surgical diseases. Among the various types of mechanical damage bone injuries (mainly in parts of the limbs) occurring in 44.5% of cases. Treatment of diseases damage the device movement in animals, because of anatomical features, presents a problem.

Many authors believe that the stimulation of bone formation remains a neglected and urgent problems of modern traumatology. Therefore, finding new ways to stimulate the regeneration of bone is a priority for research [1].

**Analysis of recent research and publications.** In practice veterinary experts often occur with injuries of different etiologies. Topical goal in the short term, with minimal

cost and impact on the body, reconstruct damaged tissue [5].

The use of stem cells in clinical practice veterinary medicine was made possible by a phenomenal discovery in biology and biotechnology related to the ability of stem cells after introducing them into the body of the recipient to enter a place of damaged tissues and restore cell structure. The installed capacity of stem cells differentiated in virtually all the specialized cells of the body and perform specific biological functions [3, 7, 8].

Researchers working mainly with embryonic stem cells and mesenchymal. Mesenchymal stem cells are found in the bone marrow stroma brain is one of the kinds of adult stem cells of animals. In particular, they were isolated from skeletal muscle, adipose tissue, lung, fetal liver, cord blood. They are referred to as multipotent cells that can

differentiate into cells of connective tissue, including bone, fat, cartilage and muscle tissue, so they are optimal for cell-regenerative treatment of damaged tissue above [2].

The best source of multipotent stem cells is bone marrow of animals. First of all, this is due to the availability of methods of obtaining the cells, its low invasiveness to the body sufficient opportunity and time to get the desired cellular material [3].

Since bone healing occurs with defect connective tissue replacement, our task is - multipotent stem cell transplantation, which will continue to own differentiated bone [4,6,9].

**The purpose of research** – of clinical and experimental study of reparative osteogenesis acceleration in the healing process after bone defect during treatment with allogeneic mesenchymal bone marrow stem cells.

**Materials and methods.** Animal experiments were performed according to the requirements of the “General ethics of animal experimentation,” approved by the National Congress on Bioethics (20/09/04 g., Kyiv, Ukraine) and consistent with the provisions “of the European Convention for the protection of vertebrate animals used for experimental and other scientific purposes” (Strasbourg, 1986)

In experiments using female rabbits aged 6 months with an average weight of 2.5 kg. Animals were divided into two groups of 3 animals each: first - control; second - research.

All manipulations with animals performed under general anesthesia. The defect in the region of the distal femur metaphysis animals trepanation formed by a metal cutter, which had a diameter of 3.5 mm and a retainer for limiting the depth of the hole is 1.5 mm. (Fig. 1.).

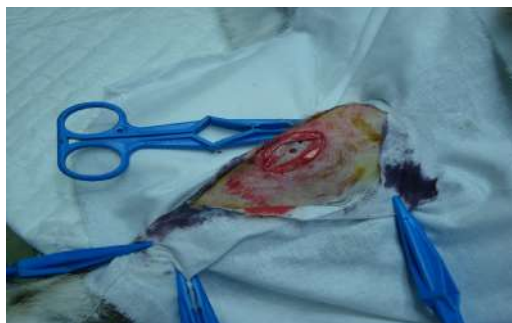The operation was conducted in compliance with all the rules of aseptic and antiseptic. Cutting of the skin and the muscles in the area between the m. rectus feoris and m. vactus lateralis. The size of surgical access was 3 cm .

Animals of the first group (control) after injury periosteum and bone tissue wound sewn without making cells. The animals of the experimental group in the area of the bone defect was injected allogeneic mesenchymal bone marrow stem cells in an amount of  $5 \times 10^6$  to hemostatic sponge “Helaspon” Manufacturer: Shoven ankerfarm GmbH, Germany, which is a biodegradable matrix (Fig. 2,3.).

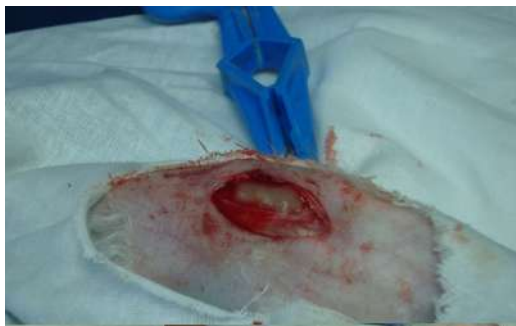Getting a bone marrow separation from his cell with high proliferative activity and culturing mesenchymal stem cells was performed according to the described methods [1].

Macroscopic and microscopic changes in the tissue of experimental animals studied 30 days after application of mechanical injury. After 30 days of experimental studies after injury, the animals in each group performed euthanasia of animals and femur fragments were taken for histological examination.

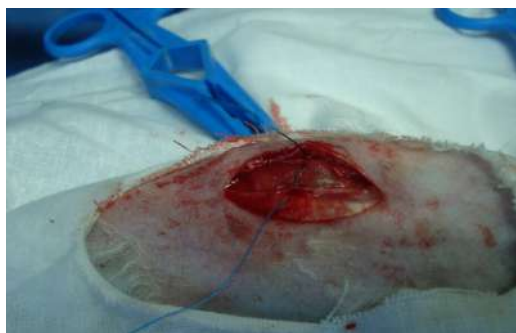Pieces of tissue for histological examination of the removed fragment excised femurs without crushing. Conducted formalin fixation, decalcification 5% nitric acid, fill in tseloyidyn; receiving sections 10 microns thick, staining was performed with hematoxylin-eosin and hematoxylin-pikrofuksynom by Van ghisoni. Histological and histomorphometrical study was performed on microscope Olympus CX31 and MBS-2. Measurement of the total area and volume of regenerate bone in it conducted with the use of ocular inserts square-sitchatoyi 196 section (14h14), mainly in series-adjacent fields of view.



**Fig. 1. Defect bone in the area of transition from the diaphysis to epiphysis**



**Fig. 2.** Introduction to the bone defect site allogeneic mesenchymal bone marrow stem cells in an amount of  $5 \times 10^6$  to hemostatic sponge «Helaspon» Manufacturer: Shoven ankerfarm GmbH, Germany, which is biodegradable matrix.

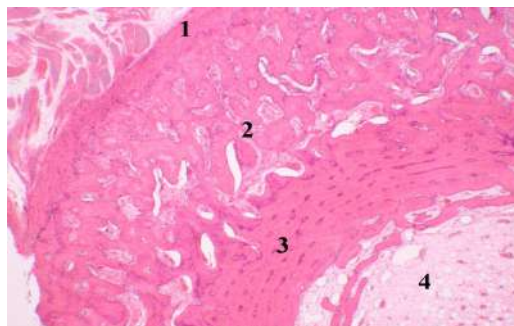


**Fig 3.** Suturing wounds

**Results and discussion.** Bone regenerate in both groups was compared characteristic histological picture, but some observed heterogeneity of structure. Specific quality features in the control and experimental groups or individual animals has been established, that the structure of bone and fibrous regenerate has one type.

In the control group of animals in the area regenerate damaged reveal that the morphological features reminiscent of spongy bone tissue. Osteon there were loosely arranged, in cross sections were round or irregular ellipse-shape (Fig. 4).

Calcium bone in the regenerate tissue in small quantities. Periosteum was the relatively thin layer of dense connective tissue fibers, the outer fibers were loosened in some plac-



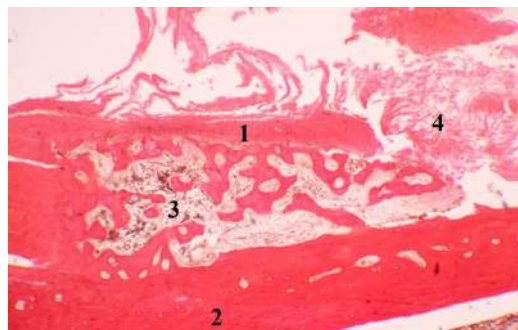
**Fig. 4.** Bone animals in the control group: 1 - periosteum (periosteum); 2 - spongy bone substance (spongiosis); 3 - compact bone substance; 4 - marrow. Painting with hematoxylin and eosin Karatsu x 40

es, in some areas periosteum was absent defect in these areas was closed growths loose connective tissue (Fig. 5, 6).

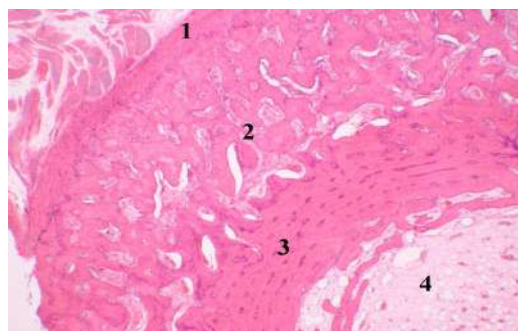
In preparations obtained from control animals number 2 layer regenerate relatively thin, no periosteum (Fig. 7,8).

In preparations obtained from control animals №3, regenerate the structure was a uniform arrangement of compact and spongy bone with fibrous layers of dense connective tissue. Histiocytic infiltration of fibrous dense connective tissue was absent, the blood vessels were filled with blood (hyperemic). In animals, the experimental group showed damage in the area regenerate, which had a structure similar to that of the control group animals. Plot regenerate was built mainly of cancellous bone, which forms the network structure of small trabecular bone, which showed a large number of osteoblasts and osteocytes (Fig. 9, 10).

Area of restored bone is much greater for such animals in the control group. This area was, in fact, fully formed callus. Osteon and Haversian canal in structure differed from that of the control group animals. In the area of regeneration showed a large amount of dense fibrous connective tissue, which formed a substantial thickness of layers between the elements of bone tissue. Bunches of connective tissue fibers are randomly directed, thick, sealed (Fig. 11).



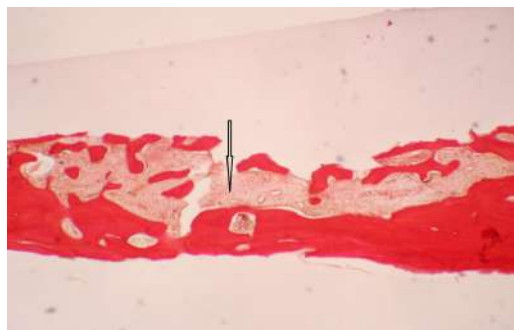
**Fig. 5. Bone animals in the control group: 1 - potonshe periosteum; 2 - compact bone substance; 3 - proliferation of fibrous connective tissue; 4 - closing the defect fibrous connective tissue. Van Gieson's stain, x 40**



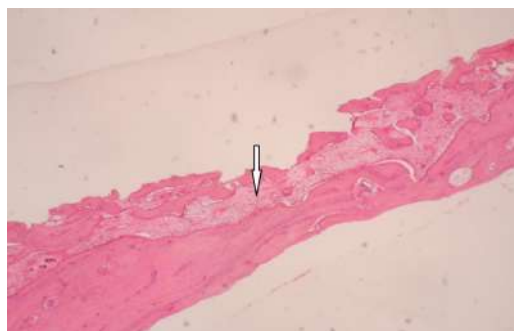
**Fig. 6. Bone animals in the control group. 1 - osteon; 2 - compact bone substance; 3 - proliferation of fibrous connective tissue; 4 - closing the defect fibrous connective tissue; 5 - histiocytic infiltration of fibrous connective tissue. Painting with hematoxylin and eosin Karatsu x 40**

In the connective tissue showed a large number of fibroblasts and fibrotytis. Periosteum was a thick layer of dense connective tissue fibers, fibers which adhere to one another. In formed bone observed a large amount of calcium deposits (Fig. 12).

Most clearly expressed a similar picture on the preparations obtained from animal experiments №2. Overall structure of regenerated land defect in tissue samples taken from the animals of experimental group, fully consistent with the normal structure of cancellous bone.



**Fig. 7. Bone animals in the control group. Tinned layer regenerate (arrow); no periosteum. Van Gieson's stain, x 40**

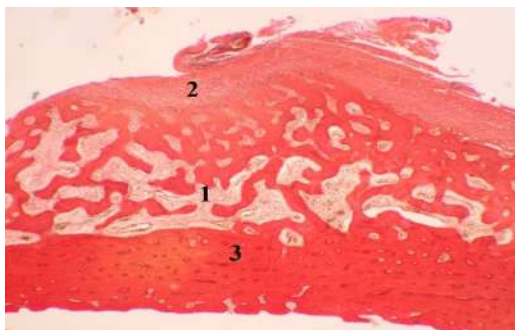


**Fig. 8. Bone animals in the control group. Tinned layer regenerate (arrow); no periosteum. Painting with hematoxylin and eosin Karatsu x 40**

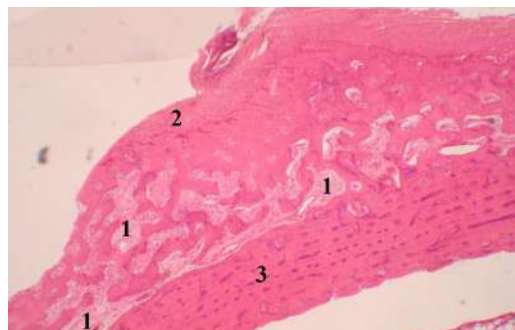
Conclusion and prospects for further research: the experimental group of animals regeneration of bone in the defect area occurred much faster and better than animals in the control group. This is evidenced by the following facts: regenerate a larger area compared to animals in the control group; more pronounced growth periosteum compared to animals in the control group; most calcium deposits intensity compared to animals in the control group; no pathological changes (histiocytic infiltration of fibrous connective tissue, vascular congestion) than animals in the control group.

Thus, the results of the studies indicate that mesenchymal stem cells are adminis-

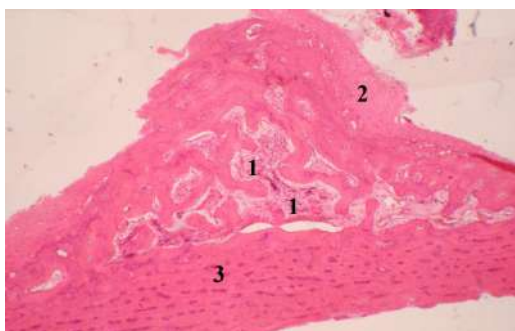




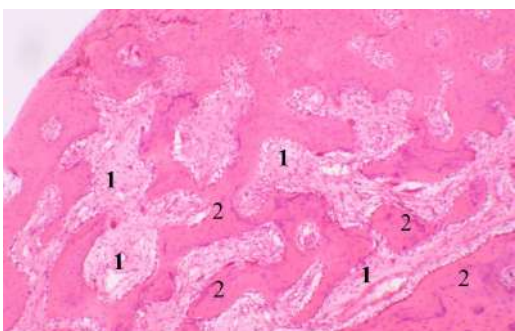
**Fig. 9. Bone animals of experimental group 1 – a well-developed layer of bone regenerate; 2 – periosteum; 3 – compact bone substance. Van Gieson's stain, x 40**



**Fig. 11. Bone animal research group. 1 – bundles of connective tissue fibers composed of bone regenerate; 2 – periosteum; 3 – compact bone substance. Painting with hematoxylin and eosin Karatsu x 40**



**Fig. 10. Bone animals of experimental group 1 – a well-developed layer of bone regenerate; 2 – periosteum; 3 – compact bone substance. Painting with hematoxylin and eosin Karatsu x 40**



**Fig. 12. Bone animal research group. 1 – bundles of connective tissue fibers composed of bone regenerate; 2 – massive deposits of calcium in bone tissue. Painting with hematoxylin and eosin Karatsu, x 100.**

tered in an amount of  $5 \times 10^6$  to hemostatic sponge «Helaspon» Manufacturer: Shoven ankerfarm GmbH, Germany, which is a biodegradable matrix in place of the defect

bone optimize the processes of reparative osteogenesis can therefore be used to acceleration of reparative osteogenesis during bone healing.

## References

1. Mazurkevych A. I., Kharkevych Yu. O., Maliuk M. O., Danilov V. B., Kovpak V. V., Zhurba V. I. (2010). Vplyv mezenkhimalnykh stovburovykh klityn kistkovoho mozku ta embrionalnykh fibroblastiv shchuriv na perebih reparatyvnykh protsesiv u yikhniishkiri. [Influence of mesenchymal barrel cages of marrow andembryo desmocytes of rats is on motion of репаративних processes in their skin] Naukovyi visnyk Natsionalnoho universytetu bioresursiv i pryrodokorystuvannya Ukrainy, 151, Ch 1.– S.197–205. (in Ukraine)
2. Mazurkevych A.I., Maliuk M.O., Tkachenko S.M., Kharkevych Yu.O.(2014). Vychennia biosumisnosti hemostatychnykh hubok iz stovburovymy klitynamy kistkovoho mozku krolia pid chas kultuvuvannya in vitro [Study of biocompatibility of гемостатичних sponges with thebarrel cages of marrow of кроля during cultivation of in vitro] Visnyk Sumskoho natsionalnoho ahrarnoho universytetu, Vyp.1(34), S. 7 – 11. (in Ukraine)

3. Mazurkevych A.I., Maliuk M.O., Danilov V.B. (2012). Metodichni rekomendatsii «Vykorystannia mezenkhimalnykh stovburovykh klityn dlia korektsii reparatyvnykh protsesiv v orhanizmi tvaryn-retsipiientiv» [Methodical recommendations "Use of mesenchymal stem cells for the correction of reparative processes in the organism of animals-recipients".]. Kyiv, S. 42. (in Ukraine)
4. Aggarwal S., Pittenger M.F. (2005). Human mesenchymal stem cells modulate allogeneic immune cell responses. *Blood*, 105, 1815–1822.
5. Augello A., Tasso R., Negrini S.M. (2005). Bone marrow mesenchymal progenitor cells inhibit lymphocyte proliferation by activation of the programmed death 1 pathway. *Eur. J. Immunol*, 35, 1482–1490
6. Mangashetti L. S. (2005). IL-4 inhibits bone-resorbing activity of mature osteoclasts by affecting NF-kappa B and Ca2+ signaling. *J. Immunol*, Vol. 175, 917–925.
7. Niemeyer P., Krause U., Kasten P. (2006). Mesenchymal Stem Cell-Based HLA-Independent Cell Therapy for Tissue Engineering of Bone and Cartilage. *Current Stem Cell Research and Therapy*, Vol. 1: 1, 21-27.
8. Quarto R., Mastrogiacomo M., Cancedda R., Kutepov S.M., Mukhachev V., Lavroukov A., Kon E., Marcacci M. (2001). Repair of large bone defects with the use of autologous bone marrow stromal cells. *N. Engl. J. Med.* – Vol. 344, N 5. – P. 385-386.
9. Roodman G. D. (1993). Role of cytokines in the regulation of bone resorption. *Calcif. Tissue Int.*, Vol. 53: 1, 94–98.

## АНОТАЦІЯ

**М. О. Малюк, М. А. Куліда, Я. К. Сердюков, А. В. Богославець.** Вплив мезенхімальних стовбурових клітин на репаративний остеогенез у тварин // *Biological Resources and Nature Managment.* – 2017. – 9, №1–2. – P.76–82.

Досліджено співвідношення структури кістково-фібринозного регенерату у кролів на фоні експериментального застосування алогенних мезенхімальних стовбурових клітин кісткового мозку з метою корекції репаративного процесу у кістковій тканині тварин.

Встановлено, що у тварин дослідної групи регенерація кісткової тканини в ділянці дефекту відбувалася значно швидше і повніше, аніж в тварин контрольної групи. Про це свідчать такі факти: більша площа регенерату порівняно з тваринами контрольної групи; більш виражений розвиток періосту порівняно з тваринами контрольної групи; більша інтенсивність відкладень солей кальцію порівняно з тваринами контрольної групи; відсутність патологічних змін (гістоцитарна інфільтрація волокнистої сполучної тканини, гіперемія судин) порівняно з тваринами контрольної групи.

**Ключові слова:** мезенхімальні стовбурові клітини, кістковий регенерат

## АННОТАЦИЯ

**Н. А. Малюк, М. А. Кулида, Я. К. Сердюков, А. В. Богославец.** Влияние мезенхимальных стволовых клеток на репаративный остеогенез у животных // *Биоресурсы и природопользование.* – 2017. – 9, №1–2. – С.76–82.

Исследовано соотношение структуры костно-фибринозного регенерата у кроликов на фоне экспериментального применения аллогенных мезенхимальных стволовых клеток костного мозга с целью коррекции репаративного процесса в костной ткани животных.

Установлено, что у животных контрольной группы, регенерация костной ткани в области дефекта происходила намного быстрее, нежели у животных контрольной группы. Об этом свидетельствуют следующие факты: большая площадь регенерата, в сравнении с животными контрольной группы; более выраженное развитие периоста, в сравнении с животными контрольной группы; большая интенсивность отложений солей кальция, в сравнении с животными контрольной группы; отсутствие патологических изменений (гистоцитарная инфильтрация волокнистой соединительной ткани, гиперемия сосудов) в сравнении с животными контрольной группы.

**Ключевые слова:** мезенхимальные стволовые клетки, костный регенерат