

Diagnostics of Severity of the Trigeminal Nerve Injuries During Jaws Surgeries

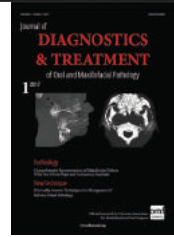Oleksii O. Tymofieiev^{1,*}, Natalia O. Ushko², Olena P. Vesova³, Mariia O. Yarifa⁴

¹ Chair of the Department of Maxillofacial Surgery, Stomatology Institute, Shupyk NMAPE, Kyiv, Ukraine (ScD, Prof)

² Department of Maxillofacial Surgery, Stomatology Institute, Shupyk NMAPE, Kyiv, Ukraine (PhD, Assoc Prof)

³ Department of Maxillofacial Surgery, Stomatology Institute, Shupyk NMAPE, Kyiv, Ukraine (ScD, Prof)

⁴ Oral and Maxillofacial Surgery Department, KMU of UAFM, Kyiv, Ukraine (PhD, Assoc Prof)



ABOUT ARTICLE

Article history:

Paper received 15 August 2016

Accepted 20 September 2016

Available online 18 February 2017

Keywords:

Electrophysiological indicators

Trigeminal nerve

Neurological complications

Neuropathy

Tumors of the jaws

Tumor-like lesions of the jaws

ABSTRACT

Purpose.

To study the dynamics of changes in the electrophysiological parameters of II and III branches of trigeminal nerve in patients after surgeries on tumors and tumor-like lesions of jaws; to define rehabilitation therapy depending on the severity of the nerve damage.

Material and methods.

Investigation and treatment of neurological complications in 179 patients after surgeries of removal for tumors and tumor-like lesions of the upper and lower jaws, on a hardware-software complex "DIN-1".

Results.

The values of the electrophysiological parameters of conductivity, resistance and tone of the trigeminal nerve branches in patients after surgeries on tumors and tumor-like lesions of jaws can be diagnostic criteria for the severity of the sensitive nerves damage in the surgical wound.

Conclusion.

Our data can be used as an objective prognostic test in oral and maxillofacial surgery for determination the severity of neurogenic damage to soft and bone tissues innervated by the trigeminal nerve.

© Diagnostics and Treatment of Oral and Maxillofacial Pathology. Published by OMF Publishing, LLC. All rights reserved.

Introduction

The analysis of postoperative complications in patients with maxillofacial pathology identifies a significant number of neurological symptoms, the occurrence of which is associated with anatomical characteristics of the structure of the middle and lower facial zones, the proximity of the exit places of the second and third branches of the trigeminal nerve from the skull and facial bones, trauma to the blood vessels that feed the nerve and, consequently, violation of its trophic [1-4].

We performed a review of local neurological complications that occur after surgeries of removal of tumors and tumor-like lesions of jaw bones.

If the surgical intervention is associated with the removal of tumor and tumor-like lesions of the mandible (Fig 1) and

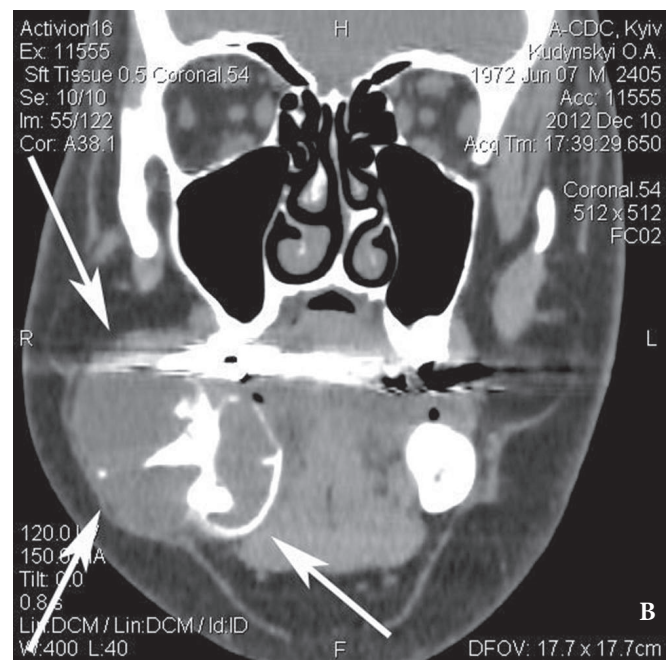
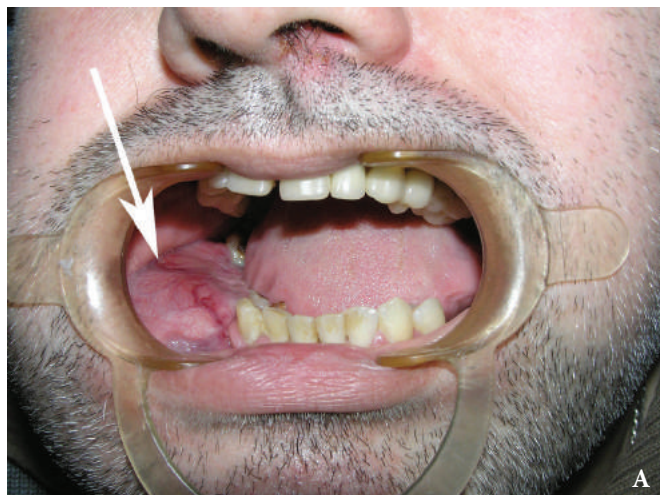

FIGURE 1. View of a 40-years-old male patient with ameloblastoma (arrow) of the right mandible (A). On coronal CT image (B), the tumor is marked by arrows.

* Corresponding author. Department of Maxillofacial Surgery, Stomatology Institute, Shupyk NMAPE, 4-a Pidvysotskogo Street, Kyiv 01103, Ukraine.
Tel., fax: +38 (044) 528 35 17. E-mail address: tymofeev@gmail.com (O.O. Tymofieiev)

maxilla (Fig 2), the injury of the trigeminal nerve of different degrees can happen. Therefore, in the postoperative period in operated patients a neuropathy of the corresponding trigeminal nerve branches of different severity and duration is present, which require adequate treatment [5, 6].

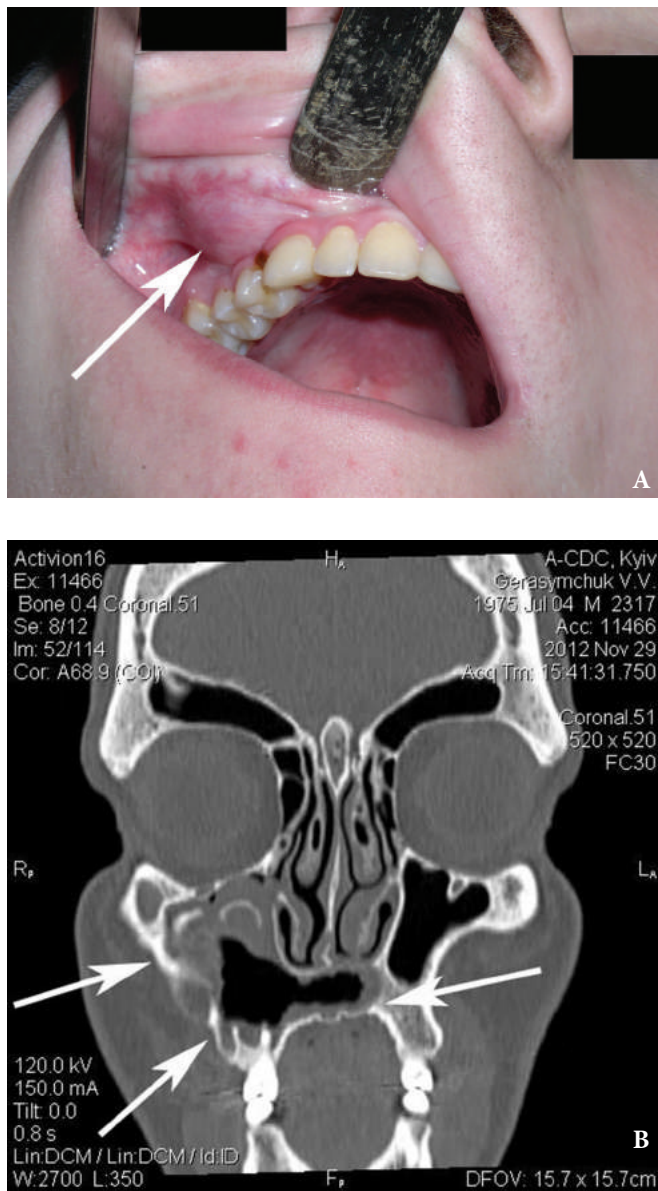


FIGURE 2. Intraoral view of 38-years-old male patient with ameloblastoma (arrow) of the maxilla (A). On coronal non-contrast CT image (B), the tumor is indicated by arrows.

We believe that in cases when during the operation, a doctor separates the lesion in the jaw from the branches of the trigeminal nerve slightly shifting the nerve is causing a minimal trauma, which, in our opinion, should be regarded as **contusion** (Fig 3A). In other cases, when the tumor or tumor-like lesions are located under nerve trunk (a branch), in order to identify and remove the pathological focus we have to relocate the branches of the trigeminal nerve, stretching them. This nerve injury we name **nerve stretching** (Fig 3B). In some cases upon surgical intervention a **partial and/or complete rupture** (Fig 3C) of the relevant branches of the trigeminal nerve may happened.

The purpose of the study was to investigate on hardware-software complex “DIN-1” the dynamics of changes in the electrophysiological parameters of soft tissues, innervated by

the II and III branches of trigeminal nerve in patients after surgical removal of tumors and tumor-like lesions of jaws depending on the severity of the nerve injury (contusion, stretching, incomplete and complete rupture of the nerve) that occurred during performance of the surgery.

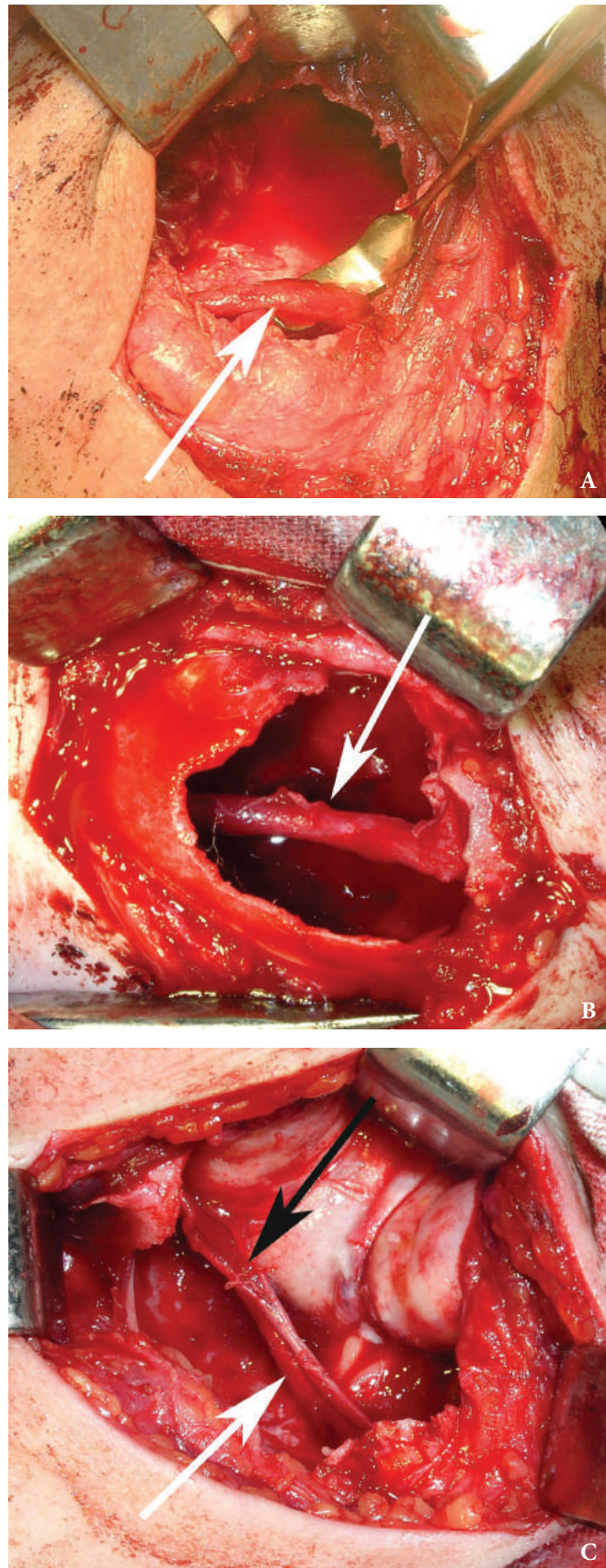


FIGURE 3. Intraoperative view of the nerve (white arrows): in case of contusion (A), in case of stretching (B), in case of partial rupture (C). Black arrow shows the place of incomplete nerve rupture.

Material and Methods

An investigation of neurological complications was performed in 179 patients after surgeries related to removal of tumors (ameloblastomas, osteoblastomas) (Fig 4) and tumor-like lesions (odontogenic keratocysts, radicular and follicular cysts, etc.) of upper and lower jaws. All patients received surgery and postoperative medical treatment at the Department of Maxillofacial Surgery, Shupyk National Medical Academy of Postgraduate Education.

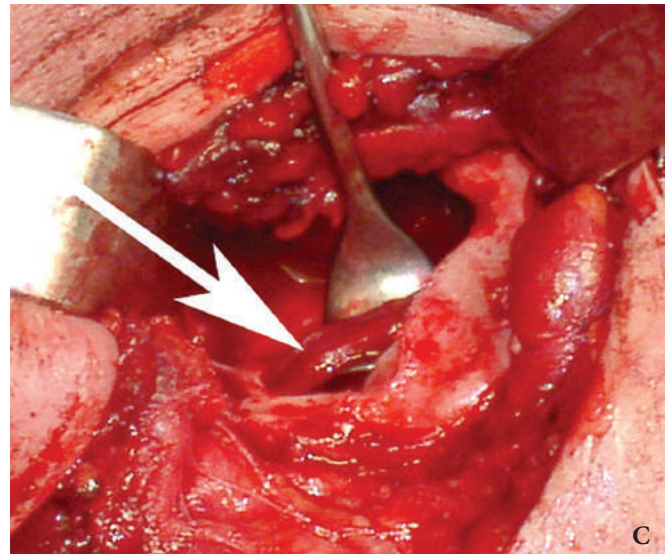
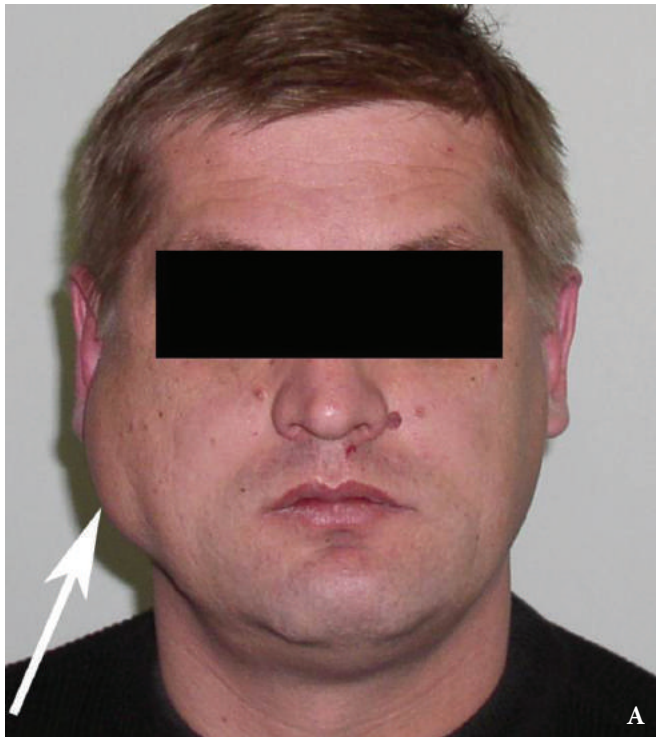
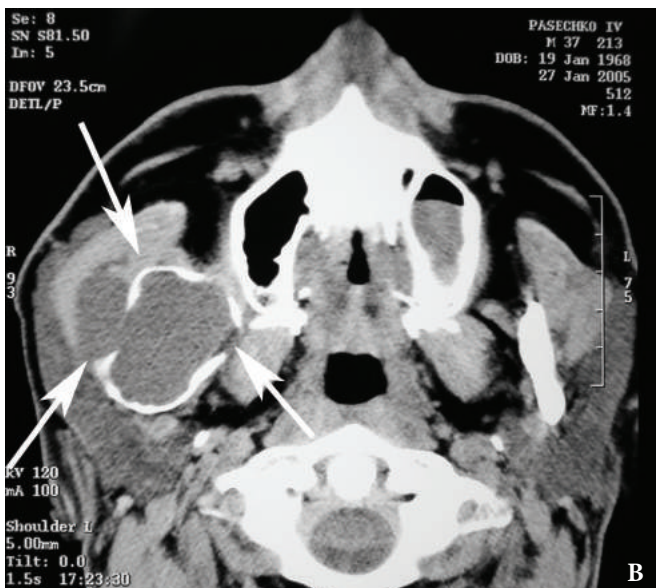
FIGURE 4. View of 37-years-old man with ameloblastoma (arrow) of the right mandible (A). The tumor on axial CT scan (B) is indicated by arrows. View of inferior alveolar nerve (arrow) during the surgery (C).



The control group consisted of 35 persons – practically healthy people (without pathological changes in the oral and maxillofacial region). In those individuals we have identified electrophysiological parameters of soft tissues, innervated by the II and III branches of the trigeminal nerve.

All patients were divided into 4 groups: I group – 47 patients (for 23 patients surgery done on the maxilla and

for 24 – on the mandible) after surgery in which there was a light injury to trigeminal nerve branches which we have described as a nerve contusion; group II – 57 patients (for 26 patients the surgery was performed on the maxilla, and for 31 people – on the mandible), in those patients was observed a stretching of the branches of the trigeminal nerve during the separation of tumors or tumor-like lesions; group III – 53 patients (for 21 the surgeries were performed on the maxilla and for 32 – on the mandible), in which was observed a partial (incomplete) rupture of one of the branches of the

trigeminal nerve during the removal of the pathological lesion (tumor or tumor-like lesion); IV group – 32 patients (for 17 the surgery were performed on the maxilla, and for 15 – on the mandible) after surgery (resection of the jaw), in which there was a complete rupture of one of the branches of the trigeminal nerve during the removal of the pathological lesion (tumor or tumor-like lesions).

All patients underwent clinical examination methods, which included: general surveying, palpation, medical history, determining sensitivity (pain, tactile and thermal sensitivity) of the corresponding areas innervated by the II and III branches of the trigeminal nerve, x-rays of the jaws, etc.

After performing appropriate surgery the selection of patients with postoperative damage to the trigeminal nerve branches was carried out. To measure the static and dynamic parameters of areas of the soft tissues that are innervated by the trigeminal nerve, hardware-software complex “DIN-1” (Fig 5) was used. General surveying of patients was carried out at the following exit points of the trigeminal nerve: mental, infraorbital (was determined the conductivity, resistance and tone to the nerve). Examination was carried out on the computer and then recording the obtained data. All special methods of examination of the trigeminal nerve were performed during hospitalization and in the dynamics of the postoperative period.

All received digital data were processed by variational-statistical method with the calculation of Student's test. Changes of electrophysiological parameters in the dynamics



FIGURE 5. View of hardware-software complex “DIN-1”.

of examination of patients (postoperative) were compared with the norm, i.e. indicators identified in healthy people. The indicators were considered significant at $p < 0.05$.

Results and Discussion

Performing the investigation of practically healthy people (without pathology in the maxillofacial region) the static and dynamic indicators of the soft tissues, innervated by the II (in infraorbital measuring position) and III branches of the trigeminal nerve (in the mental measuring position), were determined. The indicants of resistance and tonus of the nerve have been measured. For the II branch the indicants of conductivity were 113.0 ± 2.8 conventional units (CU), resistance – 5.0 ± 0.7 CU and tone – 2.20 ± 1 CU. For the III branch the indicants were 113.0 ± 2.8 CU, resistance – 5.00 ± 7 CU and tone – 2.2 ± 0.1 CU. Thus, the indicants of conductivity, resistance and tonus of II and III branches of the trigeminal nerve in healthy people were almost the same.

In patients of I study group (**contusion of the trigeminal nerve**) in the dynamics of the investigation (postoperative), we found the loss of pain, tactile and thermal sensitivity of the skin and mucosa of the oral cavity of different severity, and these changes of sensitivity we consider in our research. In this study we present the changes in electrophysiological parameters of the branches of the trigeminal nerve in the dynamics of postoperative period. The indicants of conductivity (Fig 6) upon hospitalization (before surgery) were 115.1 ± 3.1 CU ($p > 0.05$), a day after surgery 77.3 ± 4.2 CU ($p < 0.001$), after 3 days – 82.4 ± 4.5 CU ($p < 0.001$), 7-8 days after surgery – 88.2 ± 3.7 CU ($p < 0.001$), after 14-15 days (two weeks) – 90.2 ± 3.2 CU ($p < 0.001$), 1 month – 109.2 ± 5.0 CU ($p > 0.05$). Resistance (Fig 7) upon the hospitalization corresponded to 5.6 ± 2.2 CU ($p > 0.05$), a day after the surgery the resistance was minus 2.5 ± 1.7 CU ($p < 0.001$), after 3 days – minus 8.6 ± 4.1 CU ($p < 0.001$), after 7-8 days

after surgery – minus 2.9 ± 0.9 CU ($p < 0.001$), after 14-15 days (two weeks) – 3.1 ± 0.3 CU ($p < 0.05$), after 1 month 4.6 ± 2.3 CU ($p > 0.05$). The tone (Fig 8) upon the hospitalization was equal to 2.3 ± 0.3 CU ($p > 0.05$), a day after the surgery, the tone was 2.40 ± 5 CU ($p > 0.05$), after 3 days – 2.00 ± 5 CU ($p > 0.05$), after 7-8 days after surgery – 2.2 ± 0.4 CU ($p > 0.05$), after 14-15 days (two weeks) – 2.30 ± 4 CU ($p > 0.05$).

Thus, the conductivity and resistance of II and III branches of the trigeminal nerve within the first three days after the surgery reached a maximum change (decrease) of the studied parameters, and after 1 month the indicants of conductivity and resistance returned to normal. Increased tone of II and III branches of the trigeminal nerve was not significantly changed throughout the period of examination of patients of the I study group.

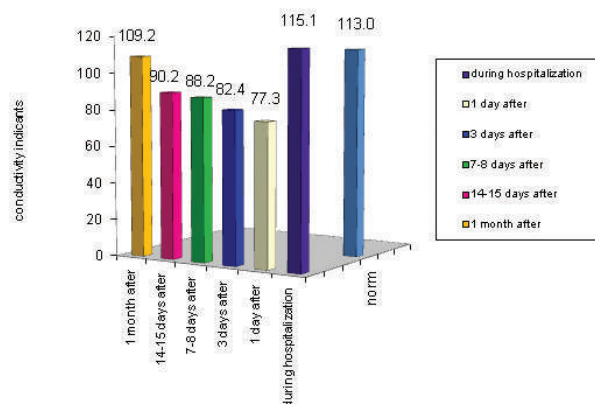


FIGURE 6. The conductivity indicators of the trigeminal nerve branches in patients of the I study group.

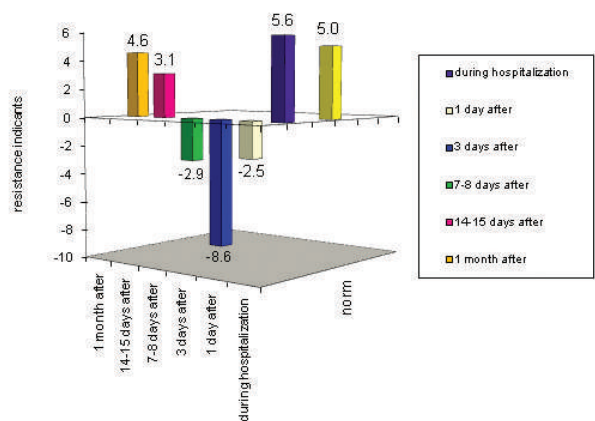


FIGURE 7. A resistance indicators of the trigeminal nerve branches in patients of I study group.

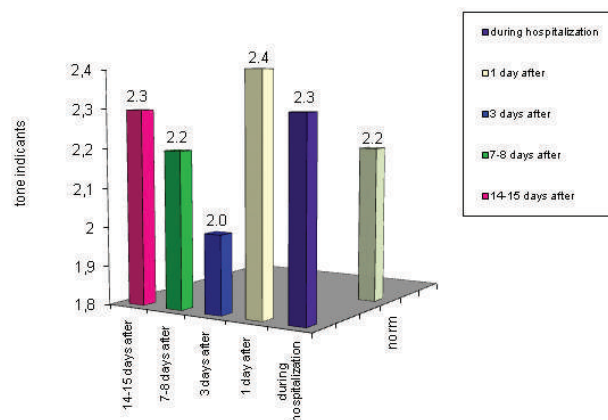


FIGURE 8. A tone indicators of the trigeminal nerve branches in patients of the I study group.

Examining patients of II study group (**stretching of the trigeminal nerve**) we also noted the change of pain, tactile and thermal sensitivity of the skin and mucosa of the oral cavity of different severity. Electrophysiological indicants of the branches of trigeminal nerve changed in the dynamics of the investigation. The conductivity (Fig 9) upon hospitalization (before surgery) was 119.4 ± 3.1 CU ($p > 0.05$), a day after surgery – 66.34 ± 6 CU ($p < 0.001$), 3 days after surgery – 78.4 ± 4.2 CU ($p < 0.001$), 7-8 days after surgery – 83.3 ± 3.4 CU ($p < 0.001$), after 3-4 weeks – 88.4 ± 3.2 CU ($p < 0.001$), and in 2 months – 118.5 ± 7.9 CU ($p > 0.05$). A resistance (Fig 10) upon hospitalization was 7.2 ± 1.9 CU ($p > 0.05$), a day after the surgery, the resistance was minus 6.7 ± 2.4 CU ($p < 0.001$), after 3 days – minus of 13.1 ± 3.9 CU ($p < 0.001$), after 7-8 days after surgery – minus 18.9 ± 2.9 CU ($p < 0.001$), after 3-4 weeks – minus 3.8 ± 1.6

CU ($p < 0.001$), after 2 months – 6.8 ± 4.8 CU ($p > 0.05$). A tone (Fig 11) upon hospitalization was 2.5 ± 0.3 CU ($p > 0.05$), a day after surgery, was 2.4 ± 0.3 CU ($p > 0.05$), after 3 days – 2.6 ± 0.4 CU ($p > 0.05$), 7-8 days after surgery – 2.6 ± 0.5 CU ($p > 0.05$), 3-4 weeks after surgery – 2.3 ± 0.3 CU ($p > 0.05$), 2 months after surgery was 2.4 ± 0.5 CU ($p > 0.05$).

Thus, the conductivity and resistance of the II and III branches of the trigeminal nerve within the first three days in patients of II study group (with the stretching of the branches of the trigeminal nerve) reached the maximum changes (reductions) in these indicants and only 2 months after the surgery indicants have been normalized. Increased tonus of II and III branches of the trigeminal nerve was not significantly changed throughout the period of examination inpatients of II study group.

Through analysis of the changes of electrophysiological parameters of II and III branches of trigeminal nerve in patients of II study group (with stretching branches of the trigeminal nerve) after surgery it was found that, the heavier the surgery was in this group, the result were neurological symptoms from trigeminal nerve and more the conductivity and resistance deviate from the norm, i.e. reduced.

During treatment of the III study group of patients (**partial or incomplete rupture of one of the trigeminal nerve branches**) we noted the change of pain, tactile and thermal sensitivity of the skin and mucosa of the oral cavity of different severity. Electrophysiological indicants of the trigeminal nerve branches changed in the dynamics of investigation. The conductivity (Fig 12) upon hospitalization (before surgery) was 120.2 ± 5.8 CU ($p > 0.05$), 3 days after surgery – 65.2 ± 8.6 CU ($p < 0.001$), after 14-15 days – 73.4 ± 9.2 CU ($p < 0.001$), 1 month after surgery – 79.3 ± 8.3 CU ($p < 0.001$) after 3 months – 82.2 ± 11.3 CU ($p < 0.02$), 6 months – 107.5 ± 11.2 CU ($p > 0.05$). Resistance (Fig 13) upon hospitalization was equal to 5.9 ± 0.8 CU ($p > 0.05$), through 3 days after surgery the resistance was minus 9.7 ± 4.3 CU ($p < 0.001$), after 14-15 days – minus 10.6 ± 4.9 CU ($p < 0.001$), 1 month after surgery – minus 7.9 ± 4.7 CU ($p < 0.001$), after 3 months – minus 2.2 ± 1.9 CU ($p < 0.01$), after 6 months – 3.6 ± 4.2 CU ($p > 0.05$). The tone (Fig 14) upon hospitalization was 2.1 ± 0.2 CU ($p > 0.05$), through 3 days after surgery the tone was 2.9 ± 0.2 CU ($p < 0.001$), after 14-15 days – 3.1 ± 0.3 CU ($p < 0.001$), 1 month after surgery was 2.8 ± 0.2 CU ($p < 0.01$), after 3 months – 2.5 ± 0.1 CU ($p < 0.05$), after 6 month – 2.3 ± 0.5 CU ($p > 0.05$).

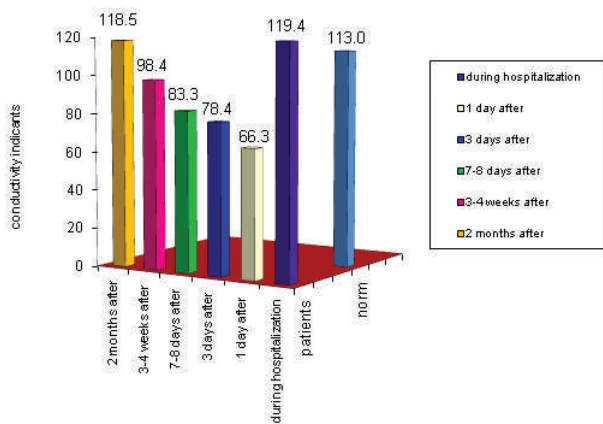


FIGURE 9. The conductivity indicants of the trigeminal nerve branches in patients of the II study group.

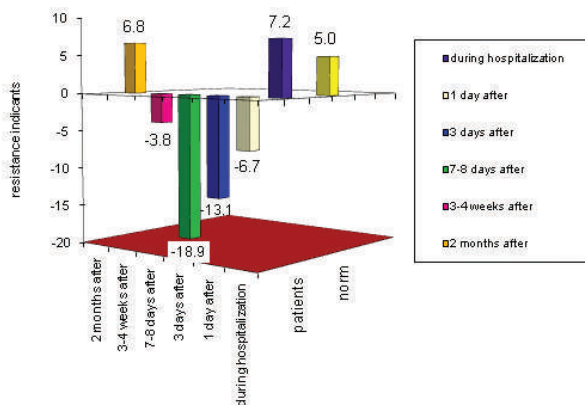


FIGURE 10. The resistance indicants of the trigeminal nerve branches in patients of II study group.

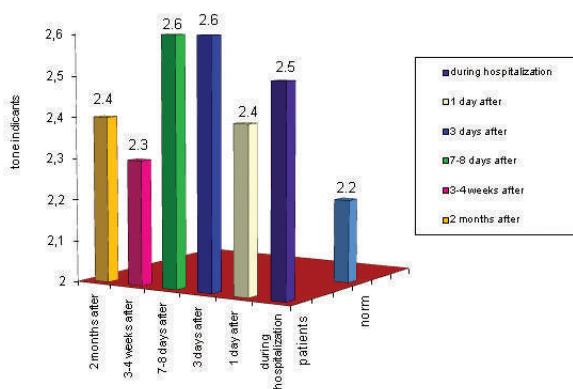


FIGURE 11. The tone indicants of the trigeminal nerve branches in patients of II study group.

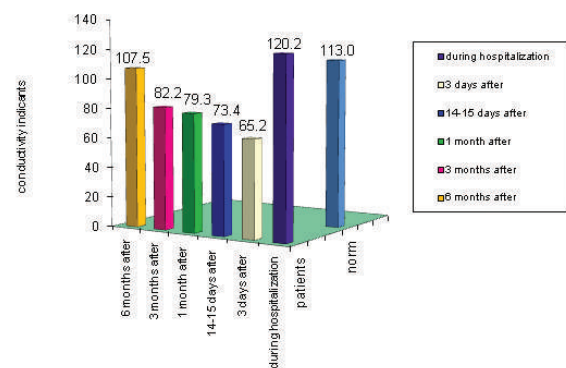


FIGURE 12. The conductivity indicants of the trigeminal nerve branches in patients of III study group.

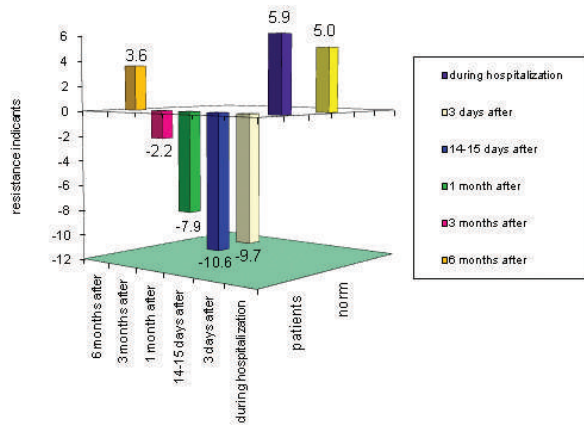


FIGURE 13. The resistance indicants of the trigeminal nerve branches in patients of III study group.

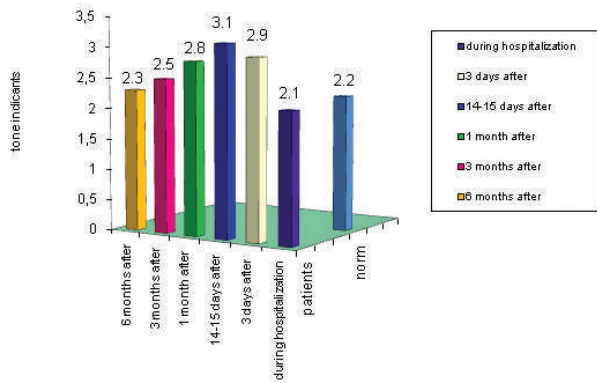


FIGURE 14. The tone indicants of the trigeminal nerve branches in patients of III study group.

Analysing the conductivity and resistance of the trigeminal nerve branches in patients of III study group (**partial rupture of any branch of the trigeminal nerve**) after surgery we found a significant decrease in these indicants. And they were very low during the first month after surgery in all patients of this study group. Then there was a slow and gradual increase of conductivity and resistance with its normalization to the 6th month after surgery. The tone of the trigeminal nerve branches was significantly increased. The highest data rates were on 14-15 days after surgery. The tone normalization occurred at the 6th month after surgery.

The heavier the surgeries were in patient of III study group (**partial or incomplete nerve rupture**), resulted in neurological symptoms from trigeminal nerve, the greater and more authentic a deviation from the norm of the conductivity, resistance and tone. Normalization of all the electrophysiological indicants was occurred only 6 months after surgery.

During examination of patients of IV study group (a complete rupture of one of the trigeminal nerve branches), we found a significant change in pain, tactile and thermal sensitivity of the skin and mucosa of the oral cavity of different severity. Electrophysiological indicants of the trigeminal nerve branches changed in the dynamics of investigation. The conductivity (Fig 15) upon hospitalization (before surgery) was 117.2 ± 5.6 CU ($p > 0.05$), 3 days after surgery – 58.5 ± 6.8 CU ($p < 0.001$), after 14-15 days – 44.9 ± 8.3 CU ($p < 0.001$), 1 month after surgery – 49.6 ± 6.7 CU ($p < 0.001$) after 3 months – 51.2 ± 7.9 CU ($p < 0.001$), after 6 months – 56.9 ± 12.8 CU ($p < 0.001$). Resistance (Fig 16) at hospitalization was equal to 5.6 ± 0.9 CU

($p > 0.05$), through 3 days after surgery the resistance was minus 23.8 ± 3.4 CU ($p < 0.001$), after 14-15 days – minus 29.8 ± 5.9 CU ($p < 0.001$), 1 month after surgery – minus 33.9 ± 5.2 CU ($p < 0.001$), after 3 months – minus 34.4 ± 6.3 CU ($p < 0.001$), after 6 months – minus 31.5 ± 11.9 CU ($p < 0.001$).

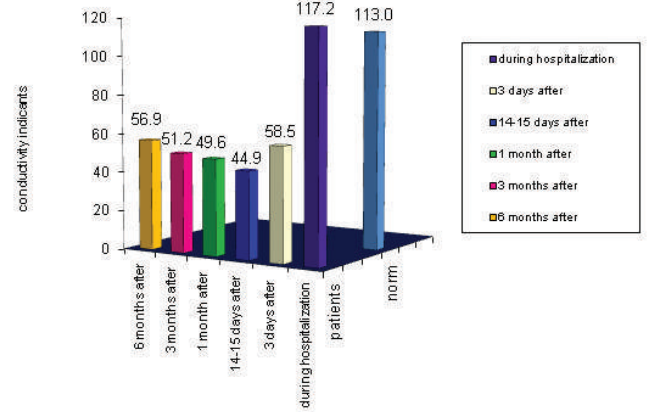


FIGURE 15. The conductivity indicants of the trigeminal nerve branches in patients of IV study group.

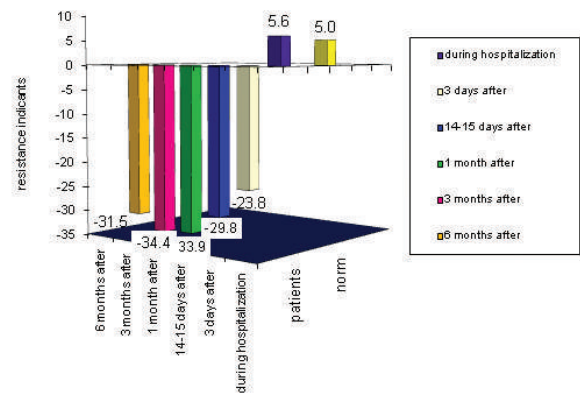


FIGURE 16. The resistance indicants of the trigeminal nerve branches in patients of IV study group.

Indicants of tonus (Fig 17) upon hospitalization was equal to 2.2 ± 0.1 CU ($p > 0.05$), through 3 days after surgery the tone was 2.9 ± 0.3 CU ($p < 0.001$), after 14-15 days – 3.5 ± 0.2 CU ($p < 0.001$), 1 month after surgery – 3.8 ± 0.3 CU ($p < 0.001$), after 3 months – 3.6 ± 0.3 CU ($p < 0.001$), after 6 months – 3.3 ± 0.2 CU ($p < 0.001$).

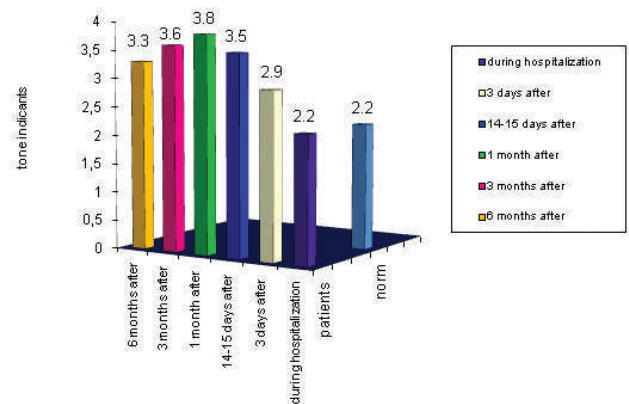


FIGURE 17. The tone indicants of the trigeminal nerve branches in patients of IV study group.

Analysing the conductivity and resistance of the trigeminal nerve branches in patients of IV study group (with complete rupture of II or III branch of the trigeminal nerve) after surgery we noted that on the 3rd day after surgery a significant decrease of these indicants occurred, which remained significantly low at 3-6 months after surgery. Increased tone of the trigeminal nerve branches was significantly increased and the highest data rates were 1 month after surgery. Normalization of conductivity, resistance and tone were not occurred within 6 months after surgery.

Research of heavier proceeded surgery of patient IV study group (nerve damage) the resulted in a clinical neurological symptoms from trigeminal nerve and the greater was deviation from the norm of the conductivity, resistance and tone. According to our observations, the normalization of electrophysiological indicants of conductivity, resistance and tone does not occur even at 8-12 months after surgery.

Summarizing conclusions, we found that upon the injury II and III branches of the trigeminal nerve (I study group) after surgery the conductivity and resistance were significantly decreased (in comparison with healthy people) and during the first three days after surgery they had reached the maximum of their changes. Significantly low conductivity and resistance were noted within 14-15 days after surgery. An investigation on hardware-software complex "DIN-1" set the normalization of conductivity and resistance at 1 month after surgery. Increased tone upon the injury of II and III branches of the trigeminal nerve was not significantly changed throughout the postoperative period in patients of I study group.

Upon stretching of II and III branches of the trigeminal nerve (II study group) the conductivity and resistance was significantly decreased (compared to the norm, i.e., healthy people) for the first three days after surgery. Significantly low conductivity and resistance were noted during 1-1.5 months after surgery. The investigation with the use of a hardware-software complex "DIN-1" set the normalization of conductivity and resistance after 2 months after surgery. Increased tonus upon the stretching of the II and III branches of the trigeminal nerve was not significantly changed throughout the period of examination of patients of II study group. It should be noted that the sensitivity recovery of the skin and mucous membranes of the oral cavity in the region of surgery also occurred in the specified time, i.e. 2 months after operation.

When partial (incomplete) rupture II and III branches of the trigeminal nerve (III study group) occurs, a significant decrease of conductivity and resistance after surgery were noted. On 14-15 days after surgery noticed a maximum reduction in the incidence of resistance and conductivity.

Further, it was observed a slow and gradual increase of these indicants, but they remained significantly low for 3 months. The tonus indicants upon the incomplete (partial) rupture of the trigeminal nerve branches were significantly increased. The highest data rates were also at 14-15 days after surgery. An investigation on hardware-software complex "DIN-1" set the normalization of all studied indicants just 6 months after the surgery. Changes of all types of sensitivity of skin and mucous membranes of the oral cavity in the field of surgery within a specified time, i.e. 6 months after the surgery, has not recovered despite the normalization of electrophysiological

indicants. Complete recovery of all types of sensitivity in case of partial (incomplete) rupture of branches of the trigeminal nerve was occurred not earlier than after 8-9 months after surgery.

In a complete rupture the II and III branches of the trigeminal nerve (IV study group) in the postoperative period there was a simultaneous significant decrease of conductivity and resistance, and the rate of the tonus – on the contrary – was significantly increased compared with healthy people (norm). The lowest possible (conductivity and resistance) and the highest (tone), these figures were not just for 14-15 days after surgery, but in the following months surveys. The normalization of electrophysiological indicants (according to the hardware-software complex "DIN-1") conductivity, resistance and tonus of the soft tissues, innervated by the affected branches of the trigeminal nerve, was observed even for 6-8-12 months after surgery. It is established that the heavier the proceeded operation associated with removal of a tumor or tumor-like lesions of the jaws from the surveyed of this study group was, the result was a neurological clinical symptoms from the relevant branches of the trigeminal nerve and highes were deviations of the conductivity, resistance and tonus. Recovery of all types of sensitivity of skin and mucosal membranes after complete rupture of the trigeminal nerve branches occurred uniformly and not for all investigated samples.

Conclusions

Based on the performed investigation it was found that the determination of soft tissues electrophysiological indicants, innervated by the II and III branches of the trigeminal nerve in patients after surgery on removal of benign tumors of the jaws, is not only a diagnostic criteria of the severity of the trigeminal nerve injury in the surgical wound, but also can serve as a prognostic index that indicants the timing of sensitivity recovery of the skin and mucous membranes in the area of surgery.

Upon contusion and stretching of the trigeminal nerve branches a significant reduction in conductivity and resistance in the first few days after surgery is observed. Recovery (normalization) of the electrophysiological parameters upon contusion and stretching of the trigeminal nerve branches occurs in 1 or 2 months (respectively) after surgery.

If in the postoperative period a significant decreasing of conductivity and resistance, and significantly increasing of indicant tonus are observed it's indicates the injury to the trigeminal nerve branches in form of partial or complete rupture. Recovery (normalization) of all the studied electrophysiological parameters upon incomplete (partial) rupture of the trigeminal nerve branches occurs within 6 months after surgery. Upon the complete rupture of the trigeminal nerve branches the normalization of electrophysiological parameters of the trigeminal nerve does not occur within 8-12 months after surgery.

Thus, the study of electrophysiological indicants of the trigeminal nerve (conductivity, resistance, and tone) in the postoperative period has both diagnostic and prognostic value. The results that were achieved in this study can be used in maxillofacial and oral surgery.

References

1. Vesova O. Porazhenie troichnogo nerva pry neopuholevyh zabolevaniyah chelistno-litsevoy oblasti: mehanizmy vozniknoveniya, diahnozyka, obosnovanie lecheniya: diss. Na soiskanie uch. Stepeni d. med. n.: spez. 14.01.22 "Stomatolohiya" [The injury of the trigeminal nerve in cases of nonneoplastic diseases of maxillofacial area: mechanisms of emergence, diagnostics, explanation of treatment: medical doctoral thesis: qualification 14.01.22 "Stomatology"] Kiev, 2013. 425 p. (in Russian)
2. Tymofieiev OO, Vesova OP, Lesnuhin VL. Otsenka tyazhesti povrezhdeniya vetvei troichnogo nerva u bolnoho s perelomamy cheliustey I skulovoho kompleksa [Estimation of the injury degrees of the trigeminal nerve branches in patients with jaw and malar complex fractures]. *Sovremennaia stomatologia* [Modern stomatology] 2004;4:92–4 (in Russian).
3. Tymofieiev OO. Rukovodstvo po chelistno-litsevoi hirurhii i hirurgicheskoi stomatologii [Manual of maxillofacial and oral surgery]. 5th ed. Kyiv: Chervona Ruta-Turs; 2012. p. 1048 (in Russian).
4. Tymofieiev OO., Vesova OP, et al. Symptom "Nozhnyits" – objektivnyi prognosticheskyi test nevrohennyh ismeneniy v chelyustno-litsevoi oblasti [Symptom of "scissors" – objective prognostic test neurogenic changes in maxillofacial area]. *Sovremennaia stomatologia* [Modern stomatology] 2005;4:100–6 (in Russian).
5. Tymofieiev OO, et al. Symptom Vensana – osobennosti klinicheskoho proyavleniya i mehanizm eho rasvitiya [Symptom Vensana – specific of its clinical implications and the mechanism of its development]. *Sovremennaia stomatologia* [Modern stomatology] 2004;3:93–7 (in Russian).
6. Tymofieiev OO. Chelyusno-litsevaya hirurhiya [Maxillofacial surgery] 2nd ed. Kyiv: Meditsina; 2015. 800 p. (in Russian).

Tymofieiev OO, Ushko NO, Vesova OP, Yarif MO.
Diagnostics of severity of the trigeminal nerve injuries during jaws surgeries.
J Diagn Treat Oral Maxillofac Pathol 2017;1:32–9.

Діагностика тяжкості травми трійчастого нерва при операціях на щелепах

Олекій О. Тимофєєв¹, Наталія О. Ушко², Олена П. Весова³, Марія О. Ярифа⁴

¹ Завідувач кафедри щелепно-лицевої хірургії ІС Національної медичної академії післядипломної освіти імені П.Л. Шупика, д. мед. н., професор, Заслужений діяч науки і техніки України, Київ, Україна.

² Доцент кафедри щелепно-лицевої хірургії ІС Національної медичної академії післядипломної освіти імені П.Л. Шупика, к. мед. н., доцент, Київ, Україна.

³ Професор кафедри щелепно-лицевої хірургії ІС Національної медичної академії післядипломної освіти імені П.Л. Шупика, к. мед. н., професор, Київ, Україна.

⁴ Доцент кафедри хірургічної стоматології та щелепно-лицевої хірургії КМУ УАНМ, к. мед. н., доцент, Київ, Україна.

ПРО СТАТТЮ

Історія рукопису:

Отриманий: 07 жовтня 2016

Прийнятий: 10 грудня 2016

Онлайн з: 18 лютого 2017

Ключові слова:

Електрофізіологічні показники
Трійчастий нерв
Неврологічні ускладнення
Нейропатії
Пухлини щелеп
Пухлиноподібні утворення щелеп

РЕЗЮМЕ

Мета. Вивчити динаміку змін електрофізіологічних показників II і III гілок трійчастого нерва у хворих після проведення операцій видалення пухлин і пухлиноподібних утворень щелеп; визначити реабілітаційні можливості лікаря в залежності від важкості ушкодження нерва.

Методи. Проведено обстеження та лікування неврологічних ускладнень у 179 хворих після проведення оперативних втручань, пов'язаних з видаленням пухлин і пухлиноподібних утворень верхньої та нижньої щелеп, на апаратно-програмному комплексі "ДНН-1".

Результати. На підставі проведеного обстеження встановлено, що величини електрофізіологічних показників провідності, резистентності і тонуся гілок трійчастого нерва у хворих після проведених операцій видалення пухлин і пухлиноподібних утворень щелеп можуть бути діагностичними критеріями важкості ушкодження нерва в операційній рані.

Висновки. Отримані нами дані можна використовувати як об'єктивний прогностичний тест в щелепно-лицевій хірургії та хірургічній стоматології для визначення ступеню вираженості неврогенних ушкоджень у м'яких і кісткових тканинах, що іннервуються трійчастим нервом.

Діагностика тяжкості травми трійчастого нерва при операціях на щелепах

Алексеї А. Тимофєєв¹, Наталія А. Ушко², Елена П. Весова³, Мария А. Ярифа⁴

¹ Завідувач кафедри щелепно-лицевої хірургії ІСНМАПО імені П.Л. Шупика, д. мед. н., професор, Заслуженный деятель науки и техники Украины, Киев, Украина.

² Доцент кафедры щелепно-лицевої хірургії ІС НМАПО імені П.Л. Шупика, к. мед. н., доцент, Киев, Украина.

³ Професор кафедри щелепно-лицевої хірургії ІС НМАПО імені П.Л. Шупика, д. мед. н., професор, Киев, Украина.

⁴ Доцент кафедри хірургічної стоматології та щелепно-лицевої хірургії КМУ УАНМ, к. мед. н., доцент, Киев, Украина.

О СТАТЬЕ

История рукописи:

Получена: 07 октября 2016

Принята: 10 декабря 2016

Онлайн с: 18 февраля 2017

Ключевые слова:

Электрофизиологические показатели
Тройничный нерв
Неврологические осложнения
Нейропатии
Опухоли челюстей
Опухолеподобные образования челюстей

РЕЗЮМЕ

Цель. Изучить динамику изменений электрофизиологических показателей II и III ветвей тройничного нерва у больных после проведения операций удаления опухолей и опухолеподобных образований челюстей; определить реабилитационные возможности врача в зависимости от тяжести повреждения нерва.

Методы. Проведено обследование и лечение неврологических осложнений у 179 больных после проведения оперативных вмешательств, связанных с удалением опухолей и опухолеподобных образований верхней и нижней челюстей, на аппаратно-программном комплексе "ДИН-1".

Результаты. На основании проведенного обследования установлено, что величины электрофизиологических показателей проводимости, резистентности и тонуся ветвей тройничного нерва у больных после проведенных операций удаления опухолей и опухолеподобных образований челюстей могут являться диагностическими критериями тяжести повреждения чувствительного нерва в операционной ране.

Выводы. Полученные нами данные можно использовать как объективный прогностический тест в челюстно-лицевой хирургии и хирургической стоматологии для определения степени выраженности неврогенных повреждений в мягких и костных тканях, иннервируемых тройничным нервом.