

Investigation of the influence of magnesium ions on the morphofunctional state of the thyroid gland of adult rats

R.V. Yanko

O.O. Bogomoletz Institute of Physiology, Nat. Acad. Sci. of Ukraine

Abstract. Purpose — to investigate the effect of magnesium chloride on the morphometric parameters of the thyroid gland functional state of the adult rats. **Materials and methods.** The study was conducted on 24 male Wistar rats at the age of 15 months. Experimental rats orally received magnesium chloride daily at a dose of 50 mg/kg body weight. Duration of experiment was 21 days. From thyroid tissue preparations were made according to standard histological methods. Gland morphometry was performed on digital images using a computer program «Image J». **Results.** The data indicate that the 21 daily administration of magnesium chloride adult rats increases the area and height of the follicular epithelium, increased follicular-colloidal index, number thyrocytes in the follicle, resorption vacuoles in the colloid, increase the number interfollicular islets, decrease the relative area of connective tissue in the gland. **Conclusions.** The influence of magnesium chloride (at a dose of 50 mg/kg) increases the signs of the thyroid gland synthetic activity. This may be of practical interest in the use of magnesium-containing compounds in persons with thyroid dysfunction.

Keywords: magnesium, thyroid gland, morphometric parameters.

Thyroid disease (TD) is an important medical and social problem all over the world, due to the high prevalence of the pathology that affects the most able-bodied population and children [1]. The spectrum of etiological factors that lead to a thyroid dysfunction can be attributed to: genetic factors, autoimmune diseases, infectious diseases, pernicious habits, radiation damage, etc. [2]. A

special place among the thyroid pathology is an imbalance of macro- and microelements in the body. Deficiency or excess of such elements as iodine, selenium, magnesium, lithium, calcium, cobalt, copper, iron, etc. affect the thyroid, breaking the synthesis and increasing the body's need for thyroid hormones [3].

Magnesium is one of the 12 structural elements that make up 99% of the elemental content of the human body. It is the main intracellular ion involved in carbohydrate, protein and lipid

* Адреса для листування (Correspondence): Інститут фізіології ім. О.О. Богомольця НАН України, вул. Богомольця, 4, м. Київ, 01024, Україна.
E-mail: biolag@ukr.net

metabolism, regulates the storage and release of energy in ATP. Magnesium is involved in the functions control of many organs and systems: the nervous, endocrine, cardiovascular, musculoskeletal, digestive tract, and others [4]. Magnesium deficiency in human body is a common phenomenon, which may lead to: a decrease in its content in food, gastrointestinal tract pathology, TD (hyperthyroidism), excessive physical activity, stress, alcohol abuse, etc. [5].

Literary data about magnesium ions influence on the thyroid gland are small and ambiguous. This may be due to the use of various sources of magnesium in experiments, differences in the dosage of magnesium compounds, use in experiments of animals of different species and age, seasonality and duration of experiments, etc. [6-8]. It is known from literature that magnesium deficiency leads to a decrease in thyroid function (hypothyroidism) due to parathyroid gland synergistic function, which regulates the absorption of magnesium. Magnesium stimulates the thyroid gland to produce thyroxine, as well as it is directly involved in the transformation of thyroxin into triiodothyronine. Magnesium also has a direct role in the absorption of iodine by the thyroid [9].

The purpose of the work is to investigate the effect of magnesium chloride on the morphofunctional state of the thyroid gland in adult rats.

Materials and methods

The study was conducted in the spring period (March) of the year on 24 Wistar male rats at the age of 15 months old. The source of magnesium ions was magnesium chloride ($MgCl_2 \cdot 6H_2O$ Germany) that rats received daily orally at a dose 50 mg/kg body weight. The animals, both the control and the experimental group, were in unified conditions with a standard diet. Duration of experiment was 21 days. The rats were decapitated under a slight, ethereal anesthetic. Studies were performed according to the national «General ethical principles of experiments on animals» (Ukraine, 2001) that are conformed with the regulations of the «European Convention for the Protection of vertebrate animals used for experimental and other scientific purposes» (Strasbourg, 1985).

Histological medical preparations were made from the thyroid tissue according to the standard method: fixed in a Buena liquid, dehydrated in alcohols of increasing concentration (70-96 °C), and dioxanes. The received samples were poured into paraffin. Paraffin sections, 5-6 mcm thick, were made on a sliding microtome, painted with Bemer hematoxylin and eosin. Two- and three-color methods were used for Van Gyason and Masson for connective tissue elements visualization [10]. Using a digital camera, microdrugs were photographed on a microscope called «Nicon» (Japan). Morphometry was carried out using the computer program «Image J» [11].

The cross-sectional area of the follicles, colloids and follicular epithelium; effective, external and internal diameters of the follicles; height of the follicular epithelium was measured on the thyroid gland histological sections. An average number of thyrocytes in the follicles was calculated. The follicular-colloidal index and colloid accumulation index were determined. Using the method of imposing point morphometric nets, the relative area of the connective tissue, parenchyma of the gland (%) and the index of sclerotization were measured. Layers width of interparticle, interlobular and interfollicular connective tissue were measured [12-14].

Statistical processing was carried out with statistics variation methods using the computer program Statistica 6.0. The normal distribution of digital arrays was checked with the Pearson criterion. With normality of distribution, to estimate the dissimilarity factor in the reliability of the differences between control and experimental groups, Student t-criterion was used. Differences were considered reliable at $p < 0.05$.

Results and discussion

It was found that thyroid gland of rats receiving magnesium chloride has an unchanged structure with preservation of its main structural elements. The structure of the thyroid parenchyma is divided into central and peripheral zones. Yes, animals' thyroid gland contains follicles of oval and elongated shape of different sizes. Follicles of small and medium size are localized in the central part of the gland, and large in size — in the

Оригінальні дослідження

periphery. In the intact animals' thyroid colloid in follicles stains uniform pink color, moderate or dense consistency with resorptive vacuoles. Follicles colloid of experimental animals has moderate density, less foamy with numerous resorptive vacuoles, indicating the release of hormones (**Fig.**).

In animals that received magnesium chloride, the relative area of thyroid gland parenchyma tended to increase (by 5%) compared to control. The cross-sectional area of the follicles and colloids in the experimental rats' thyroid gland remained at the control level, while the area of the follicular epithelium increased in 11% (**Table 1**).

The external, internal and effective diameters of the follicles in the thyroid of rats, after magnesium chloride administration, had no significant deviations from the control parameters. The thyrocytes' average number in the follicle of the

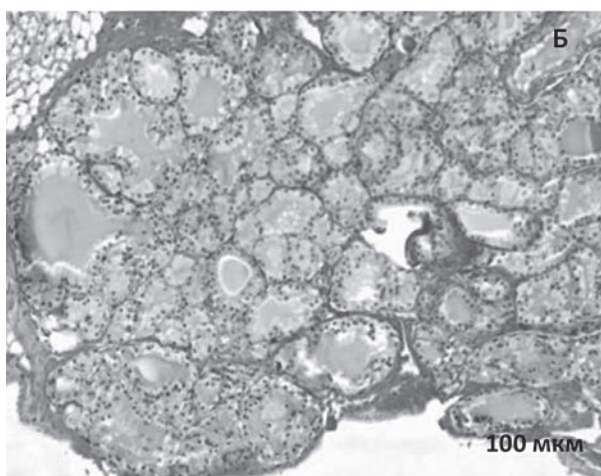



Fig. Microphotography of the thyroid gland of the intact animal (A) and the rat receiving magnesium chloride (B). Stained by the Van Gyason method. $\times 200$.

Table 1. Morphometric indicators of the thyroid gland condition of control and experimental rats ($M \pm m$, $n=12$)

Indicators	Control	Experimental
Relative area of parenchyma, %	77.8 \pm 1.69	81.5 \pm 1.62
Area, mcm ²	3576 \pm 107	3700 \pm 108
of follicle	1605 \pm 96	1517 \pm 85
of colloid	1971 \pm 80	2183 \pm 84
of follicular epithelium	62.9 \pm 2.28	68.0 \pm 1.93
Diameter of follicle, mcm	40.5 \pm 2.14	42.8 \pm 1.39
external	74.1 \pm 2.50	80.6 \pm 2.17
internal	11.2 \pm 0.11	12.6 \pm 0.21 *
effective	20.4 \pm 0.36	23.9 \pm 0.83 *
Height of thyrocytes, mcm	1.23 \pm 0.04	1.44 \pm 0.03 *
Number of thyrocytes in the follicle, units	1.81 \pm 0.17	1.70 \pm 0.37 *
Follicular-colloidal index, units		
Colloid accumulation index, units		

Note: here and in tabl. 2 * — significant difference with control ($p < 0.05$).

experimental rats was more than 17% ($p < 0.05$) compared to the control. Thyrocytes of cubic and prismatic form are a significantly higher than 13% of the control (**Table 1**). The shape of the thyrocytes depends on the functional state of the thyroid. With normal function, they have a cubic form, with hypofunction they become flat, and with hyperfunction they acquire the prismatic form. Thyrocytes of the prismatic form actively resorb thyroglobulin, discharge active hormones and secrete them in the bloodstream [12].

The follicular-colloidal index (the ratio of cross-sectional area of the follicular epithelium to colloid area) in the experimental rats was significantly higher by 17% compared to the control. Then, as the accumulation index of the colloid (the ratio of the internal diameter of the follicle to the double height of the follicular epithelium), on the contrary is tended to decrease by 6% compared with the control (**Table 1**). The growth of the follicular-colloidal index and the decrease of the colloid accumulation index indicate an increase in the secretion of thyroid hormones in the bloodstream [13].

In experimental rats there was a tendency to increase the number of interfollicular islets, which can be considered as a sign of thyroid regeneration processes activation. Interfollicular islets contain small differentiated cells, which can be a source for the new follicles formation [12].

The structure of the thyroid skeleton connective tissue includes a capsule and stroma. In the latter one, it is distinguished interparticle, interlobular and interfollicular and paravasal

connective tissue (CT). Interparticle CT surrounds the lobe of thyroid from the exterior. Interlobular CT divides thyroid parenchyma into lobes. It consists of thin bundles of collagen fibers, interlacing in different directions. Interfollicular CT consists of reticular and collagen fibers, which intertwine in the follicular membranes, linking the follicles among themselves. Paravasal CT surrounds the blood vessels of the thyroid. It is represented mainly by elastin fibers and to a lesser extent, by collagen ones. In addition to thyroid parenchyma cells, in the interfollicular connective tissue layers, CT cells are present, namely: lymphocytes, plasma cells and tissue basophils [15].

It was found that in animals, after magnesium chloride administration, the relative area of stroma in the thyroid gland was lower by 17% ($p < 0.05$) compared to the control group. This led to a significant increase in the index of sclerotization (relative ratio of the thyroid parenchyma to the relative stroma area) by 26%, which may indicate a relative decrease in the CT mass in the thyroid. It was shown that in the experimental animals' thyroid gland, the number of CT elements, depending on the localization, varied in different ways. Thus, in the thyroid gland of the experimental rats, the width of the interparticle CT remained at the control level, interlobular is increased by 24% ($p < 0.05$), and interfollicular, on the contrary, decreased by 12% ($p < 0.05$) compared with the control parameters (**Table 2**). That is, the width of the CT that breaks the lobe in the middle of the thyroid gland increases, and the number of ST elements placed between the follicles themselves, is reduced, which improves the interfollicular metabolism.

The study of magnesium compounds influence on the thyroid condition was carried out by other researchers. It was found that the effect of magnesium sulfate in various doses (0.5; 1

Table 2. Morphometric indicators of connective tissue condition in the thyroid gland of control and experimental rats ($M \pm m$, $n=12$)

Indicators	Control	Experimental
Relative stroma area, %	22.2±0.89	18.5±0.36 *
Sclerotization index, units	3.50±0.21	4.41±0.09 *
Layers width of connective tissue, mcm		
interparticle	24.5±1.36	23.9±1.27
interlobular	9.10±1.09	11.3±0.36 *
interfollicular	1.77±0.03	1.56±0.08 *

and 1.5 g/kg) on Wistar rat lines stimulated thyroid-like peroxidase and $\text{Na}^+\text{-K}^+\text{-ATPases}$ for 60 days, modified type I iodine thyronin, increased thyroxin content in the serum, led to hypertrophy of the follicular epithelium, that is, caused hyperthyroidism [7]. In another work, the deficiency and excess of magnesium on C-thyroid cells were investigated. It was shown that magnesium deficiency led to C-cells hypertrophy and hyperplasia, ribosomes hyperplasia and endoplasmic net in them. All this was accompanied by a reduced activity of cholinesterase, an increase in the synthesis and secretion of calcitonin. With a magnesium excess, thyroid C-cells did not increase in size, however, the cholinesterase activity, dopamine synthesis and storage are increased [8].

Conclusions

21-day magnesium chloride administration (at a dose of 50 mg/kg) in adult rats increases the functional activity of the thyroid gland. This is indicated by an increase in the area and height of the follicular epithelium, an increase in the follicular-colloidal index, the number of thyrocytes in the follicle, the presence of numerous resorptive vacuoles in the follicles colloid, an increase in the number of interfollicular islets, and a decrease in the relative area of stroma in the thyroid gland. These data may have not only a theoretical value, but also some practical interest in the magnesium compounds use in persons with impaired function (hypothyroidism) of the thyroid gland.

References

1. Vanderpump MP. The epidemiology of thyroid disease. *Br Med Bull.* 2011 Sept; 99:39-51.
2. Antonelli A, Ferrari SM, Corrado A, Di Domenicantonio A, Fallahi P. Autoimmune thyroid disorders. *Autoimmun Rev.* 2015 Feb;14(2):174-80
3. Moncayo R, Moncayo H. The WOMED model of benign thyroid disease: Acquired magnesium deficiency due to physical and psychological stressors relates to dysfunction of oxidative phosphorylation. *BBA Clin.* 2015 Jun; 3:44-64.
4. Andrea MP. Chapter 3. Magnesium in health and disease. In Sigel A, Sigel H, Roland KO. *Sigel. Interrelations between essential metal ions and human diseases. Metal ions in life sciences.* 2013. Springer. 49-79.
5. Fox C, Ramsoomair D, Carter C. Magnesium: its proven and potential clinical significance. *Southern Med J.* 2003;94(12):1195-201.
6. Tossion R, Brandt G. Magnesium, zinc and copper concentrations in the normal and diseased thyroid gland. *Mag-Bull.* 1988;10:87-90.
7. Chandra AK, Goswami H, Sengupta P. Effects of magnesium on

Оригінальні дослідження

- cytomorphology and enzyme activities in thyroid of rats. *Indian J Exp Biol.* 2014 Aug;52(8):787-92.
8. Stachura JA, Pearse AG. Thyroid C cells in experimental hyper and hypomagnesaemia. *Virchows Archiv B.* 1970;5:173.
 9. Jones JE, Desper PC, Shane SR, Flink EB. Magnesium metabolism in hyperthyroidism and hypothyroidism. *J Clin Invest.* 1966 Jun;45(6):891-900.
 10. Danilov RK. Guide to histology. St. Petersburg. Spec Lith. 2011; II.
 11. Nikonenko AG. Introduction to quantitative histology. Kyiv: Knihga-Plus. 2013.
 12. Zabrodin VA. Morphology of thyroid and methods of its study: methodical recommendations. Smolensk: SGMA. 2005.
 13. Nikishin DV. Morphology and methods of thyroid research: methodical recommendations. Penza: Inf. of publ. center PGU. 2008.
 14. Yanko RV. Morphofunctional state of the thyroid gland after exposure to normobaric hypoxic gas mixtures. *Endokrinolohiya.* 2016;21(1):33-7.
 15. Ludwig KS. Structure of the thyroid gland; I. Structure of connective tissue. *Acta Anat (Basel).* 1952;15(3):300-8.

(Надійшла до редакції 19.06.2018 р.)

Дослідження впливу іонів магнію на морфофункціональний стан щитоподібної залози дорослих щурів

Р.В. Янко

Інститут фізіології ім. О.О. Богомольця НАН України

Резюме. Мета роботи — дослідити вплив магнію хлориду на морфометричні показники функціонального стану щитоподібної залози дорослих щурів. **Матеріали та методи.** Дослідження проведено на 24 щурах-самцях лінії Wistar віком 15 місяців. Дослідні щури щодня перорально отримували магнію хлорид у дозі 50 мг/кг маси тіла. Тривалість експерименту становила 21 добу. З тканини щитоподібної залози виготовляли гістологічні препарати за стандартною методикою. Морфометрію залози здійснювали на цифрових зображеннях за допомогою комп'ютерної програми Image J. **Результати.** Отримані дані свідчать, що 21-добове введення магнію хлориду дорослим щурам призводить до збільшення площі та висоти фолікулярного епітелію, зростання фолікулярно-колоїдного індексу, кількості тиреоцитів у фолікулі, резорбційних вакуолей у колоїді, чисельності інтерфолікулярних

острівців, зменшення відносної площі стромы в залозі. **Висновки.** Введення магнію хлориду (у дозі 50 мг/кг) посилює ознаки синтетичної активності щитоподібної залози. Це може мати практичне значення щодо використання магнієвмісних сполук в осіб із порушенням функції щитоподібної залози.

Ключові слова: магній, щитоподібна залоза, морфометричні показники.

Исследование влияния ионов магния на морфофункциональное состояние щитовидной железы взрослых крыс

Р.В. Янко

Институт физиологии им. А.А. Богомольца НАН Украины

Резюме. Цель — исследовать влияние магния хлорида на морфометрические показатели функционального состояния щитовидной железы взрослых крыс. **Материалы и методы.** Исследование проведено на 24 крысах-самцах линии Wistar в возрасте 15 месяцев. Подопытные крысы ежедневно перорально получали магния хлорид в дозе 50 мг/кг массы тела. Продолжительность эксперимента составляла 21 сутки. Из ткани щитовидной железы изготавливали гистологические препараты по стандартной методике. Морфометрию железы осуществляли на цифровых изображениях с помощью компьютерной программы Image J. **Результаты.** Полученные данные свидетельствуют, что 21-суточное введение магния хлорида взрослым крысам приводит к увеличению площади и высоты фолликулярного эпителия, росту фолликулярно-коллоидного индекса, количества тиреоцитов в фолликулах, резорбционных вакуолей в коллоиде, увеличению численности интерфолликулярных островков, уменьшению относительной площади стромы в железе. **Выводы.** Введение магния хлорида (в дозе 50 мг/кг) усиливает признаки синтетической активности щитовидной железы. Это может иметь практический интерес относительно использования магнийсодержащих соединений у лиц с нарушением функции щитовидной железы.

Ключевые слова: магний, щитовидная железа, морфометрические показатели.



Реєструйтеся на сайті:
www.chil.com.ua

“ЛЮДИНА ТА ЛІКИ” - УКРАЇНА 2018

РЕГІОНАЛЬНИЙ КОНГРЕС

12 вересня, м. Дніпро

КДЦ "Менора"

вул. Шолом-Алейхема, 4/26

4-5 жовтня м. Одеса
Медичний Дім Odrex,
вул.Розкидайлівська, 69/71

19 жовтня м. Львів
готель "Супутник", вул. Княгині Ольги, 116

9 листопада м. Запоріжжя

23 листопада м. Харків

Дивіться пряму інтернет-трансляцію
обраних лекцій на головній сторінці порталу
www.chil.com.ua

Оргкомітет: ТОВ «Нью Віво»
Адреса: м. Київ.
вул. С. Петлюри. 13/135, офіс 23 (2 поверх)
Тел./факс: +38 044 287 07 20
e-mail: office@newvivo.com.ua

International Exhibition



27-а Міжнародна медична виставка «ОХОРОНА ЗДОРОВ'Я»

2-4 ЖОВТНЯ 2018

Київ, МВЦ, Броварський пр-т, 15
Ⓜ Лівобережна



У рамках виставки відбудеться:

Всеукраїнська відзнака

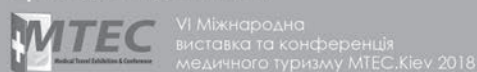
«ГОЛОВНИЙ ЛІКАР РОКУ – 2018»

Організатори:



Прем'єр Експо
Тел: +38 (044) 496 86 45
E-mail: ph@pe.com.ua

Проходить одночасно:



www.publichealth.com.ua