

the allergic syndrome in 64.3%, the asteno-neurotic in 64.3%, intoxication syndrome in 50% of patients).

3. Patients with monoinvasion, whose clinical picture is characterized by pronounced polymorphism, are recommended to perform the examination in the presence of other parasitic diseases.

References

1. Babak OY. Efficiency and safety of the use of Meratin for patients with giardiasis. *Suchasna gastroenterologiya*. 2007; 3:56-60.
2. Bodnya K. Treatment of giardiasis in children and adults. *Aktualnaya infektologiya*. 2015; 4:31-37.
3. Bodnya K, Mochalova G, Kadel'nik L. Giardiasis: diagnostic and treatment of patients in modern conditions. *Aktualnaya infektologiya*. 2015; 1:27-33.
4. But G. Modern strategies for the treatment of infections in pediatric gastroenterology. *Novosti meditsiny i farmatsii*. 2013; 451:29-33.
5. Vasilieva NA. Combined invasion of ascariasis and giardiasis: specificity of immunity and treatment. *Infektsiyni khvoroby*. 2013; 2:57-60.
6. Ershova I, Mochalova A, Lohmatova I. Allergic reactions in children with helminthiasis. *Aktualnaya infektologiya*. 2014; 4:77-80.
7. Kabakova A, Shulgai O. Approaches to treatment of giardiasis in children. *Zdorovya Ukrainy*. 2014; 1:50-51.
8. Konanykhina SYu. Effectiveness and perspectives of using Nifuratel in giardiasis treatment in children. *Bolezni i antibiotiki*. 2013; 7:18-22.
9. Koniushkevskaya AA, Sidorenko NV, Soroka LV, Detsik OS.

Giardiasis in children. *Epidemiology, clinical manifestation and diagnostic*. *Zdorovye rebenka*. 2014; 53:44-49.

10. Kramarev SA. Diagnostics, treatment and prevention of Giardiasis. *Zdorovya Ukrainy*. 2011; 1:19-20.

11. Loboda VF, Glushko KT, Dobrovolska LI. The actuality of parasitic diseases at the child's pathology of digestive system. *Visnyk naukovykh doslidzhen*. 2012; 4.

12. Maliy VP. Giardiasis. *Dityachy likar*. 2014; 34:29-36.

13. Malchitskiy M, Karbovanets O, Koval G. Specific features of acute diarrhea syndrome in the background of giardiasis and helminthiasis. *Naukovy visnyk Uzhgorodskogo universitetu. Seriya Meditsina*. 2013; 3:69-72.

14. Molchanov D. Giardiasis in children: epidemiology, diagnosis, treatment. *Okhorona zdorovya*. 2013; 1:45-51.

15. Mochalova AA. Treatment and diagnosis of Giardiasis in modern conditions. *Aktualnaya infektologiya*. 2013; 1:117-122.

16. Shadrin OG, Koval'chuk AA, Dyukareva SV, Fisun VM, Basaraba NM. Correction of gastrointestinal disorders in children with helminthiasis. *Zdorovye rebenka*. 2016; 7:27-35.

17. Minetti C, Lamden K, Durband C, Cheesbrough J, Fox A, Wastling J. Determination of *Giardia duodenalis* assemblages and multi-locus genotypes in patients with sporadic giardiasis from England. *Parasit Vectors*. 2015; 8: 444.

Received: 07.11.2018

Revised: 12.12.2018

Accepted: 17.12.2018

DOI: 10.21802/gmj.2018.4.13

Vadim Ratchik, Oleksandr Babii, Natalia Prolom, Boris Shevchenko

Diagnosics and Minimally Invasive Surgery for Achalasia Cardia

Institute of Gastroenterology of the National Academy of Medical Sciences of Ukraine, Dnipro, Ukraine

Abstract. The objective of the research was to assess the effectiveness of balloon pneumatic dilation and laparoscopic Heller myotomy in treatment of patients with achalasia cardia.

Materials and methods. Twenty-one patients with achalasia cardia were examined and treated using pneumatic balloon dilation and laparoscopic Heller myotomy in the Department of Surgery from January 2016 to April 2018. There were 8 (38.1%) men and 13 (61.9%) women at the age of 28 to 75 years (the average age was 51.47 ± 3.63 years) and disease duration of 1 month to 8 years (the average disease duration was 3.05 ± 0.49 years).

Results and discussion. With the help of radiological methods of examination, all the patients were divided into 4 groups according to the esophageal diameter: Group I included 5 (23.8%) patients with the esophagus up to 4-5 cm in diameter; Group II comprised 6 (28.6%) patients with the esophagus up to 4-6 cm in diameter; Group III included 5 (23.8%) patients with the esophagus up to 6-8 cm in diameter; Group IV consisted of 5 (23.8%) patients with the esophagus of more than 8 cm in diameter and an S-shaped configuration. A significant decrease

in the diameter of the esophagus according to fluoroscopy ($p < 0.05$) alongside with a decrease in the lower esophageal sphincter pressure according to manometry are indicative in assessing the effectiveness of achalasia cardia treatment after minimally invasive surgery. There were no complications when performing pneumatic balloon dilation and laparoscopic Heller myotomy.

Conclusions. In 7 (33.3%) patients, recurrences of achalasia cardia after balloon pneumatic dilation occurred within 2 - 10 months: in 4.7% of patients in Group I and 9.5% of patients in Group II, Group III, and Group IV. In recurrent achalasia cardia, repeated dilation was ineffective. There was performed laparoscopic Heller myotomy with Dor fundoplication, which was effective in 80.0% of cases.

Keywords: *achalasia cardia; diagnostics; balloon pneumatic dilation; laparoscopic Heller myotomy, relapses.*

Problem statement and analysis of the recent research

Achalasia cardia (AC) is a disorder characterized by impaired

relaxation of the lower esophageal sphincter (LES) in response to swallowing, discoordination of peristaltic contractions and gradual development of functional intestinal obstruction [1].

This pathology is one of the most common causes of esophageal motor dysphagia. Its incidence rate is approximately 1 case per 100,000 people annually, while the prevalence rate is 10 cases per 100,000 people. AC affects men and women equally, while its incidence increases with age [2, 3].

According to the histological analysis, AC results from the degeneration of cellular ganglia in the intermuscular Auerbach plexus of the esophageal body and the LES which leads to the esophageal motility impairment and LES relaxation impairment [4, 5].

Among modern treatment options, laparoscopic Heller myotomy (LHM) with anterior Dor fundoplication, peroral endoscopic myotomy (POEM), balloon pneumatic dilation (PD) and endoscopic injection of botulinum toxin are considered [6].

The most commonly used techniques are balloon PD and LHM [7, 8, 9].

The tactics of AC treatment is currently widely discussed, since even surgical treatment not always provides the promising results. The use of conservative methods alongside with balloon PD is quite effective at the initial stages of AC. Cicatricial changes in the gastroesophageal junction and persistent esophageal expansion are indications for surgical treatment with the use of modern laparoscopic and endoscopic techniques. The choice of surgical method depending on manometric subtypes determining the response to treatment is critical [9, 10, 11].

The objective of the research was to assess the effectiveness of balloon PD and LHM in treatment of patients with AC.

Materials and methods

Twenty-one patients with AC were examined and treated in the Department of Digestive Organ Surgery from January 2016 to April 2018. There were 8 (38.1%) men and 13 (61.9%) women at the age of 28 to 75 years (the average age was 51.47 ± 3.63 years). According to the findings of radiological examination of the esophagus, all the patients were divided into 4 groups: Group I included 5 (23.8%) patients with the esophagus up to 4-5 cm in diameter; Group II comprised 6 (28.6%) patients with the esophagus up to 4-6 cm in diameter; Group III included 5 (23.8%) patients with the esophagus up to 6-8 cm in diameter; Group IV consisted of 5 (23.8%) patients with the esophagus of more than 8 cm in diameter. The study included patients with disease duration of 1 month to 8 years (the average disease duration was 3.05 ± 0.49 years).

Radiological examination with contrast agent administration was carried out using the innovatory R/F remote-controlled table OperaT-90; the peristalsis, the size, the rate of contrast evacuation, the location of the esophagus and the state of the gastroesophageal junction were studied. The diameter of the esophagus was measured in pixels; 65 pixels were equal to 1 cm. In the control group, the esophagus was 1.5-2.0 cm in diameter.

Endoscopic diagnostics was carried out using the Olympus HQ-190 HD (Japan) and the Olympus XQ-40 (Japan) endoscopes.

Esophageal manometry was performed using the digital pressure gauge MHX-01 (Ukraine). The method involved the measurement of the LES pressure (mm Hg) using the air-filled balloon with a diameter of 2.0 cm. The normal LES pressure was 10-25 mm Hg.

A 35-mm and a 40-mm Rigiflex II Boston Scientific balloon (USA) were used to perform PD. There were performed 3-6 sessions of balloon PD under endoscopic or/and radiological control; each session lasted 3-5 minutes; the interval between sessions was 1-3 days; the pressure was created to complete the expansion of the balloon in the area of narrowing. On the background of PD, pharmacological therapy (proton pump inhibitors (pantoprazole), M-cholinolytics, calcium channel

blockers, nitrates, tranquilizers) was performed (Fig.1).

LHM with Dor fundoplication was performed using the equipment manufactured by Karl Storz (Germany) and an ultrasonic scalpel SonoSurg (Japan) in 5 (23.8%) patients.

Results and discussion

In Group I, esophagoscopy revealed no esophagitis; the characteristic endoscopic sign was change in the width of the esophageal lumen; its peristalsis, the state of the mucosa, the location of the cardia and the degree of its opening did not undergo any changes. The cardiac sphincter was centered, closed and opened in case of a low level of air insufflation. The retrograde examination revealed that the LES was tightly wrapped around the endoscope; the mucous membrane was elastic. The passage of the endoscope through the LES and the cardia was easy and there were no obstacles (Fig. 2a).

Characteristic radiological signs were normal esophageal peristalsis, increase in the esophageal diameter up to 4 cm, slight narrowing of the distal esophagus which easily let barium suspension flow in (Fig. 2b).

In Group II, esophagoscopy revealed esophagitis; the characteristic endoscopic sign was a significant expansion of the esophageal lumen; a characteristic funnel-shaped and wedge-shaped form of its terminal portion without any contents (the accumulation of the mucus or fluid, food debris) was observed. The mucous membrane was smooth, even and shiny; its folds were longitudinal in direction. The cardiac sphincter was centered, slit-shaped and closed; however, it easily opened in case of a moderate level of air insufflation. The passage of the endoscope through the LES and the cardia was easy and there were no obstacles (Fig. 3a).

Radiological examination revealed spasm of the cardia that was more persistent as compared to Group I, while the esophageal diameter increased from 4 to 6 cm. Peristaltic waves were diminished as they moved to the distal esophagus. The opening of the narrowed portion did not occur immediately; it opened in case of tighter filling of the esophagus. The cardia was closed until the process of emptying contrast media from the esophagus was completed (Fig. 3b).

In Group III, during esophagoscopy, the characteristic endoscopic sign was the expansion of the esophagus and the presence of abundant mucus and food debris in its lumen. The cardiac sphincter was eccentrically located, tightly closed, dot-shaped; it did not open even in case of a high level of air insufflation. The esophageal mucosa was slightly thickened due to constant backup of food within the esophagus; in the distal portion, the mucous membrane was hyperemic and slightly swollen (Fig. 4a). A significant resistance was felt when the endoscope passed through the cardial part to the stomach.

Characteristic radiological signs were the increase in the esophageal diameter from 6 to 8 cm, the absence of normal peristalsis and irregular contractions of its walls. The cardia opened only in case of a significant filling of the esophageal lumen. There was observed the reduction in the size of the gastric air bubble, or it was absent (Fig. 4b)

In Group IV, esophagoscopy revealed an ectatic esophagus with the formation of transverse folding. On an empty stomach, the esophageal lumen contained the accumulation of fluid, mucus, and food debris in such quantities that there was a need for an esophageal lavage to carry out more adequate reexamination. The cardia was eccentrically located. The mucous membrane was thickened, hyperemic and slightly swollen; in 2 cases, there

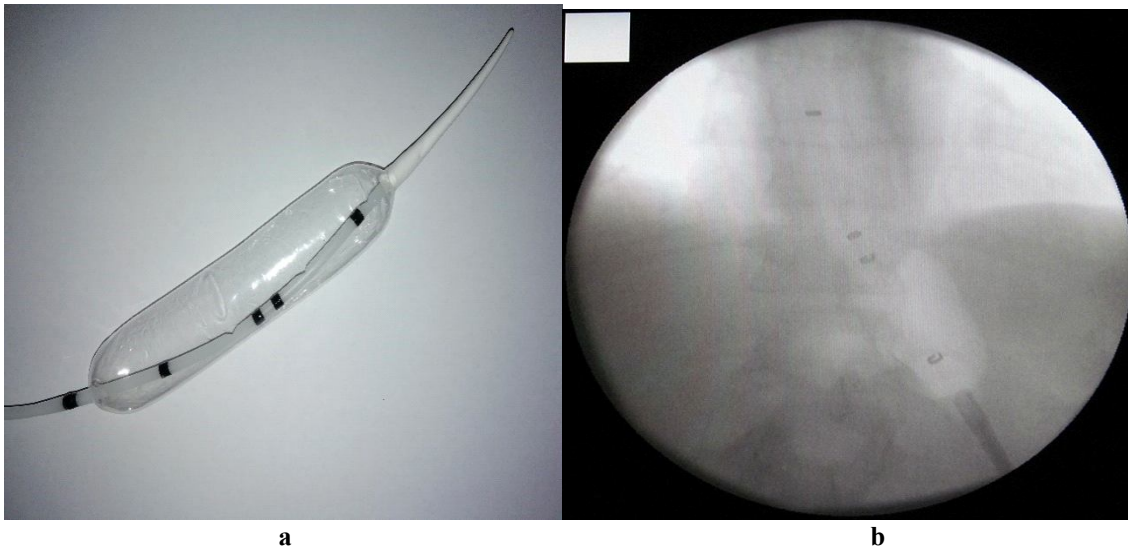


Fig. 1. Characteristics of the balloons used: a) Boston Scientific balloon (USA); b) PD under radiological control – the balloon waist in the area of stricture

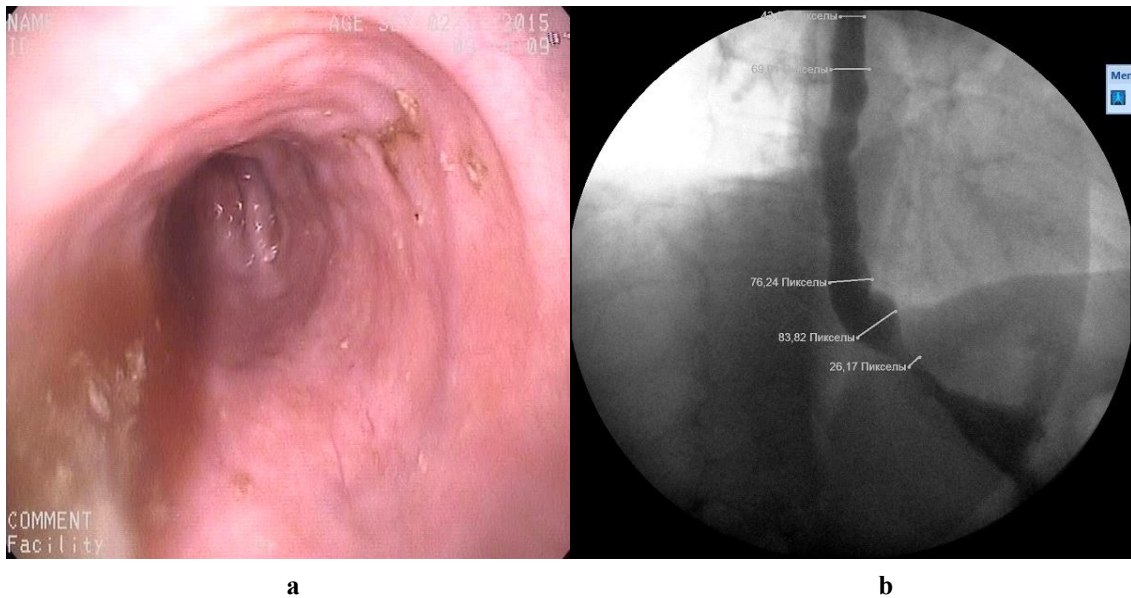


Fig. 2. AC in Group I: a) endoscopic assessment of the esophageal mucosa; b) X-ray assessment of the passage of the contrast agent through the esophagus

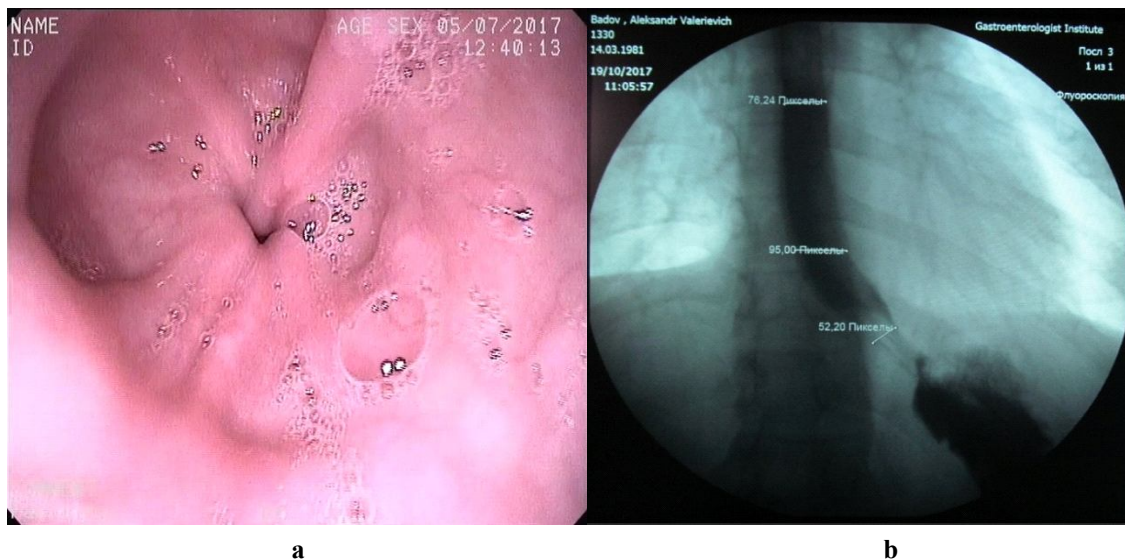


Fig. 3. AC in Group II: a) endoscopic assessment of the esophageal mucosa; b) X-ray assessment of the passage of the contrast agent through the esophagus

Table 1. LES manometry in groups of patients before and after balloon PD course

LES manometry	Group I (n=5)	Group II (n=6)	Group III (n=5)	Group IV (n=5)
before treatment, mm Hg	62.9±17.8	63.2±7.7	66.3±11.7	86.10±15.5
after treatment, mm Hg	10.5±3.0*	14.8±2.2**	15.3±3.5**	16.4±3.7**

Notes: * - (p<0.05);

** - (p<0.01) – the reliability of the difference in the manometric indicators before and after balloon PD course

were observed cicatricial changes in the lower third of the esophagus (Fig. 5a). More significant resistance was felt when the endoscope passed through the cardia.

Radiological examination revealed esophageal atony, a sharp increase in the esophageal diameter of more than 8 cm, the reduction in the esophageal length (Fig. 5b).

All the patients underwent balloon PD, while endoscopic balloon PD was performed in 5 patients of Group IV.

Fig. 6 presents a fragment of performing endoscopic balloon PD.

The data of LES manometry in groups of patients before and after balloon PD course are presented in Table 1.

After balloon PD course, there was observed a significant difference in the reduction in the LES pressure in all the groups (p<0.05).

The control of treatment effectiveness was carried out using the radiological data obtained (Table 2).

According to Table 2, a statistically significant (p<0.05) dynamics was observed in all the patients.

There were no complications when performing balloon PD. During balloon PD, the effect of the gradual disappearance of the balloon waist was achieved in all the patients.

As recurrences of AC after balloon PD occurred within 2 - 10 months, repeated courses of balloon PD were carried out. They were effective in 50.0% of cases in Group I and Group II, and 20.0% of cases in Group III and Group IV. In 23.8% of patients, repeated course of balloon PD was ineffective.

Such patients underwent LHM with Dor fundoplication. An ultrasonic scalpel was used to make a 5-cm incision of the muscular fibers in the distal esophagus followed by a 3-cm incision in the cardia. After gastric fundus mobilization, there was performed anterior fundoplication using a continuous suture technique, an atraumatic needle and non-absorbable Ti-Cron 2/0 surgical sutures.

Fig. 7 presents the stages of performing LHM.

After LHM and Dor fundoplication, the positive results were observed in 4 (80.0%) cases. There were no intraoperative and postoperative complications when performing LHM.

Fig. 8 presents an example of LHM instrumental screening with a positive dynamics.

Discussion

Balloon PD is an effective primary treatment of AC, especially in the short term. However, the use of PD is characterized by relapses and the need for retreatment. Although LHM demonstrates better long-term effectiveness, there are patients who suffer from constant or recurrent symptoms of AC after LHM. Thus, according to the results of one of the prospective multicenter randomized trials, 2 years after LHM,

Table 2. Radiological examination of the esophagus in groups of patients before and after balloon PD course

Esophageal diameter	Group I (n=5)	Group II (n=6)	Group III (n=5)	Group IV (n=5)
before treatment, cm	3.24±0.24	5.13±0.26	7.28±0.16	8.54±0.26
after treatment, cm	1.60±0.15*	3.21±0.26*	3.86±0.69**	5.72±0.27*

Notes: * - (p<0.05);

** - (p<0.01) – the reliability of the difference in the manometric indicators before and after balloon PD course

10% of patients developed significant recurrent symptoms of AC [12]. According to the data of the meta-analysis conducted by Illés A et al. (2017), the effectiveness of LHM exceeded that of PD by the duration of remission and the reduction in the frequency of relapses in AC [9]; whereas according to the results of Cheng JW et al. (2017), there were no significant differences between LHM and PD in 2-year and 5-year remission periods. This study showed that any type of treatment may be offered as initial treatment of AC [13].

Thus, when assessing the methods of minimally invasive surgery for AC we used, it should be noted that balloon PD provided good results immediately after procedure; however, in one-third of cases, it was characterized by rather short-term effectiveness, especially in later stages of the disease. Therefore, the use of LHM with Dor fundoplication complements the program of comprehensive treatment and improves the anti-reflux function of the LES.

Conclusions

1. AC recurrences after balloon PD occurred within 2 - 10 months in 33.3% of cases; therefore, repeated courses of balloon PD were carried out. They were effective in 9.5% of cases. In 23.8% of patients, repeated course of balloon PD was ineffective.

2. After LHM with Dor fundoplication, the positive results were observed in 80.0% of cases.

References

- Clark SB, Rice TW, Tubbs RR et al. The nature of the myenteric infiltrate in achalasia: an immunohistochemical analysis. *Am J Surg Pathol.* 2000;24(8):1153-1158.
- Enestvedt BK, Williams JL, Sonnenberg A. Epidemiology and practice patterns of achalasia in a large multi-centre database. *Aliment Pharmacol Ther.* 2011;33(11):1209-1214. doi: 10.1111/j.1365-2036.2011.04655.x.
- Francis DL, Katzka DA. Achalasia update on the disease and its treatment. *Gastroenterology.* 2010;139(2):369-374. doi: 10.1053/j.gastro.2010.06.024.
- Salis GB, Mazzadi SA, Garcha AO, Chiocca JC. Pneumatic dilatation in achalasia of the esophagus: a report from Argentina. *Dis Esophagus.* 2004;17(2):124-8. doi: 10.1111/j.1442-2050.2004.00388.x
- Ghoshal UC, Daschakraborty SB, Singh R. Pathogenesis of achalasia cardia. *World J Gastroenterol.* 2012;18(24):3050-3057. doi:10.3748/wjg.v18.i24.3050.
- Katada N, Sakuramoto S, Yamashita K et al. Recent trends in the management of achalasia. *Ann Thorac Cardiovasc Surg.* 2012;18(5):420-428.
- Amani M, Fazlollahi N, Shirani S et al. Assessment of pneumatic balloon dilation in patients with symptomatic relapse after failed Heller myotomy: a single center experience. *Middle East J Dig Dis.* 2016;8(1):57-62. doi: 10.15171/mejdd.2016.08.
- Chrystoja CC, Darling GE, Diamant NE et al. Achalasia-specific quality of life after pneumatic dilation or laparoscopic Heller myotomy with partial fundoplication: a multicenter, randomized clinical trial.

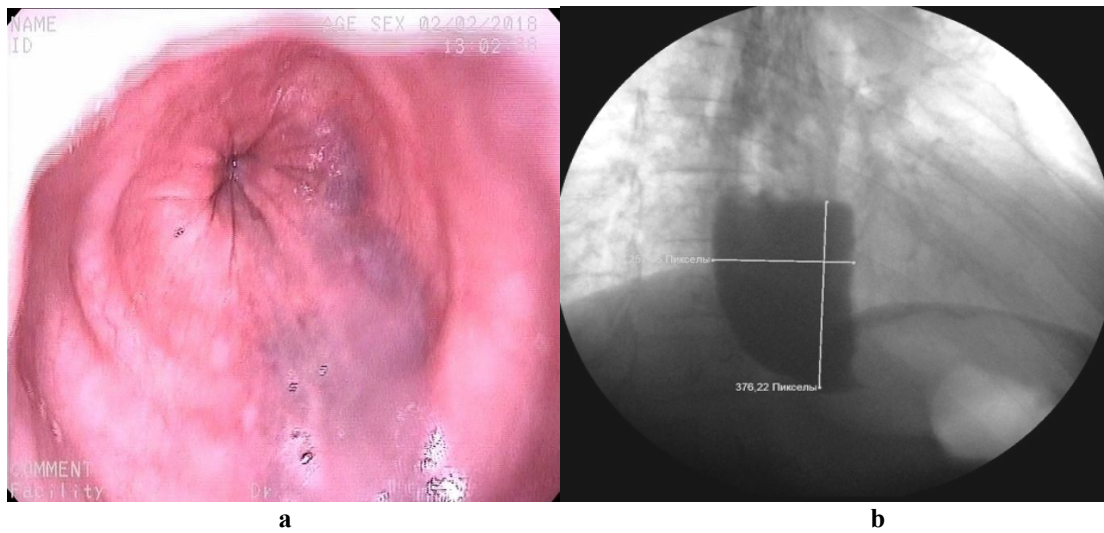


Fig. 4. AC in Group III: a) endoscopic assessment of the esophageal mucosa; b) X-ray assessment of the passage of the contrast agent through the esophagus

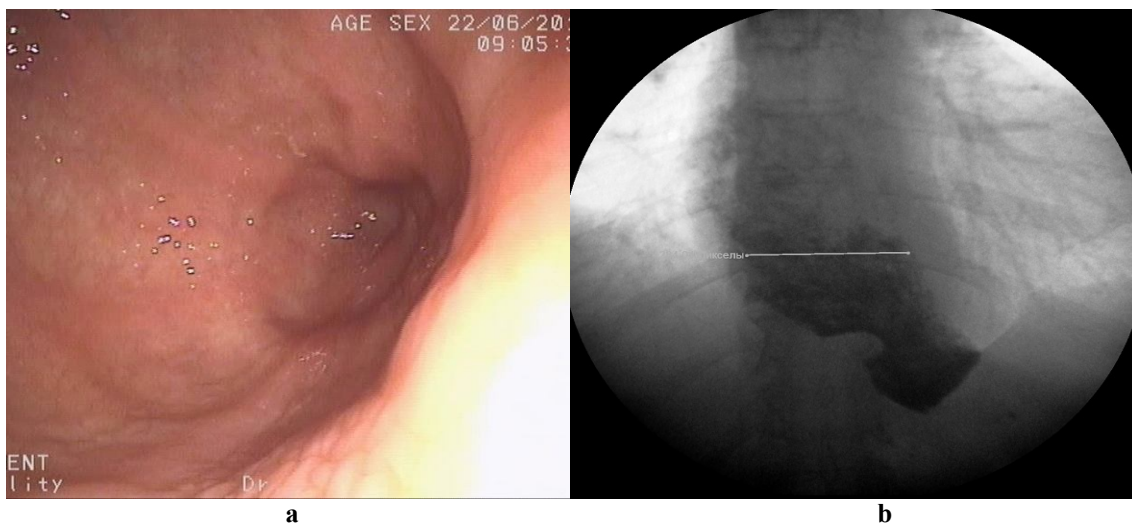


Fig. 5. AC in Group IV: a) endoscopic assessment of the esophageal mucosa; b) X-ray assessment of the passage of the contrast agent through the esophagus

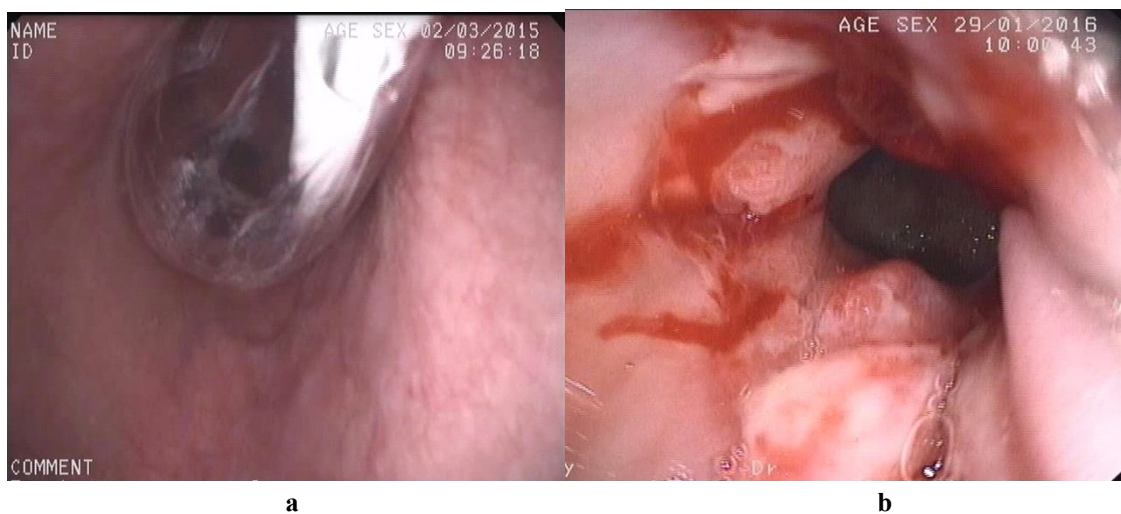


Fig. 6. Endoscopic balloon PD: a) the balloon is positioned within the LES; b) the LES after balloon PD with characteristic linear mucosal tears without active bleeding

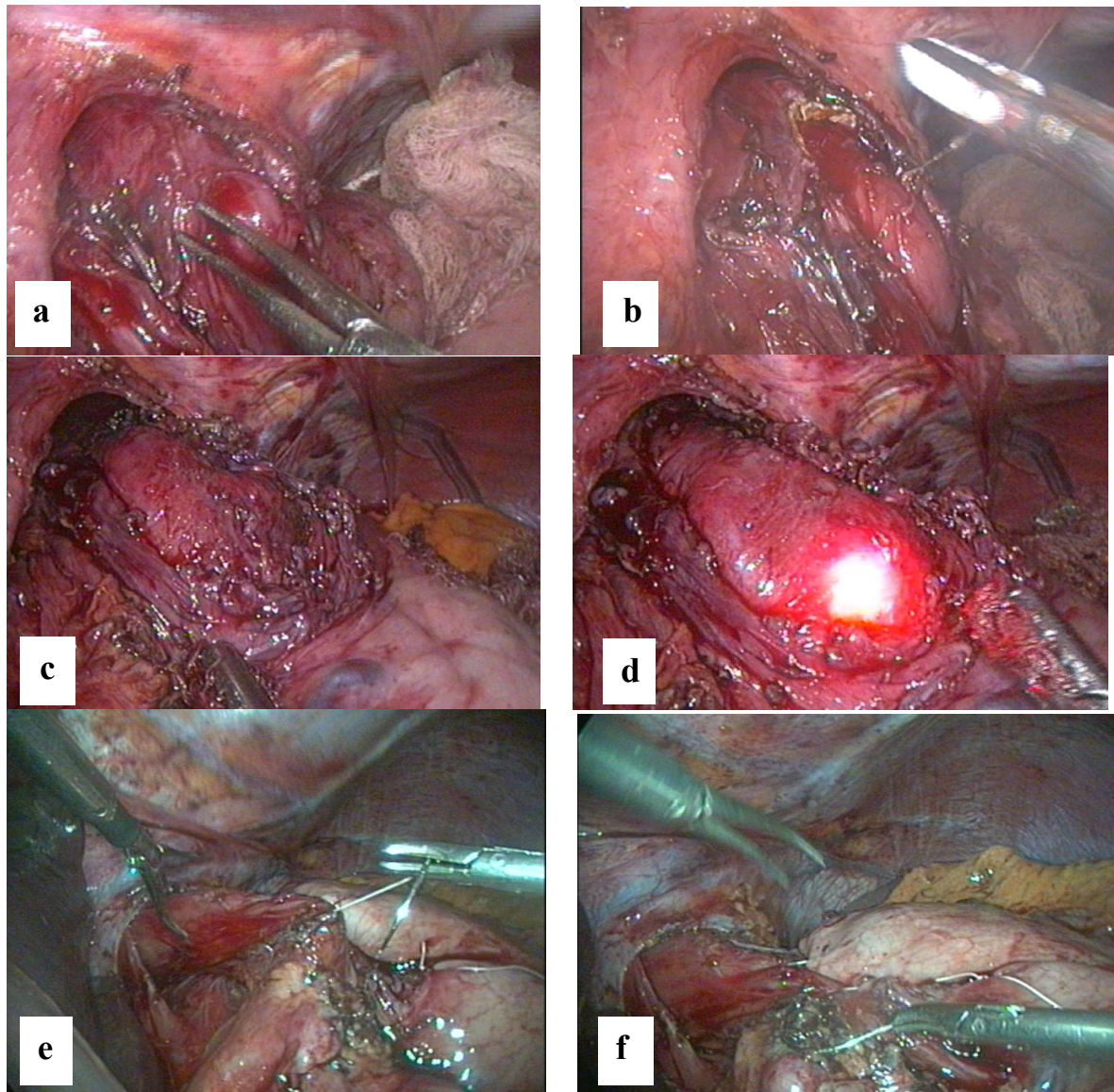


Fig. 7. Stages of performing LHM with Dor fundoplication: a) the dissection of the muscular layer of the esophagus to its mucosal layer; b) the stage of esophagectomy; c) the stage of cardiomyotomy; d) the stage of the endoscopic control of the gastroesophageal junction permeability; e) the stage of continuous suturing when performing Dor fundoplication; f) the final stage of performing Dor fundoplication

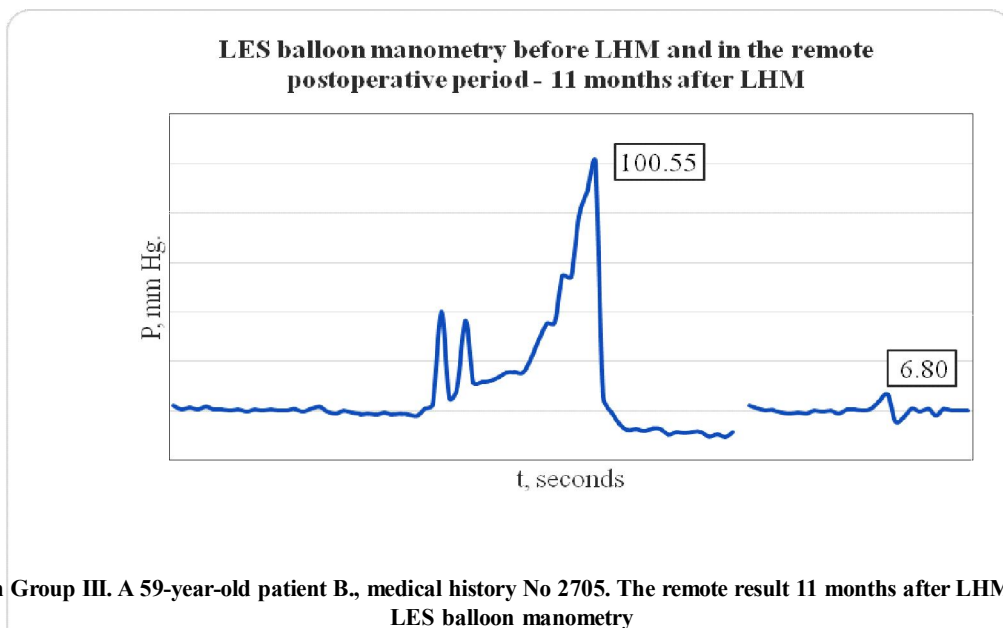


Fig. 8. AC in Group III. A 59-year-old patient B., medical history No 2705. The remote result 11 months after LHM. Dynamics of LES balloon manometry

Am J Gastroenterol. 2016;111(11):1536-1545. doi: 10.1038/ajg.2016.402.

9. Illés A, Farkas N, Hegyi P et al. Is Heller myotomy better than balloon dilation? A meta-analysis. J Gastrointest Liver Dis. 2017;26(2):121-127. doi: 10.15403/jgld.2014.1121.262.myo.

10. Esposito D, Maione F, D'Alessandro A et al. Endoscopic treatment of esophageal achalasia. World J Gastrointest Endosc. 2016;8(2):30-39. doi: [10.4253/wjge.v8.i2.30]

11. Rohof WO, Salvador R, Annese V et al. Outcomes of treatment for achalasia depend on manometric subtype. Gastroenterology. 2013;144(4):718-725. doi:10.1053/j.gastro.2012.12.027.

12. Boeckxstaens GE, Annese V, des Varannes SB et al. Pneumatic dilation versus laparoscopic Heller's myotomy for idiopathic achalasia. N Engl J Med. 2011;364(19):1807-1816. doi: 10.1056/NEJMoa1010502.

13. Cheng JW, Li Y, Xing WQ et al. Laparoscopic Heller myotomy is not superior to pneumatic dilation in the management of primary achalasia: Conclusions of a systematic review and meta-analysis of randomized controlled trials. Medicine (Baltimore). 2017;96(7):e5525. doi: 10.1097/MD.0000000000005525.

Ратчик В.М., Бабий А.М., Пролом Н.В., Шевченко Б.Ф.*

Діагностика і мініинвазивне лічення ахалазії кардії
ДУ «Інститут гастроентерології НАМН України»

* Aleksandr_babiy@ukr.net

Резюме. *Цель работы* – оцінити ефективність баллонної пневмокардиодилатації (ПКД) і лапароскопічної езофагокардіоміотомії Геллера (ЛМГ) в ліченні больних с ахалазією кардії.

Матеріали і методи. В відділенні хірургії с января 2016

года по июль 2018 года обследовано и проведено комплексное лечение с применением баллонной ПКД и ЛМГ у 21 пациента с диагнозом ахалазия кардии. Мужчин 8 (38,1 %), женщин 13 (61,9%) в возрасте от 28 до 75 лет (средний возраст (51,47±3,63) года). Длительность заболевания от одного месяца до 8 лет, в среднем (3,05 ± 0,49) года.

Результаты и обсуждение. С помощью лучевых методов исследования по диаметру пищевода пациенты были разделены на 4 группы: 1 группа с диаметром пищевода до 4 см – 5 (23,8%), 2 группа - 4-6 см – 6 (28,6%), 3 группа – 6-8 см – 5 (23,8 %), 4 группа - более 8 см с S-образно изогнутой конфигурацией – 5 (23,8%) пациентов. Достоверное уменьшение диаметра пищевода по данным флуороскопии (p<0,05), а также снижение давления в нижнем пищеводном сфинктере по данным манометрии (p<0,05) являются скрининговыми в оценке эффективности лечения АК после выполнения миниинвазивного вмешательства.

Осложнений при выполнении баллонной ПКД и ЛМГ не было.

Выводы. Рецидивы ахалазии кардии после баллонной ПКД установлены в сроки от 2-х до 10 мес у 33,3 % пациентов: у 4,7 % – в 1 группе и по 9,5 % случаев во 2, 3, 4 группах. При рецидивах АК в 23,8 % случаев повторное применение дилатации было неэффективно. Выполнена ЛМГ с фундопликацией по Дору, эффективность которой составила 80,0 % случаев.

Ключевые слова: ахалазия кардии, диагностика, баллонная пневмокардиодилатация, лапароскопическая эзофагокардиоміотомія Геллера, рецидивы.

Received: 15.12.2018

Revised: 18.12.2018

Accepted: 19.12.2018

DOI: 10.21802/gmj.2018.4.7

УДК 616.742+616-092.9+616.441-008.64

Саган Н.Т.

Становлення структурних компонентів жувальних м'язів у постнатальному онтогенезі та їх зміни при експериментальному йододефіциті

Кафедра анатомії людини

Івано-Франківського національного медичного університету

Резюме. Досліджуючи кровоносні судини жувальних м'язів, ми встановили структурну вікову перебудову, яка проявляється в збільшенні діаметра всіх ланок артеріального та венозного русла. Також з віком (у статевозрілих тварин) зростає кількість капілярів на одиницю площі та збільшується кількість капілярів, які кровопостачають одне м'язове волокно, що відповідає запитам при рості та розвитку м'язових волокон. Гістологічно та субмікроскопічно м'язові волокна набувають дефінітивної будови. Змінюється відсотковий розподіл різних типів волокон: зменшується кількість ОГМВ при одночасному зростанні ГМВ та майже незмінній кількості ОМВ, що свідчить про зниження окисних процесів і підтверджується незначним збільшенням об'ємної частки мітохондрій в ОМВ та незначним зниженням їх частки в інших типах м'язових волокон порівняно зі значним зростанням об'ємної частки міофібрил.

В умовах йододефіциту ми спостерігали зміни в діаметрі просвіту всіх ланок артеріального та венозного русла: звуження артеріальних та розширення венозних судин. Можна відмітити

потовщення артеріальної стінки внаслідок набряку всіх її оболонок. Ці зміни більш виражені у судинах жувальних м'язів нестатевозрілих тварин, що підтверджуються морфометричним дослідженням. Також зменшується кількість гемокapілярів. Ультрамікроскопічно в ендотеліоцитах також відмічаються набрякові явища. При гістологічному дослідженні м'язових волокон спостерігаються зміни в кількісному складі різних їх типів з тенденцією до зменшення кількості ОГМВ з одночасним зростанням ГМВ. Також відмічається збільшення площі поперечного перерізу всіх типів м'язових волокон. При ультрамікроскопічному дослідженні спостерігаються набрякові зміни м'язових волокон, найбільше в ГМВ. Також відбувається збільшення об'ємної частки мітохондрій та об'ємної частки міофібрил у м'язових волокнах, що свідчить про набрякові зміни в цих структурах та напруженість окисних процесів.

Ключові слова: онтогенез; гемомікроциркуляторне русло; жувальний м'яз; йододефіцит.