

## DERMATOLOGY

*Bilovol A.M., Tkachenko S.G., Volovik O.V.*


# APPLICATION OF DERMATOSCOPY IN THE MANAGEMENT OF SCABIES

(Case)

Kharkiv National Medical University, Ukraine

**Abstract:** *The article presents a case report on the employment of entomodermoscopy in diagnosis of scabies. Clinical studies of scabies using dermatoscopy provide evidence that the new method helps to improve therapy and reduce the term of medication. As of today dermoscopic patterns of scabies have been identified. We presented our experience of dermatoscopy employment in the management of microscopically negative scabies and presented a clinical case of dermoscopically diagnosed scabies. As a result of treatment, the patient has been shown to have a dramatic improvement. Presented clinical case has shown effectiveness and importance of entomodermoscopy in the improvement of parasitosis diagnosis and patient's compliance.*

**KeyWords:** *scabies, dermoscopy, entomodermoscopy.*



## INTRODUCTION

Dermatoscopy ranks high among new diagnostic techniques nowadays. This method helps to diagnose scabies quickly and does not require special preparation of the patient. Advantages of this method also comprise non-invasive nature of the procedure, patient comfort and portability of the equipment. Clinical studies of scabies using dermatoscopy provide evidence that the new method can optimize therapy and adjust the terms of medication. This is important to minimize the risks of excessive or insufficient treatment, reduce the risk of side effects and promote patient's compliance, particularly in cases of residual itching after therapy [1, 2].

Previous studies described the following dermoscopic patterns of scabies: delta and ovoid structures, similar to "jet trails" providing a possibility to diagnose parasitosis and due to non-invasive nature it is well-perceived by the patient. Dermatoscopy can identify mite eggs, excrement and burrows in the skin [3, 4].

The first reports on dermatoscopy in diagnosis of scabies were published by Argenziano et al. [5]. Their study showed the abovementioned dermoscopic pattern resembling "jet trails" in 93% of patients infected by *Sarcoptes scabiei* var. *hominis*. Microscopic studies showed that the brown triangle corresponds to the anterior part of the mite (mouth and anterior pair of legs). Posterior part of the mite is invisible that is why the abdomen and posterior pair of legs appears translucent. The mite burrow corresponds to "jet trails" and may contain feces seen as small brown dots. According to their recommendations, in crusted scabies (*scabies crustosa*) at 10-fold magnification multiple mites can be identified as brown-gray triangles at the end of a whitish winding burrow leaving no doubt as to the diagnosis. More recent studies confirmed these findings and fixed the value of dermatoscopy in diagnosis of scabies [6, 7].

## CASE DESCRIPTION:

A 36-year-old single male was admitted to the in-patient department of Kharkiv City Clinical Hospital of Skin and Venereal Diseases No.5 with diagnosis of allergic dermatitis. On admission he presented with intense itching for a month, which became worse in the evening. He was not

---

### • Corresponding Author:

*Svitlana Tkachenko, MD, PhD, Professor, Department of Dermatology, Venereology and Cosmetology, Kharkiv National Medical University, Ukraine. E-mail: [svetmail@mail.ru](mailto:svetmail@mail.ru)*

able to provide any apparent reason for itching. Three months ago he consulted an outpatient dermatologist and was referred to microscopic studies to identify scabies which gave negative results.

The diagnosis allergic dermatitis was made.

The following treatment was administered: loratadine 1 table once a day No. 14; 10% calcium gluconate solution 10 ml IV once a day No.10; Clemastine solution 2 ml IM two times a day No.10, topical applications of methylprednisolone aceponate cream two times a day. The patient reported a decrease in itching during treatment, but the character and intensity of symptoms resumed after the course of therapy.

Status localis: skin is light beige, turgor and elasticity are within norm, skin type II. There are some diffuse bright pink rounded and elongated spots up to 5 mm in diameter and bright pink papules of 3-5 mm in diameter on the skin of trunk and extremities. He is also found to have linearly arranged papules and vesicles on the skin of the corpus penis. Some of the lesions are covered with hemorrhagic crusts.

The results of microscopical examination for *Sarcoptes scabiei* are negative.

Dermatoscopy findings. Dermatoscopy examination was carried out by "Aramo" video dermatoscope at 10-fold, 20-fold and 60-fold magnification. Dermatoscopy of the abdomen showed some paired follicular papules, covered with hemorrhagic crusts (Figure 1).

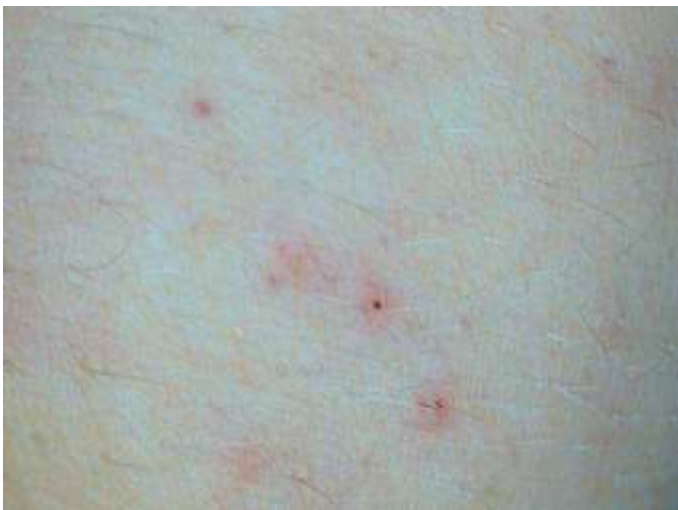

Fig.1.Paired follicular papules on the belly skin×10

The mite burrow with several holes linearly located on papulovesicular lesions (Figure 2) was detected by dermatoscopy of the penis. Dermatoscopy of the buttocks determined typical mite burrow filled with liquid.

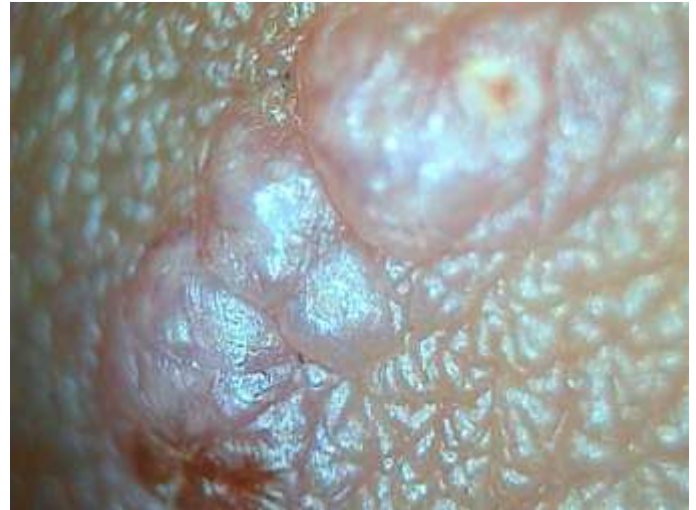

Fig.2.The mite burrow the skin of penis×60

The body of mite was visualized at the end of the burrow. Examination also revealed "jet trails" pattern in the form of small brown dots which usually contain feces of *Sarcoptes scabiei* (Figure 3).

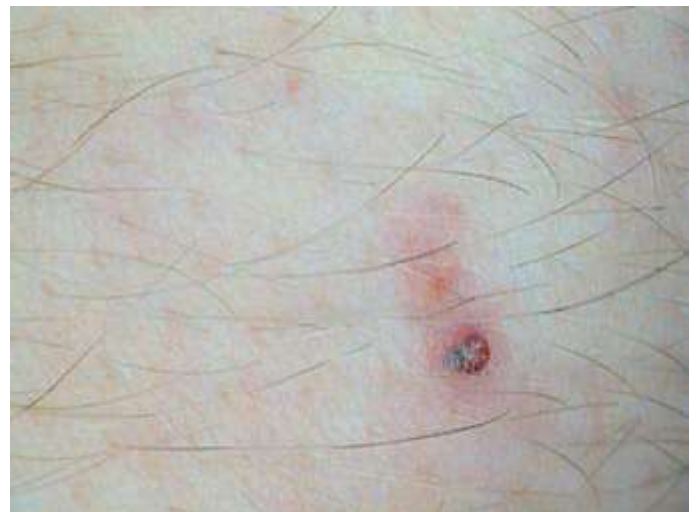

Fig. 3. The borrow on the skin of buttocks ×20.

According to dermatoscopy findings, the patient was prescribed ex juvantibus treatment of scabies: fixed combination of piperonyl butoxide and esdepallethrine as aerosol topically, disinfestation of linen and clothes.

As a result of treatment, the patient reported a significant reduction in itching as early as in the first night and complete disappearance of subjective symptoms for three days. Eruptions on the skin completely resolved within five days.

## CONCLUSIONS

Nowadays dermatoscopy is rarely used by dermatologists to manage scabies. However, identified dermatoscopic patterns give a possibility to diagnose this parasitosis. The presented case report demonstrates practical effectiveness of entomodermoscopy for in-patient management of scabies. The study confirms greater sensitivity of dermatoscopy in diagnosis of scabies as compared to visual inspection and microscopic examination. In our opinion, dramatic improvement during treatment is due to elimination of sensitizing by previous antiallergic treatment. Therefore, immobilization and destruction of the parasite were accompanied by a very rapid disappearance of subjective and objective manifestations of dermatosis. Our study has shown the effectiveness and significance of dermatoscopy in diagnosis of scabies in practical clinical work.

## REFERENCES

1. Francesco Lacarrubba et al. (2010) Use of dermatoscopy and videodermatoscopy in therapeutic follow-up: a review, *International Journal of Dermatology*, 49, 866-873.
2. Zalaudek I, Giacomel J, Cabo H, et al. (2008) Entomodermoscopy: a new tool for diagnosing skin infections and infestations, *Dermatology*, 216, 14-23.
3. *Dermatoscopy in clinical practice*. Pod red. N.N.Potekayev., M.: Studiya MDV, 144.
4. Gentiane Monsel, Olivier Chosidow (2012). Management of Scabies, *Skin Therapy Letter*, 2012 17(3).
5. Argenziano G, Fabbrocini G, Delfino M. (2007) Epiluminescence microscopy. A new approach to in vivo detection of *Sarcoptes scabiei*, *Arch Dermatol.*, 133, 751-753.

6. Bauer J. et al. (2001) Nodular scabies detected by computed dermatoscopy, *Dermatology*, 203, 190-191.
7. Prins C et al. (2004) Dermoscopy for the in vivo detection of *Sarcoptes scabiei*, *Dermatology*, 208, 241-243.

## РЕЗЮМЕ

Біловол А.М., Ткаченко С.Г., Воловік О.В.  
ВИКОРИСТАННЯ ДЕРМОСКОПІЇ У ВЕДЕННІ КОРОСТИ  
Харківський національний медичний університет,  
Україна

Стаття є описом клінічного випадку практичного використання ентомодермоскопії в діагностиці корости. Результати клінічних досліджень корости з використанням дермоскопії показали, що новий метод сприяє оптимізації терапії та скорочує строки використання ліків. На сьогодні вивчені дермоскопічні паттерни корости. Ми навели свій власний досвід використання дермоскопії у менеджменті мікроскопічно негативної корости та представили клінічний випадок дермоскопічно діагностовано корости. В результаті скабіцидного лікування пацієнт продемонстрував драматичне покращення. Наведений клінічний випадок показав корисність і значимість ентомодермоскопії у покращенні діагностики паразитоза та комплайнса пацієнта.

**Ключові слова:** короста, дермоскопія, ентомодермоскопія

## РЕЗЮМЕ

Беловол А.Н, Ткаченко С.Г., Воловик О.В.  
ИСПОЛЬЗОВАНИЕ ДЕРМОСКОПИИ В ВЕДЕНИИ ЧЕСОТКИ  
Харьковский национальный медицинский  
университет, Украина

Статья представляет собой описание клинического случая практического использования энтомодермоскопии в диагностике чесотки. Результаты клинических исследований чесотки с использованием дермоскопии показали, что новый метод способствует оптимизации

терапии и сокращать сроки применения лекарств. На сегодняшний день описаны дермоскопические паттерны чесотки. Мы представили свой опыт использования дермоскопии в менеджменте микроскопически негативной чесотки и представили клинический случай дермоскопически диагностированной чесотки. В результате скабицидного лечения пациент продемонстрировал драматическое улучшение. Представленный клинический случай показал полезность и значимость энтомодермскопии в улучшении диагностики паразитоза и коплай-са пациента.

**Ключевые слова:** чесотка, дермоскопия, энтомодермскопия

Received: 21-Feb. - 2016

Accepted: 29-Mar. - 2016