

УДК 616.132-089

G.B. Torsello^{1,2}, **G.F. Torsello**¹¹ St. Franziskus-Hospital, Münster, Germany² Center of Vascular and Endovascular Surgery, Münster University Hospital, Münster, Germany

Extending treatment choices for thoracic endovascular aortic repair. Experience from a large case series at a busy European endovascular center *

Thoracic endovascular aortic repair is the standard of care in the treatment of many thoracic aortic pathologies in most clinical settings. Graft design and patient anatomy heavily influence treatment success. The Zenith Alpha Thoracic Endovascular Graft (Cook Medical) is designed to better conform to unfavorably angled aortic arches and to overcome challenging access vessel anatomy with a low-profile introduction system.

Key words: thoracic endovascular aortic repair.

Device description

The Zenith Alpha Thoracic device has been described in detail elsewhere [13]. It was developed on the basis of the durable platform of the Zenith TX2 Endovascular Graft (Cook Medical), with features such as durable proximal fixation and a two-piece system, and has demonstrated safe and effective clinical performance.

The first main feature of this device is the use of a braided polyester graft material with a tighter weave and self-expanding nitinol stents affixed with monofilament polypropylene sutures, resulting in a markedly reduced profile without compromising durability. The second main feature is the precurved introduction system, which, in combination with the proximal bare stent, optimizes the conformability of the graft with the inner curvature of the aorta.

Clinical performance

In this case series, we included all patients treated with Zenith Alpha at our institution from August

2010 to October 2015. In total, 112 consecutive patients were treated for penetrating aortic ulcers or thoracic aneurysms. The patient characteristics are summarized in *Table*. A considerable proportion of patients had urgent or emergency procedures (12.5 % and 10.7 %, respectively). In 41 patients (36.6 %), access vessels were heavily calcified. The mean minimal iliac diameter was 5.98 mm (± 1.74 mm), and the mean iliac tortuosity index was 1.3 (± 0.18) [12]. Most patients were treated entirely percutaneously (n=98, 87.5 %). Four patients required iliac access via a conduit (3.6 %). Cerebrospinal fluid drainage was utilized in 17 cases (16 %).

The rate of technical success as defined by the reporting standards [2] was 99 %. In one case, the graft could not be advanced into the aortic arch due to heavy calcification and severe iliac stenosis. There was no postoperative aortic rupture or device migration within 30 days. In total, there were eight access vessel complications (7.1 %), including three iliac artery dissections (2.7 %) that were caused by advancing the introduction system

* Supplement to Endovascular Today.– 2016.– Vol. 15, N 5.– P. 6–8.

Table
Patient characteristics

Patient Characteristic	n (%) or mean (\pm SD)
Mean age	70.4 (\pm 9.3)
Men / women	47 / 58
Arterial hypertension	101 (90 %)
Smoking	36 (32 %)
Cerebrovascular disease	15 (13.4 %)
Coronary artery disease	39 (34.8 %)
Elective procedure	86 (76.8 %)
Urgent procedure	14 (12.5 %)
Emergency procedure	12 (10.7 %)

through tortuous and small access vessels and five pseudoaneurysms of the common femoral artery (4.5 %) that necessitated a secondary intervention. Two patients experienced persistent spinal cord injury (1.8 %); one of these patients received intraoperative CSF drainage, whereas the other one did not.

Discussion

Today, it is possible to treat a variety of thoracic aortic pathologies, especially with the introduction of devices with greater trackability and flexibility. The technical success rate in this patient group correlates well with the previously published results of this and other devices [2, 4, 5]. The same applies to results on mortality, complication, and reintervention rates. Remaining challenges of thoracic endovascular aortic repair (TEVAR), such as device apposition and fixation, are increasingly addressed by Zenith Alpha and other newer-generation devices (*Figure*). However, access vessel anatomy remains a major predictor for perioperative complications, as well as a limiting factor for treatment eligibility.

Female, Asian, and young patients have an especially greater share of thoracic compared to abdominal aortic pathologies [10], and they also represent a group of patients who commonly have smaller iliac diameters [5]. However, treating the thoracic aorta necessitates larger devices (and thus, larger-bore sheaths) compared to treating the abdominal aorta [6]. Patients with small access vessels are subject to a higher rate of access-related complications such as rupture, dissection, and pseudoaneurysm of the access vessel. The morbidity burden of these patients can be further increased by the necessity of more-invasive access methods (eg, iliac conduits) [1]. Not surprisingly, the sheath size rela-

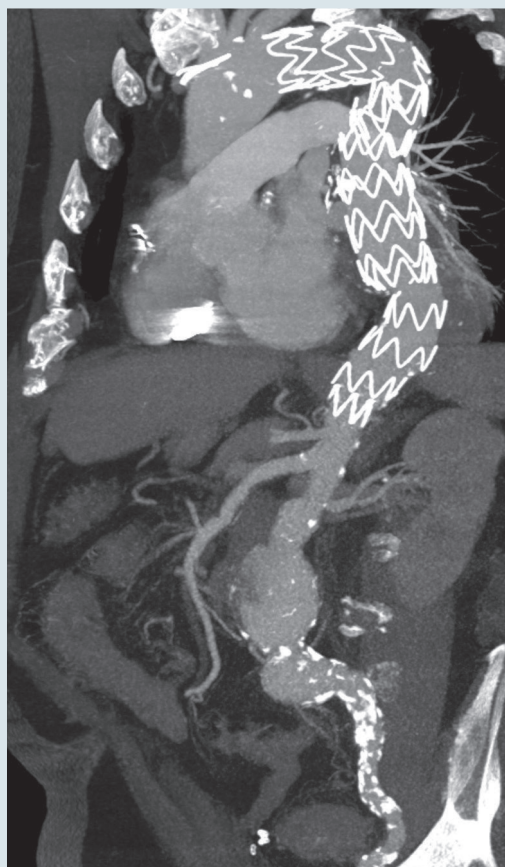


Figure. CT angiographic reconstruction showing the Zenith Alpha Thoracic device in a 72-year-old patient with aneurysmal disease of the thoracic, thoracoabdominal, and abdominal segments. Note the alignment of the stent graft with the tortuous aortic segments, as well as the presence of heavily calcified iliac arteries

tive to the access vessel diameter determines the access vessel complication rate [9], which ranged between 9 % and 21 % in the pivotal studies [3, 7, 8]. By having smaller access vessels, women tend to experience greater morbidity because of access vessel complications and more-invasive access methods [5].

Of note, access vessel morphology was unfavorable, even in this all-comer sample of patients treated with Zenith Alpha, with a mean minimum iliac artery diameter of 5.98 mm and tortuous iliac arteries (tortuosity index 1.3). Despite heavily calcified access vessels in 36.6 % of the cases, the technical success rate of Zenith Alpha remained comparable to those of other devices in more favorable anatomy.

Applicability is an even more important consideration for this device. Although, to my knowledge, there are no sound data on the rate of patients not anatomically suitable for TEVAR due to access ves-

sel morphology. It can be hypothesized that a considerable number of female or Asian patients cannot be treated with most grafts, simply due to prohibitively small access vessel diameters.

Furthermore, if these patients do qualify for TEVAR in terms of access vessel diameters, a considerable number of them cannot be treated due to iliac tortuosity. This is reflected in a large proportion of patients treated with Zenith Thoracic Alpha who

previously underwent failed treatment attempts with other grafts [12].

Conclusion

In conclusion, Zenith Alpha not only performs safely and effectively, but it also provides extended applicability to patients with challenging access vessel morphology.

References

1. Arnaoutakis G.J., Schneider E.B., Arnaoutakis D.J. et al. Influence of gender on outcomes after thoracic endovascular aneurysm repair // *J. Vasc. Surg.*–2014.– Vol. 59.– P. 45–51.
2. Chaikof E.L., Blankensteijn J.D., Harris P.L. et al. Reporting standards for endovascular aortic aneurysm repair // *J. Vasc. Surg.*– 2002.– Vol. 35.– P. 1048–1060.
3. Fairman R.M., Criado F., Farber M. et al. Pivotal results of the Medtronic Vascular Talent Thoracic Stent Graft System: the VALOR Trial // *J. Vasc. Surg.*– 2008.– Vol. 48.– P. 546–554.
4. Illig K.A., Ohki T., Hughes G.C. et al. One-year outcomes from the international multicenter study of the Zenith Alpha Thoracic Endovascular Graft for thoracic endovascular repair // *J. Vasc. Surg.*– 2015.– Vol. 62.– P. 1485–1494.
5. Jackson B.M., Woo E.Y., Bavaria J.E. et al. Gender analysis of the pivotal results of the Medtronic Talent Thoracic Stent Graft System (VALOR) trial // *J. Vasc. Surg.*– 2011.– Vol. 54.– P. 358–363.
6. Katzen B.T., Dake M.D., MacLean A.A. et al. Endovascular repair of abdominal and thoracic aortic aneurysms // *Circulation.*– 2005.– Vol. 112.– P. 1663–1675.
7. Makaroun M.S., Dillavou E.D., Wheatley G.H. et al. Five-year results of endovascular treatment with the Gore TAG device compared with open repair of thoracic aortic aneurysms // *J. Vasc. Surg.*–2008.– Vol. 47.– P. 912–918.
8. Matsumura J.S., Cambria R.P., Dake M.D. et al. International controlled clinical trial of thoracic endovascular aneurysm repair with the Zenith TX2 endovascular graft: 1-year results // *J. Vasc. Surg.*– 2008.– Vol. 47.– P. 247–257.
9. Nienaber C.A., Kische S., Ince H. Thoracic aortic stent-graft devices: problems, failure modes, and applicability // *Semin. Vasc. Surg.*– 2007.– Vol. 20.– P. 81–89.
10. Orandi B.J., Dimick J.B., Deeb G.B. et al. A population-based analysis of endovascular versus open thoracic aortic aneurysm repair // *J. Vasc. Surg.*– 2009.– Vol. 49.– P. 1112–1116.
11. Patterson B., Holt P., Nienaber C. et al. Aortic pathology determines midterm outcome after endovascular repair of the thoracic aorta: report from the Medtronic Thoracic Endovascular Registry (MOTHER) database // *Circulation.*– 2013.– Vol. 127.– P. 24–32.
12. Torsello G.F., Austermann M., Van Aken H.K. et al. Initial clinical experience with the Zenith Alpha Stent Graft // *J. Endovasc. Therapy.*– 2015.– Vol. 22.– P. 153–159.
13. Torsello G.F., Torsello G.B., Austermann M. Zenith TX2 Low Profile TAA Endovascular Graft: a next generation thoracic stent-graft // *J. Cardiovasc. Surg.*– 2012.– Vol. 53.– P. 153–159.

G.B. Torsello^{1,2}, **G.F. Torsello**¹

¹ Шпиталь Святого Франциска, Мюнстер, Німеччина

² Центр судинної та ендovasкулярної хірургії університетського шпиталю, Мюнстер, Німеччина

Розширення вибору лікування для торакальної ендovasкулярної корекції аорти. Досвід лікування великої кількості пацієнтів у Європейському центрі з ендovasкулярних втручань

Торакальна ендovasкулярна корекція аорти – стандарт допомоги при багатьох видах патології грудної аорти, який може бути застосований у більшості клінічних ситуацій. Успіх лікування дуже залежить від дизайну протеза та анатомії пацієнта. Протез Zenith Alpha Thoracic Endovascular Graft (Cook Medical) задуманий для забезпечення кращої відповідності аортальній дузі з несприятливим кутом і подолання складної анатомії судини з допомогою системи низькопрофільного введення.

Ключові слова: торакальна ендovasкулярна корекція аорти.

G.B. Torsello^{1,2}, **G.F. Torsello**¹

¹ Госпіталь Святого Франциска, Мюнстер, Германия

² Центр сосудистой и ендovasкулярной хирургии университетского госпиталя, Мюнстер, Германия

Расширение выбора лечения для торакальной эндovasкулярной коррекции аорты. Опыт лечения большого количества пациентов в Европейском центре эндovasкулярных вмешательств

Торакальная эндovasкулярная коррекция аорты – стандарт помощи при многих видах патологии грудной аорты, который может быть применен в большинстве клинических ситуаций. Успех лечения сильно зависит от дизайна протеза и анатомии пациента. Протез Zenith Alpha Thoracic Endovascular Graft (Cook Medical) задуман для обеспечения лучшего соответствия аортальной дуге с неблагоприятным углом и преодоления сложной анатомии сосуда с помощью системы низькопрофільного введения.

Ключевые слова: торакальная эндovasкулярная коррекция аорты.