

UDC 615.361:618.38+616-007.12



Jae Sun Shim, Kyounghoon Min, MinYoung Kim

CHA Bundang Medical Center, CHA University, Seongnam-si, Republic of Korea

e-mail: kmin@cha.ac.kr

ALLOGENIC UMBILICAL CORD BLOOD TRANSPLANTATION FOR A CHILD WITH CHROMOSOMAL ABNORMALITY: A CASE REPORT

ABSTRACT

A quite number of patients with global developmental delay (*GDD*) or mental retardation (*MR*) have chromosomal abnormalities. Comprehensive rehabilitation therapy helps improve the clinical functions of the patients, but there is no fundamental treatment option for *GDD* or *MR*. Umbilical cord blood transplantation (*UCBT*) showed its safety and efficacy through a lot of animal studies and some clinical trials to date. Erythropoietin (*EPO*) is an option for adjunctive therapy when combined with cell therapy. We treated a child who had *GDD* and complex chromosome rearrangement with an allogenic *UCBT* and concurrent *EPO* injections, and observed clinical improvements, and confirmed the safety of the procedure.

KEY WORDS: global developmental delay, complex chromosome rearrangement, allogenic umbilical cord blood, erythropoietin.

Global developmental delay (*GDD*) is a subset of developmental disabilities defined as significant delay in two or more of the following developmental domains: gross/fine motor, speech/language, cognition, social/personal, and activities of daily living [1]. Approximately 10 % of children who have a *GDD* or mental retardation have an underlying cytogenetic abnormality [2].

Despite a variety of treatment options for *GDD* by the multidisciplinary team including psychologist, occupational therapist, speech therapist, and social worker [3], we cannot usually change the natural course of disease, whether it takes a deteriorating course or a gradually resolving one.

Umbilical cord blood transplantation (*UCBT*) have been attempted in several mice studies for treatment of various neurologic conditions such as ischemic [4], and hemorrhage stroke [5], traumatic brain injury [6], and Alzheimer disease [7]. Moreover, *UCBT* for children with inherited metabolic disorders, such as Hurler syndrome and Krabbe disease had an effect in prevention of neurological deterioration, and even caused cognitive improvement [8, 9].

Erythropoietin (*EPO*), a glycoprotein hormone that controls erythropoiesis, also has neuroprotective characteristics reported in several studies using animal models for stroke [10] and traumatic brain injury [11]. Neuroregenerative and angiogenic effects of *EPO* in injured brain tissues have also been reported [12]. As a neurotrophic factor, *EPO* served as an adjunctive option for combination therapy to potentiate the efficacy of cell therapy [13]. Recently, our research team reported on the safety and efficacy of allogenic *UCBT* with concurrent *EPO* injection in children with cerebral palsy in a randomized, placebo-controlled trial [14].

We also tried to apply the therapeutic strategy to a *GDD* child

with expectation of favorable neurotrophic effect on brain function development. Since the result showed noticeable efficacy, we report on the combination therapy of allogenic *UCBT* with concurrent *EPO* injection for a child with *GDD* who had chromosomal abnormality.

PATIENT AND METHODS

PATIENT

A 4-year-8-month-old boy was born at full-term to healthy non-consanguineous parents. Except for 2 days of oxygen supply due to delayed crying at birth, no remarkable perinatal event had occurred. Birth weight was 2600 g (3rd centile), lengths 47 cm (5th centile), and occipital-frontal circumference (*OFC*) 32.1 cm (5th centile). Screening of inherited metabolic disorders by tandem mass spectrometry showed no prominent abnormality. Not being able to sit alone at the age of 10 months, he started receiving comprehensive rehabilitation including exercise and occupational therapy, and also speech therapy for more than a year. Nonetheless, when he first visited our hospital at 4 years and 4 months, all domains including gross and fine motor skills, cognition, speech, and social behavior were severely delayed (**Table 1**). Until the first visit to our institute, he did not stop receiving rehabilitation therapy for cognitive and motor development. His growth parameters were above average; height, 108 cm (75th centile), weight, 18.0 kg (75th centile), and *OFC*, 51 cm (50th centile). He had no apparent facial dysmorphism or skeletal anomalies. A physical examination revealed no abnormal neurologic signs such as pathologic reflexes, weakness and hyper- or hypotonia. He had no history of other medical problems such as seizure and cardiac anomaly.

He showed normal function by audiologic and ophthalmologic evaluations. However, with previously diagnosed mental retardation of mild to moderate degree, he had difficulty in interaction with other people. For language ability, he was only able to understand simple commands, and he had very limited expressive language skills, speaking only 5 words, such as «mom», «dad», «yes», «this», «that», and two words combination sentence was not produced.. He had minor motor problems, especially in balancing himself while walking independently, and was barely able to climb up the stairs holding onto the rail. Standing on one leg, jumping, and running were unachievable. He had clumsy hands, having difficulty in fastening a button. Conventional brain magnetic resonance imaging (MRI) showed no focal or gross abnormality (Fig. 1A). ^{18}F -fluorodeoxyglucose positron emission tomography (^{18}F -FDG-PET/CT) scanning showed relative decreased glucose metabolism in bilateral thalamus, basal ganglia, and cerebellum (Fig. 2A). His chromosomal analysis in another medical institute found a complex chromosome rearrangements (CCR), the genotype of which was 46, XY, t(2;14;3)(q21.3;q11.2;q25.1).

UMBILICAL CORD BLOOD TRANSPLANTATION

An unrelated allogenic UCB unit, whose donor provided informed consents for the donation of UCB, was selected from CHA Medical Center Cord Blood Bank. The UCB unit matched high resolution HLA typing for 4 of 6 for A, B, and DRB1 antigens of our patient. The number of UCB cells, as total nucleated cells, was $4.93 \times 10^7/\text{kg}$. Just after washing the frozen UCB unit to remove dimethyl sulfoxide [15], it was administered via peripheral intravenous route slowly. The patient received cyclosporine as an immunosuppressant for 4 weeks, which was given from 24 hours before UCB administration. Dosages of immunosuppressants were adjusted to maintain the target ranges in blood, 100–200 ng/mL for cyclosporine. Recombinant human EPO (Espogen® LG life sciences, Seoul, Korea of Republic) was also given twice as 500 IU/kg intravenously at 12 hours before and subcutaneously at 24 hours after UCB administration. Injections of 250 IU/kg EPO subcutaneously twice per week for 4 weeks were followed. In-patient rehabilitation treatment was conducted by the same therapists and with the same strategies as before.

METHODS OF CLINICAL EVALUATIONS

For adverse event monitoring, we checked his vital signs during a month of hospitalization and follow-up visits until 6 months after the UCBT. We also asked to his parents about his medical problem after discharge for more than one year. As efficacy measures, Gross Motor Function Measure (GMFM), Bayley Scales of Infant Development, 2nd edition (BSID-II), Functional Independence Measure for Children (WeeFIM), and speech and language evaluations with Preschool Receptive-Expressive Language Scale and Sequenced Language Scale for Infants were conducted at before UCBT within a week, 1 month, 3 months, and 6 months after the UCBT. Also brain imaging studies were followed up to examine changes in his brain with diffusion tensor image (DTI) and ^{18}F -FDG-PET/CT. The DTI data were processed using DTI studio software (Johns Hopkins University and Kennedy Krieger Institute, Baltimore, USA). And Fractional anisotropy (FA) was measured at six different regions of interest: for the corticospinal tract, two loci in each posterior limb of the internal capsule (PLIC) for the spinothalamic tract, the posterior lower pons loci were assessed, also bilaterally [16].

RESULTS AND DISCUSSION

No serious adverse events were reported for more than a year after the therapeutic procedure. As adverse event, only once of acute pharyngitis was observed at 20 days after the UCBT, and it was sustained for 10 days and completely resolved.

His physical, occupational, and speech abilities were increased after UCBT (Table. 1). Among the assessments, his expressive language skills showed the biggest improvement. From the next day of UCBT, his mother reported changes in his language ability. Within a few days, he became able to understand the meaning of two new prepositions; «inside» and «above». The number of pronounceable words also increased to 10, such as «brother», «sister», «car», «milk», «ramen», and so on, during 1 month after UCBT. Also simple two words sentences like «Open it.», «Give me.», were occasionally produced. Imitation of verbal expression

| ASSESSMENT | 1 WEEK BEFORE UCBT | 1 MONTH AFTER UCBT | 3 MONTHS AFTER UCBT | 6 MONTHS AFTER UCBT |
|---|--------------------|--------------------|---------------------|---------------------|
| Chronological age | 4 yr 8 mo | 4 yr 9 mo | 4 yr 11 mo | 5 yr 2 mo |
| GMFM A, % (lying & rolling) | 100 | 100 | 100 | 100 |
| GMFM B, % (sitting) | 98 | 98 | 100 | 100 |
| GMFM C, % (crawling & kneeling) | 90 | 95 | 95 | 98 |
| GMFM D, % (standing) | 74 | 85 | 87 | 90 |
| GMFM E, % (walking & running & jumping) | 65 | 67 | 72 | 76 |
| GMFM total, % | 85 | 89 | 91 | 93 |
| BSID-II; mental age (raw score) | 22 mo (128) | 25 mo (136) | 26 mo (140) | 27 mo (142) |
| BSID-II; motor age (raw score) | 27 mo (91) | 27 mo (91) | 27 mo (91) | 30 mo (94) |
| WeeFIM; total score | 82 / 126 | 83* / 126 | 86 / 126 | 86 / 126 |
| Receptive language age | 23 mo** | 25 mo** | | 27 mo |
| Expressive language age | 14 mo | 15 mo | | 16 mo |

Table 1. Results of clinical assessments in the study subject.

BSID — the Bayley Scales of Infant Development, 2nd Edition; GMFCS — Gross Motor Function Classification System; GMFM — Gross Motor Function Measure; mo — months; UCBT — umbilical cord blood transplantation; WeeFIM — Functional Independence Measure for Children; yr — years.

* — One point increased in the expression of communication item.

** — Preschool Receptive-Expressive Language Scale (PRES) was used only for the first two assessments for receptive language age. Due to lack of compliance of the patient, the Sequenced Language Scale for Infants (SELSI) was used for all the other language assessments.

Table 2. Fractional anisotropy values before and after the UCBT.

| REGION OF INTEREST | 1 WEEK BEFORE | 6 MONTHS AFTER UCBT |
|---|---------------|---------------------|
| Posterior limb of internal capsule | | |
| Right anterior portion | 0.69 | 0.70 |
| Right posterior portion | 0.68 | 0.71 |
| Left anterior portion | 0.69 | 0.72 |
| Left posterior portion | 0.65 | 0.69 |
| Ascending sensory tract | | |
| Right side | 0.68 | 0.69 |
| Left side | 0.66 | 0.67 |

UCBT — umbilical cord blood transplantation.

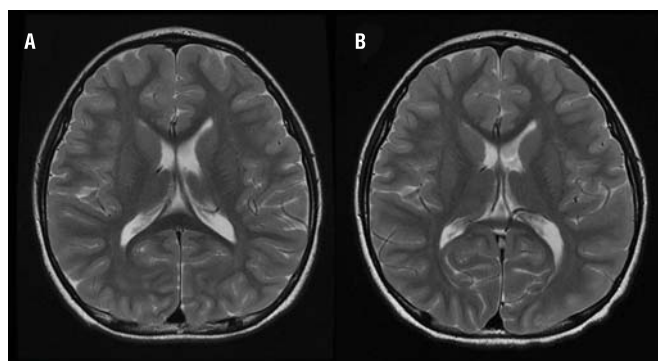


Fig. 1. Magnetic resonance images of the patient's brain. (A) 1 week before the umbilical cord blood transplantation: no focal abnormality in the brain parenchyma, (B) 6 months after the umbilical cord blood transplantation: no significant changes were observed.

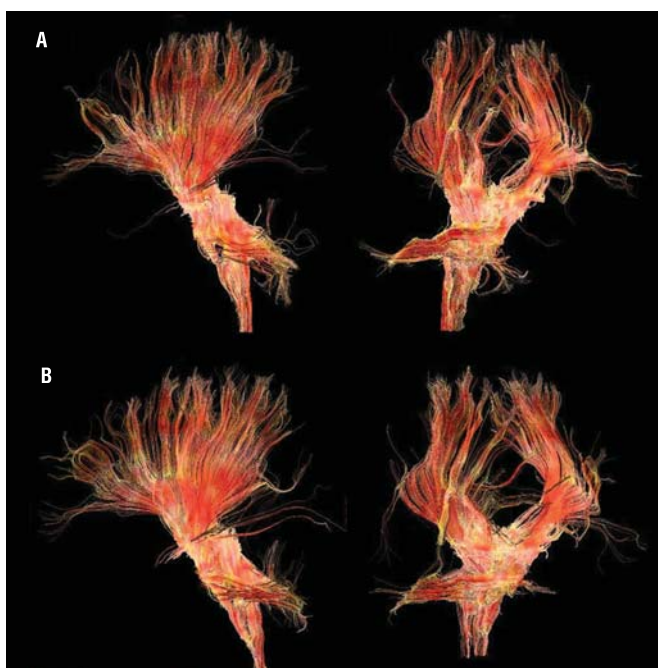


Fig. 2. Diffusion tensor tractographies of the patient's brain. (A) 1 week before the umbilical cord blood transplantation, (B) 6 months after the umbilical cord blood transplantation: increased nerve fibers in frontal and parietal areas.

in not only words but also in intonation, and use of onomatopoeia appeared distinctly more frequently than before. These improvements contributed to increase the "expression language age" by 2 months, which was assessed 1 month after the UCBT. Moreover, at 2 months after the UCBT, his mother reported that frequency of interaction with other people increased that he became able to respond 100 % of times which was not observed before.

In regard to cognitive functions, improvement in visuospatial recognition was observed to increase the age equivalent of mental scale of the *BSID-II*, from 22 to 25 months after a month. In reference to the *GMFM*, after the allogenic UCBT, he started standing on one leg for a few seconds, and the duration of bench sitting became longer and more stable than before.

The follow-up brain PET studies showed increased metabolism in bilateral thalamus and cerebellum at 2 weeks after UCBT compared to the previous one (Fig. 3). And the follow-up MRI (Fig. 1B) showed no difference compared to the old one. However, DTI showed slightly increased number of fibers throughout the brain at 6 months after UCBT (Fig. 2B). FA values were also increased in all measured loci (Table 2).

Complex chromosome rearrangements (CCR) are rearrangements involving at least three chromosomes and three or more breakpoints [17]. Patients with CCR show a wide variety of phenotypes according to its etiology; familial or de novo, and its constitutions; balanced or unbalanced [18]. In addition, the site and the number of breakpoints on chromosomes may have diverse influences on the roles of nearby genes in CCR. The breakpoints in this patient were included in the previous case reports that had developmental disabilities [19–21]. In the present case, he had GDD, but relatively mild mental retardation and gross motor delay with apparently normal appearances. Since his parents refused to undertake chromosome study, we assumed that this patient had an apparently balanced de novo CCR, which has relatively low possible estimate of the child developing phenotypical abnormalities [22].

UCB has several advantages over stem cells from other sources, such as bone marrow or peripheral blood. Above all, UCBT can be performed safely from unrelated donor with one or two HLA mismatches [13]. Both the UCB and EPO are known to have neurotrophic effects from neuroprotective, neurogenic, and vasculogenic properties [13, 23, 24]. Concerning the route of delivery of stem cells, it is reported that intravenous administration is safer and would be similarly effective when compared to other surgically invasive methods [25, 26]. And substantially, the child made a considerable clinical improvement after the allogenic UCBT, especially in expressive language ability, and additional minor advances appeared in gross motor and cognitive functions within a very short period.

It is difficult to abbreviate suggestive mechanism of neurodevelopmental improvement which was shown in this child. However, the efficacy in the early phase suggests neurotrophic effect of the UCBT although these improvements did not seem to keep this fast improving pace. During his active function gaining phase, the ^{18}F -FDG-PET/CT finding showed increased metabolism in thalamus and cerebellum. Previous studies about localized metabolism alteration in autistic spectrum disorders including GDD found no common regional abnormalities across cerebral blood flow or cerebral glucose metabolism [27]. However, consensus judgement suggests focal hypoperfused and hypometabolic areas in the thalamus, basal ganglia, parietal, temporal lobes, and cerebellum, and many of the areas are compatible with the present case [28, 29]. According to a recent trial for autism patients with bone marrow stem cell, they also showed similar finding with this result with increased glucose metabolism in cerebellum [30]. We can interpret this finding indicates favorable changes in brain networking that induces clinical improvements in expressive language, visual perception, and balance. Yet this interpretation has limitations. Viewing from another angle, the mechanism may have been related with disturbances from brain dysfunctions from genetic abnormality, even though the exact pathogenesis of the developmental disturbances cannot be clearly

understood. He had complex derangement of chromosomes, and copy number variation was not precisely detected in this case. Moreover, the translocation effect and significances of breakpoints [22] were not fully defined.

Taking a long-term view, his clinical improvement slowed down after the first month. Probably death of transplanted UCB cells caused decline in therapeutic efficacy. However, it does not seem the gained abilities vanished (**Table 1**). By DTI analysis, the number of nerve fibers and the FA values increased during the 6 months, which suggest increased axonal density or myelin volume [31]. We interpret this result as the effect of endogenous neural stem cell activation [32].

CONCLUSIONS

IN CONCLUSION, ALTHOUGH THERE ARE POSSIBLE CONTROVERSIES FROM RELATIVELY SHORT-DURATION EFFECT AND UNCLEAR MECHANISM, THE RESULTS IN THIS CASE SEEM TO BE SIGNIFICANT BY SHOWING REMARKABLE IMPROVEMENT IN LANGUAGE, COGNITION, AND MOTOR BEHAVIOR, AND CHANGES IN BRAIN WHITE MATTER AND GLUCOSE METABOLISM. FURTHER STUDIES TO INVESTIGATE THE MECHANISM OF NEUROTROPHIC EFFECTS OF THE UCBT ARE REQUIRED.

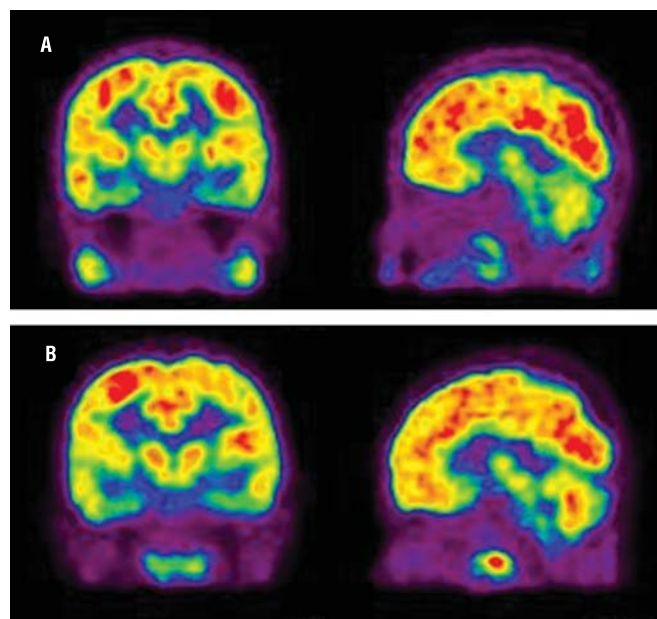


Fig. 3. ^{18}F -fluorodeoxy-glucose positron emission tomography findings at coronal and midsagittal sections of the patient's brain. **(A)** 1 week before the umbilical cord blood transplantation: low level of activity in bilateral thalamus, basal ganglia, and cerebellum, **(B)** 2 weeks after the umbilical cord blood transplantation: increased glucose metabolism in bilateral thalamus and cerebellum after the umbilical cord blood transplantation.

REFERENCES

1. Majnemer A., Shevell M. I. Diagnostic yield of the neurologic assessment of the developmentally delayed child // *J. Pediatr.* — 1995. — **127**, 2. — P. 193-199.
2. Moeschler J. B., Shevell M. American Academy of Pediatrics Committee on G. Clinical genetic evaluation of the child with mental retardation or developmental delays // *Pediatrics.* — 2006. — **117**, 6. — P. 2304-2316.
3. Tirosh E., Jaffe M. Global developmental delay and mental retardation—a pediatric perspective // *Dev. Disabil. Res. Rev.* — 2011. — **17**, 2. — P. 85-92.
4. Vendrame M., Cassady J., Newcomb J. et al. Infusion of human umbilical cord blood cells in a rat model of stroke dose-dependently rescues behavioral deficits and reduces infarct volume // *Stroke.* — 2004. — **35**, 10. — P. 2390-2395.
5. Nan Z., Grande A., Sanberg C. D. et al. Infusion of human umbilical cord blood ameliorates neurologic deficits in rats with hemorrhagic brain injury // *Ann. NY Acad. Sci.* — 2005. — **1049**. — P. 84-96.
6. Lu D., Sanberg P. R., Mahmood A. et al. Intravenous administration of human umbilical cord blood reduces neurological deficit in the rat after traumatic brain injury // *Cell Transplant.* — 2002. — **11**, 3. — P. 275-281.
7. Nikolic W. V., Hou H., Town T. et al. Peripherally administered human umbilical cord blood cells reduce parenchymal and vascular beta-amyloid deposits in Alzheimer mice // *Stem Cells Dev.* — 2008. — **17**, 3. — P. 423-439.
8. Dusing S. C., Thorpe D. E., Poe M. D. et al. Gross motor development of children with hurler syndrome after umbilical cord blood transplantation // *Phys. Ther.* — 2007. — **87**, 11. — P. 1433-1440.
9. Escolar M. L., Poe M. D., Martin H. R. et al. A staging system for infantile Krabbe disease to predict outcome after unrelated umbilical cord blood transplantation // *Pediatrics.* — 2006. — **118**, 3. — P. e879-889.
10. Asadi B., Askari G. R., Khorvash F. et al. Neuroprotective effects of erythropoietin in acute ischemic stroke // *Int. J. Prev. Med.* — 2013. — **4**, Suppl 2. — P. S306-312.
11. Mammis A., McIntosh T. K., Maniker A. H. Erythropoietin as a neuroprotective agent in traumatic brain injury. Review // *Surg. Neurol.* — 2009. — **71**, 5. — P. 527-531.
12. Iwai M., Cao G., Yin W. et al. Erythropoietin promotes neuronal replacement through revascularization and neurogenesis after neonatal hypoxia/ischemia in rats // *Stroke.* — 2007. — **38**, 10. — P. 2795-2803.
13. Koh S. H., Noh M. Y., Cho G. W. et al. Erythropoietin increases the motility of human bone marrow-multipotent stromal cells (hBM-MSCs) and enhances the production of neurotrophic factors from hBM-MSCs // *Stem Cells Dev.* — 2009. — **18**, 3. — P. 411-421.
14. Min K., Song J., Kang J. Y. et al. Umbilical cord blood therapy potentiated with erythropoietin for children with cerebral palsy: a double-blind, randomized, placebo-controlled trial // *Stem Cells.* — 2013. — **31**, 3. — P. 581-591.
15. Rubinstein P., Dobrila L., Rosenfield R. E., et al. Processing and cryopreservation of placental/umbilical cord blood for unrelated bone marrow reconstitution // *Proc. Natl. Acad. Sci. US A.* — 1995. — **92**, 22. — P. 10119-10122.
16. Min K., Yu S., Lee J. et al. Reliability of Fractional Anisotropy Measurement for Children with Cerebral Palsy // *Neuropediatrics.* — 2013. — in publishing.
17. Pai G. S., Thomas G. H., Mahoney W. et al. Complex chromosome rearrangements. Report of a new case and literature review // *Clin. Genet.* — 1980. — **18**, 6. — P. 436-444.

18. Madan K. What is a complex chromosome rearrangement? // *Am. J. Med. Genet. A.* — 2013. — **161A**, 5. — P. 1181-1184.
19. Monfort S., Blesa D., Rosello M., et al. Duplication of 14q11.2 associates with short stature and mild mental retardation: a putative relation with quantitative trait loci // *Am. J. Med. Genet. A.* — 2007. — **143**, 4. — P. 382-384.
20. Moortgat S., Verellen-Dumoulin C., Maystadt I. et al. Developmental delay and facial dysmorphism in a child with an 8.9 Mb de novo interstitial deletion of 3q25.1-q25.32: Genotype-phenotype correlations of chromosome 3q25 deletion syndrome // *Eur. J. Med. Genet.* — 2011. — **54**, 2. — P. 177-180.
21. Zahir F., Firth H. V., Baross A. et al. Novel deletions of 14q11.2 associated with developmental delay, cognitive impairment and similar minor anomalies in three children // *J. Med. Genet.* — 2007. — **44**, 9. — P. 556-561.
22. Madan K. Balanced complex chromosome rearrangements: reproductive aspects. A review // *Am. J. Med. Genet. A.* — 2012. — **158A**, 4. — P. 947-963.
23. Shao B., Cheng Y., Jin K. Estrogen, neuroprotection and neurogenesis after ischemic stroke // *Curr. Drug Targets.* — 2012. — **13**, 2. — P. 188-198.
24. Wang L., Zhang Z., Wang Y. et al. Treatment of stroke with erythropoietin enhances neurogenesis and angiogenesis and improves neurological function in rats // *Stroke.* — 2004. — **35**, 7. — P. 1732-1737.
25. Mezey E., Chandross K. J., Harta G. et al. Turning blood into brain: cells bearing neuronal antigens generated in vivo from bone marrow // *Science.* — 2000. — **290**, 5497. — P. 1779-1782.
26. Willing A. E., Lixian J., Milliken M. et al. Intravenous versus intrastriatal cord blood administration in a rodent model of stroke // *J. Neurosci. Res.* — 2003. — **73**, 3. — P. 296-307.
27. Pagani M., Manouilenko I., Stone-Elander S. et al. Brief Report: alterations in cerebral blood flow as assessed by PET/CT in adults with autism spectrum disorder with normal IQ // *J. Autism. Dev. Disord.* — 2012. — **42**, 2. — P. 313-318.
28. Rumsey J. M., Ernst M. Functional neuroimaging of autistic disorders // *Ment. Retard. Dev. Disabil. Res. Rev.* — 2000. — **6**, 3. — P. 171-179.
29. Chugani D. C. Neuroimaging and neurochemistry of autism // *Pediatr. Clin. North. Am.* — 2012. — **59**, 1. — P. 63-73.
30. Sharma A., Gokulchandran N., Sane H. et al. Autologous bone marrow mononuclear cell therapy for autism: an open label proof of concept study // *Stem Cells Int.* — 2013. — ID 623875. — <http://dx.doi.org/10.1155/2013/623875>.
31. Scheck S., Boyd R., Rose S. New insights into the pathology of white matter tracts in cerebral palsy from diffusion magnetic resonance imaging: A systematic review // *Dev. Med. Child. Neurol.* — 2012. — **54**. — P. 684-696.
32. Lichtenwalner R. J., Parent J. M. Adult neurogenesis and the ischemic forebrain // *J. Cereb. Blood Flow Metab.* — 2006. — **26**, 1. — P. 1-20.