

GLAUCOMA IN DOGS AND ITS TREATMENT WITH TIMOLOL

RAHMOUN DJALLAL EDDINE, *post graduation in morphology, oncology and animal pathology*

YOUHAN DIRMON, *veterinary doctor and medical specialist medicine in ophthalmology*

*Dnepropetrovsk State Agro-Economic University,
Dnepropetrovsk*

*Clinique d'ophtalmologie science et parcours,
Lyon, France*

deddine44@hotmail.com

youhandirmon@yahoo.com

Although glaucoma is the leading cause of blindness in dogs, the lack of a uniform definition of the disease in its various forms, it is difficult to assess the impact of animal health. Given the similarities between glaucoma, we analyzed available data on the three main forms of the disease: congenital glaucoma; open angle glaucoma and hereditary primary angle closure. A simple model was developed to estimate the extent of glaucoma on a regional basis, taking into account the research data; the results show that glaucoma is responsible for about 7% of blindness of the canine population. Thus, the use of timolol as treatment with a control voltage intra oculaure periodically has been effective in glaucoma with a success rate lower than 5 mmHg on average

Glaucoma, dogs, intraocular pressure, Timolol

Introduction. Canine glaucoma is a group of eye diseases characterized by increased intraocular pressure, incompatible with the normal functioning of the structures of the eye. Glaucoma is one of the most common causes of blindness in dogs. This is a relatively common disease. Aqueous humor is produced by the ciliary body cells and is secreted into the posterior chamber of the eye [1, 3]. It flows over the anterior surface of the lens, through the pupil and into the anterior chamber. The area of aqueous outflow, the iridocorneal angle, may be examined clinically with a corneal contact lens. Next the aqueous humor is resorbed into the bloodstream. A delicate balance between production and resorption maintains the normal intraocular pressure. The production of aqueous humor is not regulated by the intraocular pressure, however. Occlusion (blockage) of the primary outflow pathway, either at the pupil or iridocorneal angle, results in increased IOP (glaucoma) [2, 5]. In dogs, glaucoma is the result of poor drainage of aqueous humor out of the eye or its accumulation in the eye due to discomfort in circulation. Medical treatment is to reduce the secretion of aqueous humor or facilitate its evacuation.

Material and method. At the level of veterinary clinic of ophthalmology we have received a number of dogs develop glaucoma, identification of the animal performed by the reporting of race and age. The consultation showed beforehand after achieving an examines fundus, the sign of optic

nerve damage noticed with this control, the fundus is performed after an anesthesia of the animal, instillation of atropine sulphate is set for a dilation of the pupil. Examination of the fundus was performed 15 minutes after the instillations with an ophthalmoscope [Fig. 1]. The taking the intraocular pressure was performed after instillation of oxybuprocaine faure (HCl 1.6 mg / ml 0.4, eye drops in single dose), using a tonometer type Schulz [Fig. 1] kind of veterinary use before and after treatment with Timolol (Cusimolol Maleate 0.25mg/ml, 0.50mg/ml). This beta blocker eye drops has the property of reducing the pressure of fluids in the eye (intraocular pressure), this beta blocker eye drops has the property of reducing the pressure of fluids in the eye (intraocular pressure) [6, 8]. We used this treatment for dogs presenting excess intraocular pressure in dogs. However, normalization of intraocular pressure sometimes requires several weeks as treatment evaluation should it include a measure of intraocular pressure after a treatment period of approximately 4 weeks. The results are recorded daily on pc control and treat with excel SDX3.

Results and discussion. The treatment of chronic open-angle glaucoma is mainly based on the ocular hypertension which is frequently associated. Apart from the more serious cases where surgery is required when the diagnosis is made, the first therapy is medical. Monitoring should focus on the regular assessment of intraocular

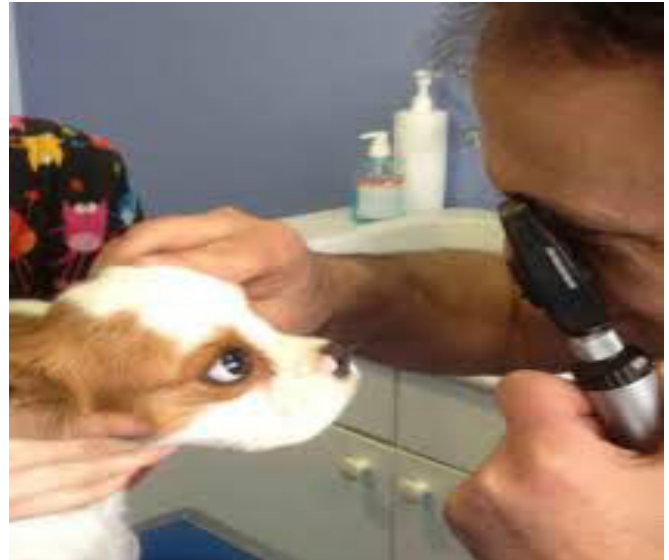
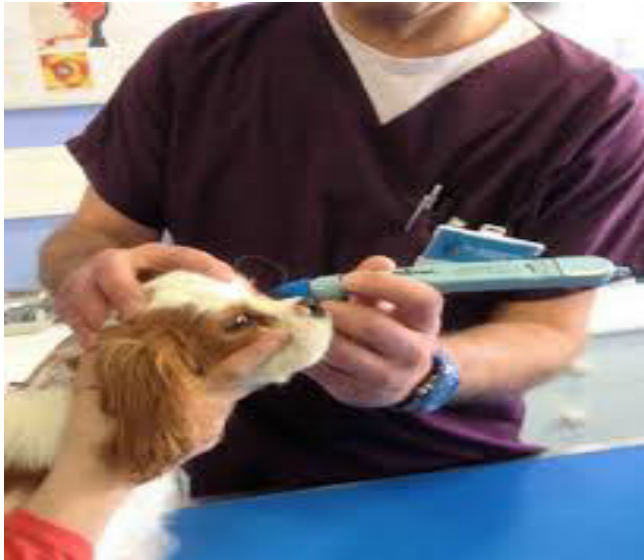
Fig 1. Taking intraocular pressure and fundus examination of a dog

pressure, the appearance of the optic nerve and visual field. Generally [9], a recording of the visual field is carried out every 6-12 months and therapy is possibly modified in case of unfavorable visual field or optic nerve. In our practice was used an anti glaucoma (NB timolol 0.25 and 0.50).

Our clinical studies showed that dogs with intraocular pressures untreated 22 mmHg 32mmHg, timolol ophthalmic solution 0.25 percent, or 0.5 percent administered twice a day produced a greater reduction intraocular pressure at 1, 2, 3, or 4 percent, It was noted that the intraocular pressure falls below 20 mm Hg, and then it is considered that the animal responds well to treatment undertaken. In this case, one

must continue processing and perform a control one month later. The examination of the fundus showed in some dogs glaucomatous excavation with papillary bleeding less confirms glaucoma which they explained elsewhere[10, 11]. There is no figure of intraocular pressure resulting systematic chronic glaucoma, while the risk for developing glaucoma is greater as the pressure is high. There are about 10 times more subjects with ocular hypertension than glaucoma. Although the majority of glaucoma is accompanied by hypertension, ocular hypertension, Ocular hypertension carries here a mechanism quite different from that at stake in the closure glaucoma angle. In glaucoma, elevated intraocular pressure is associated with a progressive degeneration of the trabecular meshwork. From this

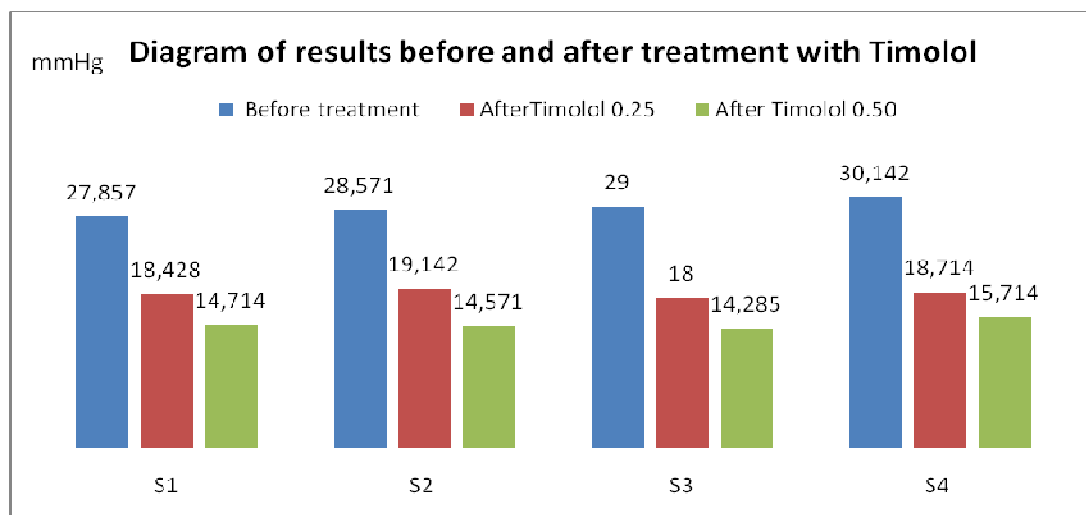


Fig. 2. Results observed with treatment (Cusimolol Maleate 0.25mg/ml, 0.50mg/ml)

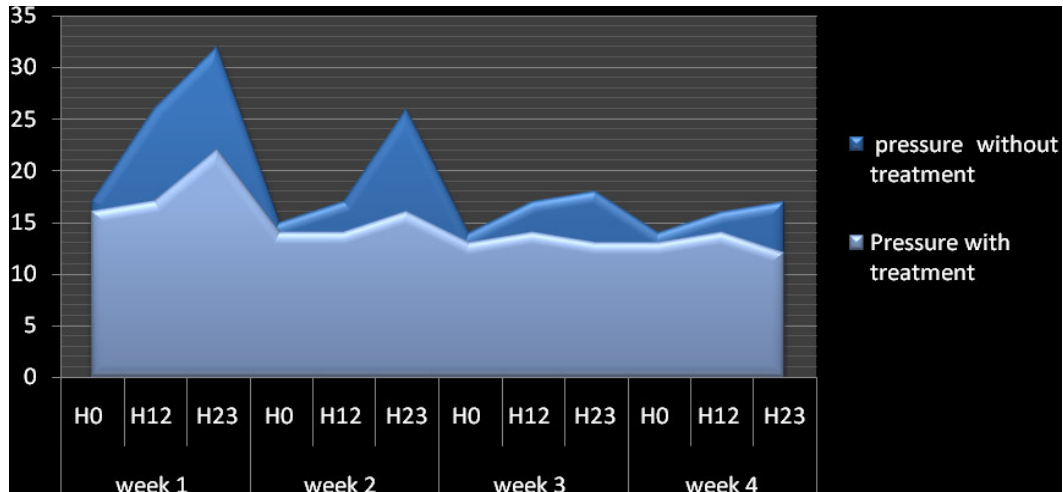


Fig. 3. Variation of intraocular pressure for 24 hours with and without treatment

it was confirmed that the intraocular pressure rises over night and this because of the action of cortisol, which is a trigger pressure by increasing the outflow of aqueous humor in the ocular medium which no longer provides its normal.

Conclusion. Glaucoma is characterized by progressive destruction of the optic nerve under the influence of multiple risk factors is the most common ocular hypertension. Glaucoma is increased pressure within the eye that results from a

decrease in the flow of aqueous humor. The treatment of chronic open-angle glaucoma is mainly to decrease the intraocular pressure by drugs (decreasing the secretion of aqueous humor or facilitating its elimination). Careful monitoring of intraocular pressure, the appearance of the optic disc and visual field changes is essential.

Thanks. We thank all the group of clinical ophthalmology Youhan Dirmon in Lyon and the staff for helping us to have realized this research.

BIBLIOGRAPHY

1. M. Zigler, B.Sc., DVM, Cert. V. Ophthalmology, Bronte Road Animal Hospital, Oakville, ON. 1990.
2. M. Williams, DVM, Dip. ACVO; Dr. Sue West, DVM, Dip. ACVO, Toronto North Veterinary Referral Services, Richmond Hill, ON. 1990.
3. Dan W. Lorimer, DVM, Eye Clinic for Animals, Tucson, Arizona. 1982.
4. Robert L. Peiffer, Jr., DVM - "Diagnostic and Therapeutic Challenges in Small Animal Ophthalmology I: Glaucoma" and "Determination of Intraocular Pressure (IOP) in Small Animal Practice". 2005.
5. Malcolm E. Miller, Bs, DVM, MS, Ph.D.: "Miller's Anatomy of the Dog", W.B. Saunders Co., Philadelphia, PA. 1998.
6. Rosa. M. Andreu de lapierre. E. L'essentiel en ophtalmologie des petits animaux: les editions du point veterinaire. 2002.
7. Chaudieu G, Chahory S. [Affections oculaires héréditaires](#) à prédisposition raciale chez le chien. Editeur: [Les Editions Du Point Vétérinaire](#). 01/2013 (2ème édition).
8. Barnett K. [Atlas diagnostique d'ophtalmologie vétérinaire: Guide pratique](#) : 2006.
9. Gelatt KN, Gelatt JP. Surgical procedures for treatment of the glaucomas. In: Handbook of small animal ophthalmic surgery. Vol.2 : corneal and intraocular procedures. Oxford, Elsevier Science, 1995, 117-161.
10. Gelatt KN. The canine glaucoma's. In Veterinary Ophthalmology. Philadelphia, Lippincot Wommians & Wilkins, 3rd ed., 1999, 733-748.
11. [Bouhanna.L. Vade-mecum d'ophtalmologie vétérinaire: Editions Med-Com: Vade-mecum](#). (2^{ème} édition). 2004.

ГЛАУКОМА СОБАК И ЕЕ ЛЕЧЕНИЕ ТИМОЛОЛОМ

Рахмун Джалал Эдин, Дирмон Йюхан

Хотя глаукома является основной причиной слепоты у собак, отсутствие единого определения этого заболевания в различных ее формах, значительно влияет на здоровье животных. Учитывая сходство между глаукомами, мы проанализировали имеющиеся данные о трех основных формах заболевания: врожденная глаукома; открытоугольная глаукома и наследственная -закрытие первичного угла. Простая модель была разработана с целью оценить степень глаукомы на региональном уровне. Результаты показывают, что глаукома является причиной около 7% слепоты в популяции собак. Таким образом, использование тимолола в дозе не менее 5 гр, как средства снижения внутриглазного давления периодически была эффективной

Ключевые слова: глаукома, собаки, внутриглазное давление, тимолол

ГЛАУКОМА СОБАК ТА ЇЇ ЛІКУВАННЯ ТИМОЛОЛОМ

Рахмун Джалал Едін, Дірмон Йюхан

Незважаючи на те, що глаукома є основною причиною сліпоти у собак, не існує єдиного визначення цього захворювання при її різних формах, що значно впливає на здоров'я тварин. Зважаючи на значну подібність глауком, ми проаналізували наявні відомості про три основні форми захворювання: вроджена глаукома, відкритокутова глаукома і спадкова - закриття первинного кута. Проста модель була розроблена з метою оцінити ступінь глаукоми на регіональному рівні. Результати показують, що глаукома є причиною біля 70% сліпоти в популяції собак. Використання тимололу в дозі не менше 5 гр. як засобу, що знижує внутрішньоочний тиск періодично було ефективно

Ключові слова: глаукома, собаки, внутрішньоочний тиск, тимолол
