

© Savchenko L., Mormol I., Husar P., Reva N., Borzykh O., Kaydashev I.
UDK:616-053.5:615.916'918

ACUTE INTAKE OF A LARGE DOSE OF CARDIAC GLYCOSIDES BY A YOUNG MALE*

Savchenko L.¹, Mormol I.¹, Husar P.², Reva N.², Borzykh O.¹, Kaydashev I.¹.

¹Department of Internal Medicine № 3 with Phthysiology, Ukrainian Medical Stomatological Academy, 23 Shevchenko Str., 36011 Poltava, Ukraine.

² 1-st City Clinical Hospital, Intensive Care Department, 27 Engelsa Str., 36011 Poltava, Ukraine.

Одними з найбільш токсичних препаратів є група серцевих глікозидів. Маючи вузьку широту терапевтичної дії, серцеві глікозиди здатні викликати серйозну інтоксикацію з ускладненнями, включаючи аритмії і порушення провідності, які часто призводять до смерті. Беручи до уваги показники смертності в разі отруєння ліками, важливо приділяти особливу увагу профілактиці, діагностиці та лікуванню таких станів. У даній статті представлений клінічний випадок розвитку гострої глікозидної інтоксикації у пацієнта 28 років з ускладненнями у вигляді порушень ритму і провідності, внаслідок помилкового прийому дигоксину. Своєчасне звернення за медичною допомогою і відповідне лікування допомогло уникнути серйозних наслідків глікозидної інтоксикації.

Ключові слова: гостра глікозидна інтоксикація, ускладнення, аритмія.

Introduction

As a result of development of chemical and pharmaceutical industry the rate of the cases of acute poisoning tend to increase, which is a significant problem for both health and toxicological science in general. One of the most toxic drugs is a group of cardiac glycosides. Having a very narrow spectrum of therapeutic action, cardiac glycosides are able to cause serious intoxication with complications including arrhythmias and conduction disorder, which often lead to death [1,2]. Considering the mortality rates in cases of medication poisoning it is important to pay special attention and care to prevent, diagnose and treat such medical conditions.

Case report

The 28-year-old Ukrainian male accidentally took digoxin instead of calcium. The patient arrived at the hospital around 16 hours after the accident. He complained on general weakness, palpitation and dyspnea.

The patient said that he took some tablets of «calcium» (approximately 30) in evening before sleep and next morning the symptoms of weakness, palpitation and dyspnea appeared. He found out that instead of calcium he took digoxin, which was often used by his grandmother. The patient approached emergency unit of the local hospital to receive medical help. The dose of taken digoxin was calculated as 0.0075G.

The patient considered himself to be generally healthy. He said that he had no chronic diseases and allergic reactions. The patient reported occasional (once or twice a year) viral diseases.

On admission, the patient was fully conscious (Glasgow Coma Scale: 15). His vital signs were: temperature 36.8°C, respiratory rate 17 breaths/minute, pulse 56

beats/minute; blood pressure 140/70 mm Hg, saturation O₂ 98%. On physical examination the patient's skin was pale, rash absent. Pupils were normally dilated. Peripheral lymph nodes were not enlarged. Peripheral edema was absent. Bones and muscle system were normal. Freely breathing through the nose. Ribcage was symmetrical, palpation was painless. Percussion of the lungs was normal, on auscultation - vesicular breathing. The heart auscultation revealed irregular rhythm. There were no murmurs or gallops. The tongue was wet and clean. There was no hepatosplenomegaly.

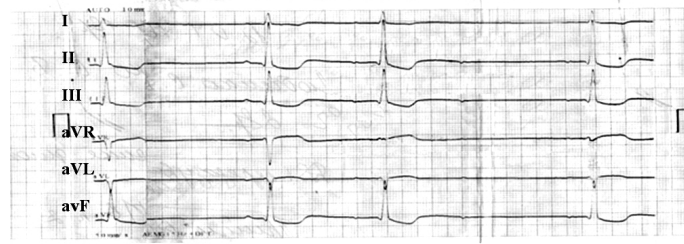
Laboratory tests results were within the normal range.

Blood test results: haemoglobin (HBG) 148 g/l; red blood cell (RBC) count $4.7 \cdot 10^{12}$ / l; color indicator 0.93; white blood cell (WBC) count $10.1 \cdot 10^9$ / l; eosinophils 1%; lymphocytes 16%, monocytes 3%; hematocrit (Hct) 0.45. Chemistry: total bilirubin – 17.0 mcmol/l, blood glucose – 5.0 mmol/l, urea 4.6 mmol/l, creatinine 123.0 mcmol/l, fibrinogen 4.4 g / l, electrolytes: K⁺ - 5.53 mmol/l, Na⁺ -137 mmol/l, Cl⁻ – 97.4 mmol/l; total protein 79.0 g/l. Urine test – unremarkable.

Chest X – ray detected no abnormalities.

On admission, an electrocardiogram (ECG) demonstrated atrial rhythm. The heart frequency: 57 beats per min. Atrioventricular (AV) block – II degree, and type I 3: 2, 5: 4, 5: 3. We observed transitional abnormality in repolarization (Figure 1).

* To cite this English version: Savchenko L., Mormol I., Husar P., Reva N., Borzykh O., Kaydashev I. Acute intake of a large dose of cardiac glycosides by a young male // Problemy ekologii ta medytsyny.- 2016. - Vol 20, № 3-4. - P. 16–19.

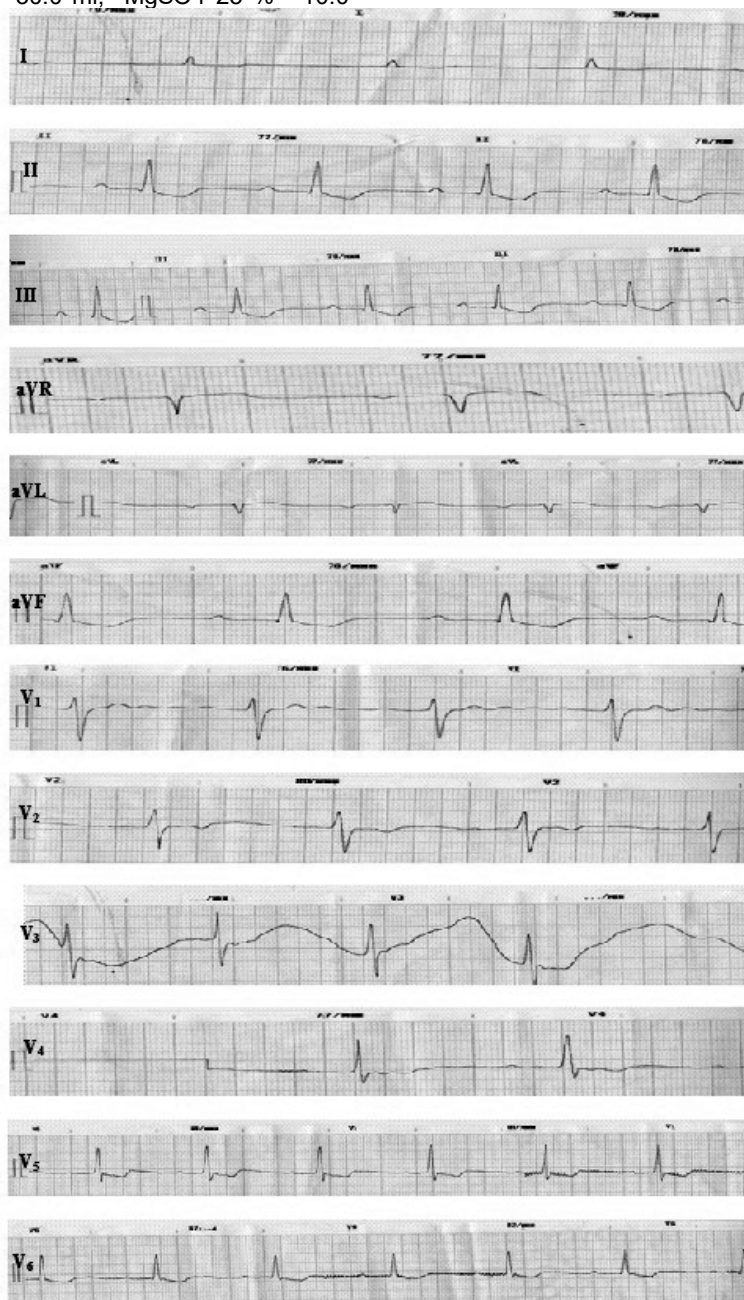

After admission the patient was transferred to the Intensive Care Department for monitoring of ECG, pulse rate, arterial pressure, body temperature, percentage of oxygen-haemoglobin saturation, urine output, etc.

Treatment consisted an activated charcoal administration, fluid infusion 1000 ml (solution glucose 5% - 400.0 ml, reosorbilact - 200.0 ml, sorbilact - 200.0 ml, electrolytes (NaCl 10% - 30.0 ml, MgSO4 25 % - 10.0

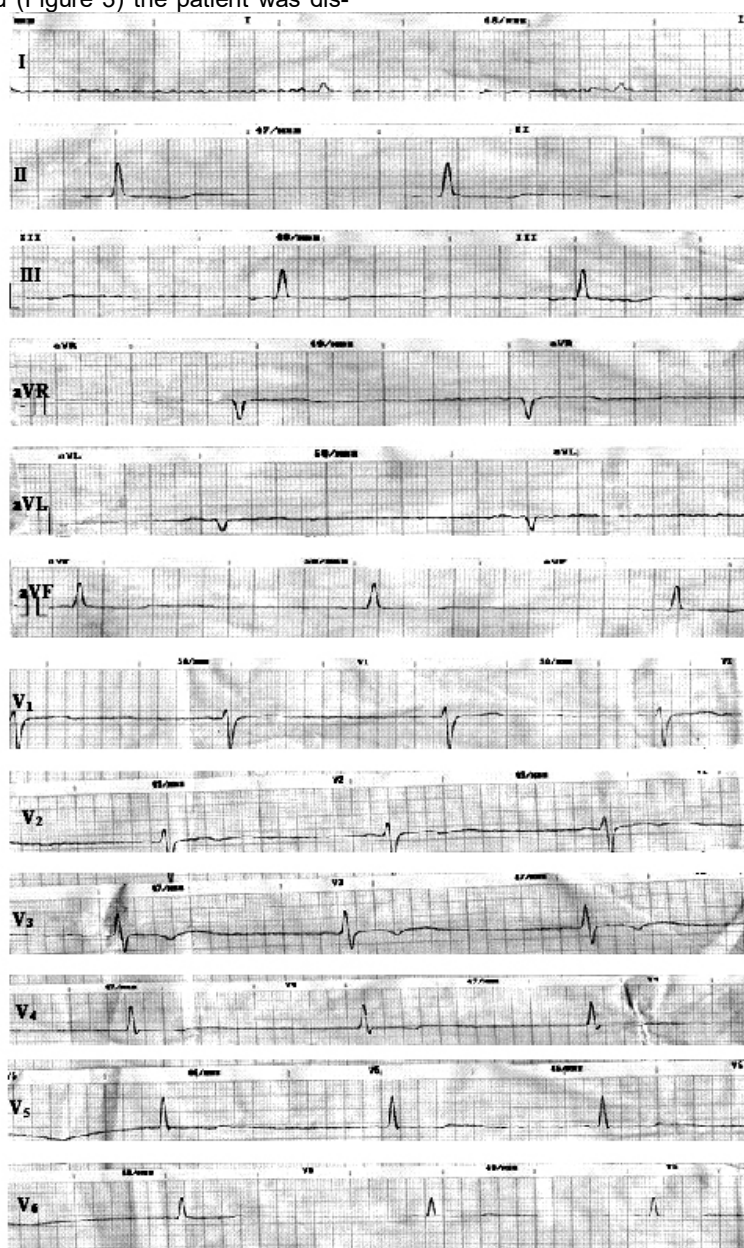
ml), omeprazole 40 mg intravenously, diluted in 200.0 ml of physiological solution, furosemide 2.0 ml.

Six hours after admission the ECG showed a positive change. Right sinus rhythm. Heart rate 71 beat per min. Electrical axis of the heart - vertical. There was subendocardial ischemia on myocardium of posterior-lateral walls (digitalis intoxication) (Figure 2).



The patient remained in hospital for three days. When the ECG had normalized (Figure 3) the patient was dis-

charged from hospital.



Discussion

Acute digoxin poisoning is a life-threatening condition. The clinical characteristics of intoxication are mainly cardiac (bradycardia, heart block, dysrhythmias), gastrointestinal (nausea, vomiting, abdominal pain, diarrhea) and weakness. Vision changes, including green/yellow discoloration and electrolyte abnormalities (hyperkalemia) may be noted in patients with chronic poisoning.

ECG changes include flattening or inversion of the T wave and depression of the ST segment. Dysrhythmias often associated with cardiac glycoside toxicity include bradydysrhythmias, sinus bradycardia with all types of AV nodal block, junctional rhythms, and sinus arrest [3, 4, 5, 6].

The intoxication mechanism of cardiac glycosides is that toxic concentrations of the substance significantly reduce the membrane ATP-ase activity, disrupt the function of sodium-potassium pump. Inhibition of enzyme activity leads to disruption of the return of potassium ions

into the cell, and the accumulation of sodium thereby increasing the excitability of cells and the development of arrhythmia [7].

Treatment of cardiac glycosides intoxication should consider the gastro-intestinal decontamination, treatment of all kinds of dysrhythmia, antidote (anti-digoxin Fab) administration or temporary cardiac pacing [2, 6].

In the case we are reporting, there was a one-time overdose of digoxin by the subject, whom did not have cardiovascular disease or other problems with health. The patient complained on general weakness, palpitation and dyspnea. On ECG was observed arrhythmia and atrioventricular block, deep trough decline in segment ST. Furthermore, the digoxin's effect appeared within a few hours after acute poisoning. The initial serum digoxin concentration in our patient was very high and did not reflect the total body burden, probably because full distribution has not occurred. This reflects the time for distribution to a peripheral compartment and/or time-dependent binding to the Na⁺-K⁺-ATPase [6]. After

treatment the patient's state significantly improved, symptoms of weakness, palpitation and dyspnea disappeared. We were unable to use antidote therapy due to limited resources of medication in the hospital, especially digoxin-specific antibody fragments.

Conclusions

A timely appeal for medical help and appropriate treatment avoided the serious consequences of glycoside intoxication.

Special attention should be paid to the fact the patient asked for medical help. This is a very important feature in the «internal diseases clinic», that reflects the severity of underlying disease.

From the start to the patient's request for help, the doctor should carefully complete all complaints, the medical history of disease and predict possible complications.

This case confirms the importance of careful usage of medications.

Summary

One of the most toxic drugs is a group of cardiac glycosides. Having a very narrow spectrum of therapeutic action, cardiac glycosides are able to cause serious intoxication with complications including arrhythmias and conduction disorder, which often lead to death. Considering the mortality rates in cases of medication poisoning, it is important to pay special attention and care to prevent, diagnose and treat such medical conditions. The 28-year-old male presents with intoxication and arrhythmia after he unintentionally took a wrong medication. A timely appeal for medical help and appropriate treatment helped to avoid serious consequences of glycoside intoxication.

Key words: acute glycoside intoxication, complications, arrhythmias

References

1. Bauman JL, DiDomenico RJ, Galanter WL. Mechanisms, manifestations, and management of digoxin toxicity in the modern era. *Am J Cardiovasc Drugs*. 2006;6:77–86. [PubMed] [Cross Ref]
2. Patel V. Digitalis Toxicity. Mode of access: <http://emedicine.medscape.com/article/154336-treatment>.
3. Kanji S, MacLean RD. Cardiac glycoside toxicity: more than 200 years and counting. *Crit Care Clin*. 2012;28:527–35. [PubMed] [Cross Ref]
4. Pincus M. Management of digoxin toxicity. *AustPrescr*. 2016 Feb;39(1):18–20. [PubMed]
5. Radenkova-Saeva J, Atanasov P. Cardiac glycoside plants self-poisoning. *ActaMedicaBulgarica*. 2014;1:99–104.
6. Roberts DM, Gallapathy G, Dunuwille A, Chan BS. Pharmacological treatment of cardiac glycoside poisoning. *British Journal of Clinical Pharmacology*. 2016;81:488–95.
7. Botha C. Cardiac glycoside intoxication. Mode of access: http://www.afrivip.org/sites/default/files/cardiac_glycoside_intoxication_complete_2.pdf.

Матеріал надійшов до редакції 02.12.2016